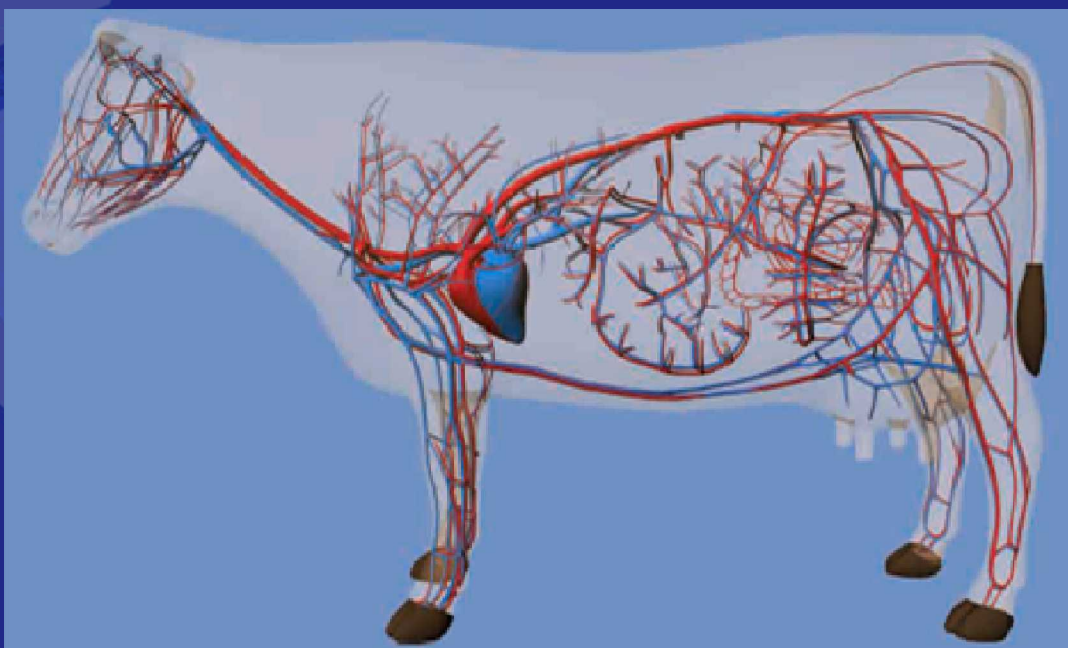


Examination of the Cardiovascular System



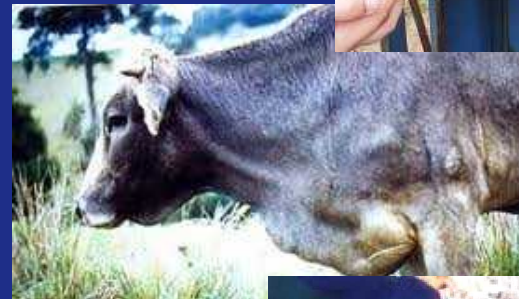Sandia is a multiprogram laboratory operated by Sandia Corporation, a Lockheed Martin Company,
for the United States Department of Energy's National Nuclear Security Administration
under contract DE-AC04-94AL85000.
SAND #




Examination from Afar: Cardiovascular System

- **Information collected during an examination from a distance**


- General body condition
- Edema
- Ease of respiration
- Respiratory rate
- Coughing
- Nasal discharge
 - **Blood**
 - **Serous**
- Jugular vein distension/pulsation
- Cranial abdominal pain
- Hydration status
- Licking nose
- Chewing cud





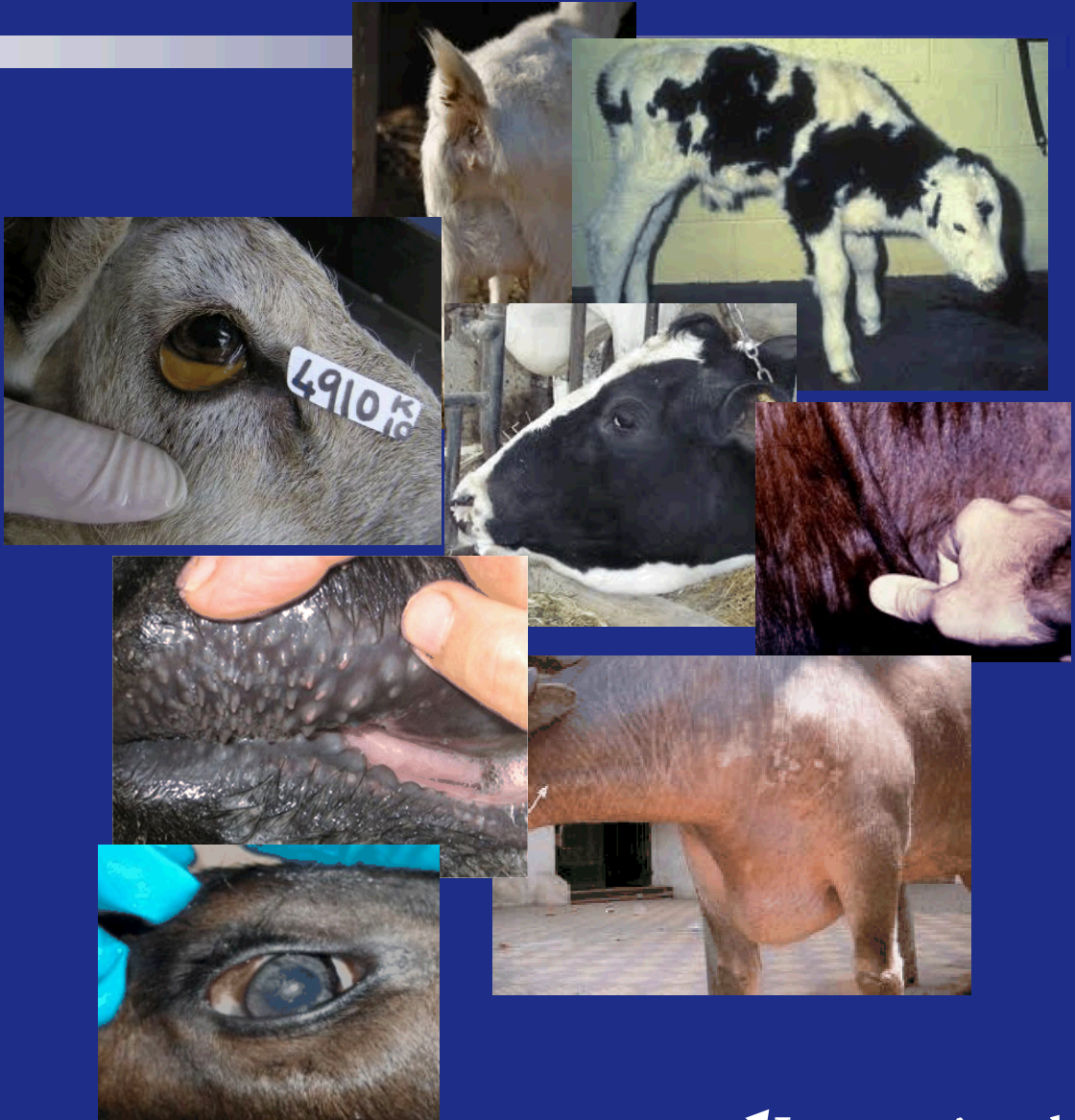Collecting a Meaningful History: Cardiovascular System

- **Historical information related to the cardiovascular system evaluation**
 - Duration of illness
 - Difficulty breathing
 - Coughing
 - Nasal discharge
 - Vaccinations
 - Previous treatments - magnet
 - Food and water consumption
 - Calving/lambing history
- **Historical information related to the herd**
 - Other animals affected
 - Duration of signs
 - Similarity of signs
 - Deaths associated with the illness
 - Changes in food and/or water
 - New additions to the herd



Examination: Cardiovascular System

- **Pulse**
 - Middle coccygeal artery: cattle
 - Femoral artery: sheep and goats
- **Mucous membranes**
 - Color
 - Dryness
- **Nasal discharge**
- **Facial symmetry**
 - Edema
 - Eye position in the globe
- **Sclera**
 - Color
 - Edema
- **Jugular vein distention**
- **Edema**
- **Milk vein pulsation**
- **Palpate lymph nodes**





Examination: Cranial Abdominal Pain

- Withers pinch test
- Grunt test





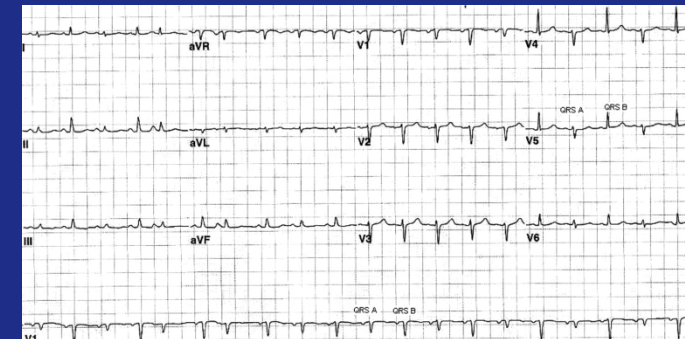Examination: Cardiac Auscultation

- **Anatomy**
 - Cattle: majority of the heart is in the left hemithorax
 - **Heart sounds are best heard on the left side**
 - Pulmonic valve: 3rd intercostal space
 - Aortic valve: 4th intercostal space
 - AV (mitral) valve: 5th intercostal space
 - **The heart can be heard on the right side at the third intercostal space**
 - Right AV valve: 3rd intercostal space
 - Stethoscope must be pushed far cranial
 - Sheep and goats: majority of the heart is in the left hemithorax
 - Left side: 2nd to 5th intercostal spaces



Examination: Cardiac Auscultation

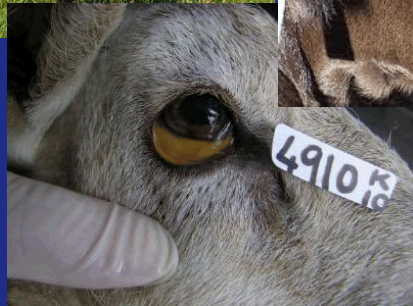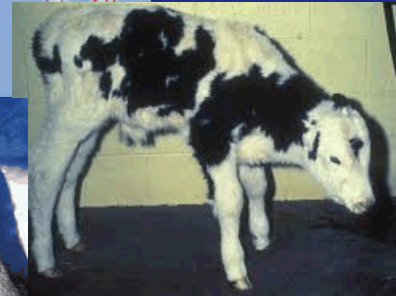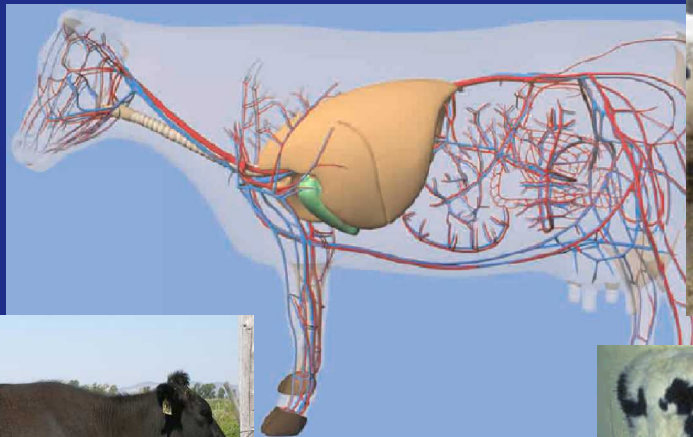

- **Auscultation**
 - Heart rate:
 - Cattle: 60 – 80 beats / minute
 - Calves: 110 – 120 beats / minute
 - Sheep: 70 – 80 beats / minute
 - Goats: 70 – 90 beats / minute
 - Lambs and kids: 120 – 140 beats / minute
 - Regular rhythm:
 - Skipped beats
 - Irregularities
 - Should listen for a full minute or longer
 - Sounds
 - Intensity of sounds
 - Endocarditis versus pericarditis
 - Electrical alternans
 - S1 and S2 can be heard in sheep, goats, and cattle
 - Listen closely for murmurs





Interpretation of Results: Cardiovascular System

- Abnormal findings: cardiovascular system





Ancillary Tests: Cardiovascular System

- **Electrocardiography**
- **Ultrasound examination (echocardiography)**
- **Radiography**
- **Hematology**
- **Microbiology**