Reprinted from CANCER, Vol. 8, No. 3, May-June, 1955
Copyright, 1955, by the American Cancer Society, Inc.
J. B. Lippincott Company Printed in U. S. A.

717627 89

PATHOLOGICAL STUDY OF EIGHT PATIENTS WITH GLIOBLASTOMA MULTIFORME TREATED BY NEUTRON-CAPTURE THERAPY USING BORON 10

JOHN T. GODWIN, M.D.,* LEE E. FARR, M.D., WILLIAM H. SWEET, M.D., AND JAMES S. ROBERTSON, M.D.

THE purpose of this paper is to report the pathological observations in eight cases of glioblastoma multiforme treated by thermal-neutron capture by boron 10. Because of the complexity of this subject, the clinical, physical and physiological[9, 10, 15, 22] aspects have been recorded in separate reports.

This form of investigative therapy is another of the applications of nuclear energy in the efforts to find better methods for managing human disease. In this instance, a normally stable isotope—boron 10—when bombarded with thermal neutrons produces ionizing radiations in situ.

After the identification of the neutron by Chadwick in 1932, the possibility of slow-neutron therapy was first suggested in 1936 by Locher. In 1940 Kruger, of the University of Illinois, working at the Crocker Radiation Laboratory in Berkeley, published the results of his observations on the effects of boron capture of thermal neutrons on mouse mammary carcinoma, lymphoma, and sarcoma in vitro after which they were transplanted. The percentage of transplantable tumors was reduced. He concluded that these results indicated that neoplastic cells could be destroyed in vivo if sufficient boron in some suitable form could be applied to the tumor in vivo.

In the same year Zahl, Cooper, and Dunning,[30] using the cyclotron at Columbia University, performed in vivo experiments with transplantable mouse sarcomas. These were injected with various forms of slow-neutron–capturing materials, then irradiated with slow neutrons. A significant tumor regression was observed.

Ludford and Duran-Reynals observed that acid dyes when injected into the blood stream would accumulate in greater concentration in tumor tissue than in normal tissue. In view of this Zahl and Cooper[28, 29] prepared lithium salts of pontamine sky blue 6B, trypan blue, and carminic acid in an effort to enhance the concentration of lithium in tumor tissue. They also discussed the physical-biological considerations involved in the use of slow neutrons for cancer therapy.

In 1948 Tobias et al. gave mice, intravenously, uranium UO_2 colloid prepared from enriched U^{235} (95 per cent) and followed it with slow-neutron bombardment.

In 1949, in a study of the cytogenetic effects of slow neutrons in *Trandescantia,* Conger and Giles found that this form of irradiation was more efficient than roentgen rays and that the efficiency was related to boron content. This report led Sweet[24] to consider the use of boron slow-neutron bombardment in brain tumors and data that he had obtained led us at Brookhaven temporarily to abandon our search for a boron carrier and to rely on a simple salt for therapeutic exploration. At this time the collaboration leading to these reports was begun. In 1952, Sweet and Javid[25] were able to show a differential concentration of borax in many rapidly growing brain tumors as compared to normal brain. Also, in the same year, Javid, Brownell, and Sweet reported upon their calculations of radiation damage to be anticipated from boron and various other elements in the brain incident to slow-neutron bombardment.

In 1953 Farr et al.[10] reported the clinical results of actual application of neutron-capture therapy in ten patients.

THEORETICAL ASPECTS

With roentgen-ray or beta-particle irradiation the destructive ionization is produced by electrons set free or accelerated. With fast-neutron irradiation a proton recoils with en-

From the Medical Department, Brookhaven National Laboratory, Upton, Long Island, New York, and the Massachusetts General Hospital, Boston, Massachusetts.
Presented in part at the Seventh Annual Cancer Symposium of the James Ewing Society, March 13, 1954.
This research was supported by the Atomic Energy Commission.
Mr. Frank E. Young prepared the histological sections and Mr. Robert F. Smith prepared the photographs.
*Present address: St. Joseph's Infirmary, Atlanta, Georgia.
Received for publication, October 14, 1954.

4001401

6-33-4

SLOW NEUTRON REACTIONS							
Cross Section	Original Nuclide		Thermal Neutron	Intermediate Complex		Product Nuclide	Accompanying Radiation
(0.33 barns)	$_1H^1$	+	$_0n^1$	$\longrightarrow$ $_1H^{2*}$	$\longrightarrow$	$_1H^2$	+ γ(2.23 Mev)
(1.7 barns)	$_7N^{14}$	+	$_0n^1$	$\longrightarrow$ $_7N^{15*}$	$\longrightarrow$	$_6C^{14*}$	+ $_1p^1$(0.6 Mev)
(3990 barns)	$_5B^{10}$	+	$_0n^1$	$\longrightarrow$ $_5B^{11*}$	$\longrightarrow$	$_3Li^7$	+ $_2\alpha^4$(2.39 Mev)

FIG. 1. Reactions occurring between boron 10, hydrogen, and nitrogen after slow-neutron bombardment.

ergy from the incident neutron, which energy is dissipated by the production of very intense ionization along its path. This energy is large compared to that of an electron. Stone and Larkin have utilized fast neutrons in therapy.

The reaction with which we are concerned is the thermal- or slow-neutron capture by boron 10 (Fig. 1). Boron 10 is employed because of its high cross section for thermal-neutron capture. This reaction is one of the most favorable known for this type of investigation:

FIG. 2. Alpha tracks produced by thermal neutron bombardment of mouse brain containing boron. There are also some spurious proton tracks that cannot be differentiated from the alpha tracks. (Courtesy of P. Gerald Kruger.)

4001402

the capture cross section of boron for slow neutrons is about 1000 times larger than the collision cross section of hydrogen for fast neutrons. Also, while the slow neutrons have a very small energy (a fraction of an electron volt up to 1 electron volt), the disintegration products, $_3Li^7 + {}_2He^4$, have about 0.87 Mev and 1.52 Mev energy respectively. These rather large energies are dissipated in very short distances (4 to 8 μ) in tissues, hence cause an even more intense ionization along their paths than the recoil proton in the fast-neutron–irradiation process. From these theoretical considerations, it is clear that the boron–thermal-neutron reaction should cause cell destruction more efficiently than other types of irradiation if the disintegration can be produced in the area of the neoplastic cells. The capture cross section of hydrogen and nitrogen (Fig. 1) is small enough so that the reaction with these elements need not result in radiation over tolerance of normal tissue during neutron-capture therapy.

It has been demonstrated that a sufficient differential concentration of boron is obtained in glioblastoma to be of significance therapeutically. This is probably due to the "blood-brain barrier" that retards the initial concentration of boron in normal brain but that is absent in tumor so that there exists a period during which time thermal-neutron irradiation may be instituted. Figure 2 shows heavy-particle tracks in an emulsion below a mouse-brain section irradiated by slow-neutron bombardment.

Because as yet no satisfactory method of computing or measuring tissue radiation in dose has been developed, the total thermal-neutron exposure per square centimeter of skin over the 2×4-in. port, together with the dose of boron injected, is given.

PATHOLOGICAL STUDIES

During the past two years (1950 to 1953) ten patients with surgically proved glioblastoma multiforme have been treated with this method (Table 1). The patient was placed in a compartment atop the nuclear reactor, boron 10 in glycerin was given intravenously, and the reactor was rapidly brought up to full power to provide sufficient numbers of thermal neutrons to irradiate the site of the tumor (Figs. 3, 4, 5).

All the patients have died and autopsies were obtained in eight cases. The longest survival from the first irradiation to death was 186 days. The autopsies were performed at the Brookhaven National Laboratory Hospital and at the Massachusetts General Hospital. This report is concerned with a pathological study of the eight cases in an attempt to ascertain possible irradiation effects. No effort has been made to give details of the gross or microscopic features of the lesions but, instead, photographs or conclusions in each case are given.

Except for the brains, a routine examination of all tissues was performed. In two cases radioautographic studies were performed because of the presence of thorotrast in certain tissues. Spectrographic analysis of the liver from one case was obtained to prove the presence of thorium and obtain a rough approximation of the amount in the liver (Fig. 6). This was calculated to be roughly 4 gm.

The brains were fixed in formalin immediately upon removal and sectioned several days later. Serial coronal sections from 0.5 to 1 cm. thick were made. The entire section of the hemisphere containing tumor together with surrounding normal brain was selected for celloidin section. Additional random sections of tumor and adjacent brain were taken for paraffin sections.

The celloidin sections were stained with hematoxylin and eosin, Perdrau's modification of Bielschowsky's method for reticulin, Weil's method for myelin, cresyl echt violet for Nissl substance, and Mallory's phosphotungstic acid–hematoxylin for astrocytes. Cajal's gold sublimate method for astrocytes and oil red O stain for fat were used on frozen sections.

A study of the brain tumors and adjacent brain was made in an effort to ascertain changes that might be attributed to irradiation. It should be pointed out that there are certain difficulties in identifying these. Glioblastoma undergoes spontaneous degenerative

2-113-1





3-107-1

FIG. 3. Compartment atop the nuclear reactor. The patient is placed with head over port (black rectangle).
FIG. 4. Patient in position atop the nuclear reactor. Alpha probe counter is being attached.
FIG. 5. Boron being administered intravenously just prior to neutron bombardment.

(For captions see opposite column.)

4-25-1

4001403



FIG. 6. Spectograph of thorium and liver specimen showing identical pattern.

changes that may simulate the effects of radiations. In addition, these cases had had previous craniotomy. One other, though less likely, cause for changes may be the boron itself, which has been stated to produce neuronal damage in the brains of mice and dogs.[19]

In most cases the operative specimen was obtained for study and comparison with the autopsy specimen. These were generally small specimens. A small number of roentgen-ray radiated and nonirradiated glioblastomas were obtained from Abner Wolf for comparison with the autopsy specimens (Fig. 7).

A short clinical and pathological discussion of the eight cases follows.

REPORT OF CASES

Patient 3977 (P. J.) was a 51-year-old business woman who noted the onset of slowly progressive neurological defects about one year prior to admission. This eventually lead to craniotomy at the Pratt Diagnostic Center in November, 1950, at which time she was having seizures, partial anomia, an abnormal focus by electroencephalogram, and a displaced left temporal lobe. A glioblastoma involving the left temporal lobe and considered to be inoperable was found. After a small dose of borax during the operation, the tumor tissue contained five times as much boron as normal brain. On February 15, 1951, she was given thermal-neutron–capture therapy, receiving 0.44×10^{12} neutrons per square centimeter. The boron dose was 20 mg. per Kg. body weight. During the first twenty-four hours after treatment the patient suffered from nausea and vomiting and transient hypertension. There was some clinical improvement, but after about six weeks she became progressively worse and died.

Pathological Findings. Gross and microscopic autopsy findings were not significant except as related to the brain. There was a



FIG. 7. Microphotograph of glioblastoma showing extensive vascular changes after roentgen-ray radiation.

4001404

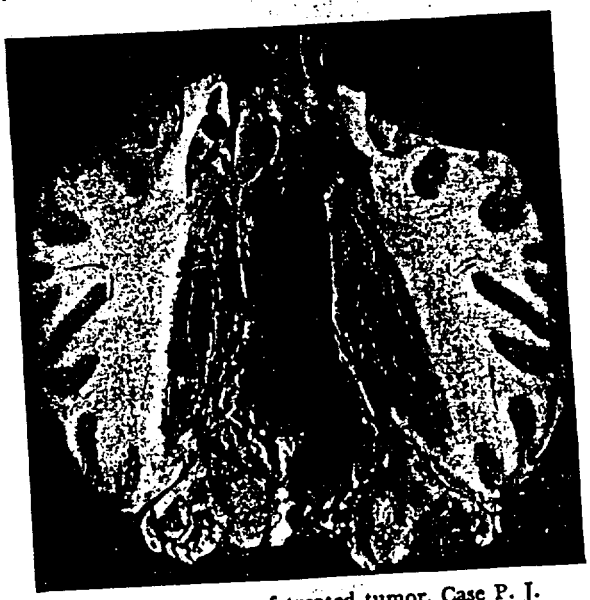

FIG. 8. Appearance of treated tumor. Case P. J.

5.5×2-cm. cyst filled with gelatinous material. A coronal section through the tumor is shown in Fig. 8.

TABLE 1

PATIENTS TREATED

Autopsy Was Not Obtained in Cases J. M. and J. H.

Pat.	Sex	Date of oper.	Date 1st irrad.	Dates later irrad. as day after 1st irrad.	Day. death as day after 1st irrad.	Day. death as day after Oper.
P.J.	F	12/ 1/50	2/15/51		67	143
W.L.	M	1/27/51	3/15/51		93	140
G.F.	M	1/ 6/51	3/22/51		43	118
J.M.	M	2/ 9/51	6/14/51		141	267
A.R.	M	1/13/51	6/14/51		100	252
A.B.	M	10/26/51	12/13/51	26; 89; 134	186	234
T.F.	M	1/10/52	2/12/52	80	136	169
P.P.	M	1/11/52	4/ 8/52	14; 73	97	185
A.H.	F	5/ 8/52	9/12/52	56; 119; 147	152	279
J.H.	M	10/ 5/52	11/ 7/52	28; 63	67	100

Microscopic examination showed large areas of tumor necrosis and some alteration in the adjacent brain, such as glial proliferation and chromatolysis of Nissl substance. Some tumor cells stained positively for fat. There were no changes beyond those seen in spontaneous degeneration (Fig. 9). There was no change in the adjacent brain, except that believed caused by the contiguous tumor.

Patient 4055 (W. L.) was a 38-year-old white



FIG. 9. Pretreatment specimen showing typical glioblastoma. Case P. J. Posttreatment specimen was similar.

4001405

FIG. 10. Appearance of treated tumor. Case W. L.

FIG. 12. Appearance of treated tumor. Case A. R.

man who developed neurological symptoms about one month prior to craniotomy. At operation a left temporal glioblastoma multiforme was encountered of which about 75 per cent was excised. Thirty-seven days later the patient was given neutron-capture therapy with a total thermal-neutron skin exposure of 1.42×10^{12} neutrons per square centimeter and a boron dose of 26 mg. per Kg. body weight. There was some apparent improvement for a few days, followed by progression of the disease requiring further surgical therapy. This was performed sixty-three days after irradiation.

The patient became worse and died ninety-three days after radiation therapy.

Pathological Findings. Postmortem examination revealed bronchopneumonia, moderate hepatic centrolobular necrosis, and nodular goiter. Examination of the brain showed a large tumor extending from the posterior part of the frontal lobe posteriorly to within 2 cm. of the occipital tip (Fig. 10).

Study of the various sections revealed no changes that were considered attributable to irradiation. There were large areas of necrosis and fibrinoid changes in some vessels. There was no damage to the adjacent brain, except that incident to the contiguous tumor.

FIG 11. Appearance of treated tumor. Case G. F.

Patient 4045 (G. F.) was a 60-year-old man upon whom craniotomy was performed and resection of a glioblastoma multiforme of the right parietotemporal and occipital lobes was done. One month later, on March 22, 1951, he was given neutron-capture therapy, receiving 1.46×10^{12} thermal neutrons per square centimeter at the skin. The boron dose was 29 mg. per Kg. body weight. He continued a progressively downward course and died forty-three days later.

Pathological Findings. At autopsy the patient had bronchopneumonia, pulmonary-artery tumor emboli, and an organized thrombus in one pulmonary artery. A coronal section of the tumor is shown in Fig. 11.

The postirradiated tumor showed necrosis and more pleomorphism than the small surgical specimen; otherwise there were no suggestive irradiation changes.

Patient 4227 (A. R.) was a 47-year-old white man who was operated upon about one month after the appearance of neurological symptoms. A large cystic glioblastoma multiforme was removed from the right parieto-occipital region. He was admitted to Brookhaven National Laboratory Hospital and given neutron-capture therapy, receiving a total of 1.42×10^{12} neutrons per square centimeter at the skin. The boron dose was 25 mg. per Kg. body weight. He showed no significant changes immediately after this therapy. Clinical follow-up was unsatisfactory, as the patient went to South America on business.

On August 15, 1951, he developed severe seizures, returned to this country, and died 100 days after radiation therapy.

Pathological Findings. Autopsy findings were not available except for the brain. On sagittal section, the right hemisphere was seen to contain a circumscribed infiltrating neoplasm that was variegated and varicolored. It measured 6.5 cm. in the anteroposterior diameter and 7 cm. vertically. It contained cysts

4001406

FIG. 13. Appearance of treated tumor. Case A. B.

filled with gelatinous material, one of which measured 5×4×1.5 cm. (Fig. 12).

Microscopically, there were numerous hemorrhagic areas but none suggestive of irradiation changes. A section of the operative specimen showed viable tumor. (This pattern differs somewhat from the postradiation tumor.)

Patient 4653 (A. B.) was a 58-year-old white man who first had neurological symptoms twenty-four days prior to craniotomy. On October 26, 1951, a glioblastoma multiforme was excised from the right frontoparietal region. On December 13, 1951, he was subjected to neutron-capture therapy. Three days later a mild dermatitis appeared over the area of irradiation.

On December 18, 1951, he was discharged but returned on January 7, 1952, with a progression of disease. On January 8, a second neutron-capture treatment was given. He improved so that he was able to walk, which he had not been able to do prior to this treatment. On January 10, 1952, he was given 40 cc. of thorotrast. The scalp area exposed to the radiation showed evidence of radiation effect, with epilation, by January 25.

He was readmitted on March 10, 1952, and on March 11 was subjected to a third neutron irradiation. He was again readmitted on April 24, 1952, and on April 25 he was again given neutron-capture therapy. After treatment he was lethargic and became slowly progressively worse and died on June 15, 1952. He received a total of 5.31×10^{12} thermal neutrons per square centimeter of skin. The boron dose was 19 mg. per Kg. body weight for each of the

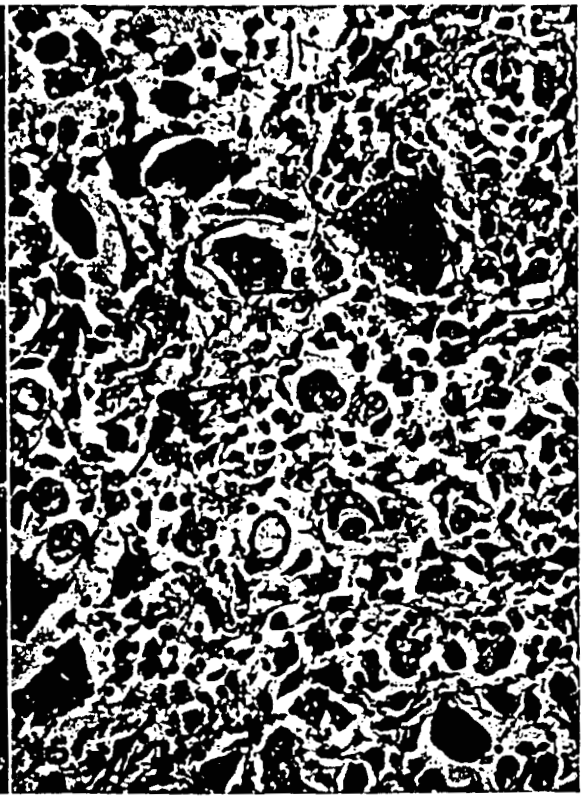

FIG. 14. Histological appearance of glioblastoma prior to treatment. Case A. B. Compare with Fig. 15 for posttreatment tumor.

FIG. 15. Histological appearance of treated glioblastoma. Case A. B. Compare with Fig. 14 for pretreatment specimen.

4001407

FIG. 16. Serial slices of left hemisphere with extension from frontal to occipital lobes. Case P. P.

first three treatments and 16 mg. per Kg. for the fourth treatment.

Pathological Findings. The significant postmortem findings were bronchopneumonia, pulmonary infarction, thrombophlebitis of the left iliac vein, and residual brain tumor (Fig. 13). Numerous sections of the residual brain tumor and adjacent brain showed foci of necrosis, tumor giant cells, and some thickening of the vessels adjacent to the tumor. There were no changes in the tumor or adjacent brain that unequivocally could not be associated with spontaneous changes, although the tremendous size of the giant cells, vacuolization of cytoplasm and nuclei, and scarring, in addition to fibrinoid vascular changes, are suggestive of radiation effects (Figs. 14, 15).

Of incidental interest was the presence of thorotrast granules in the liver, spleen, and bone marrow. Radioautographic studies of the thyroid, skin, lymph node, and gut were negative. The liver showed numerous alpha tracks produced by the disintegration of thorium. A rare alpha track was found in the kidney, lung, and pancreas.

Sections of bone marrow and spleen were not available for radioautographic study, although, in view of the presence of thorotrast granules in these organs, there is no doubt that alpha tracks would have been found. The thorotrast in the liver was located in the Kupffer





FIG. 17. Pituitary showing extensive scarring. Case P. P.
FIG. 18. Preirradiated specimen. Case P. P. Compare with Fig. 19.

4001408

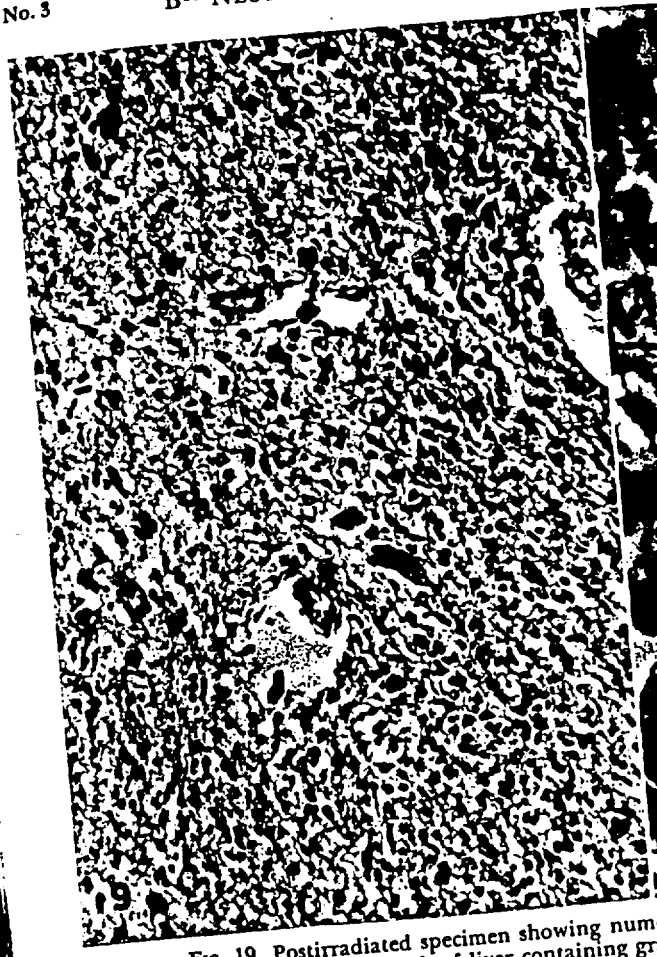

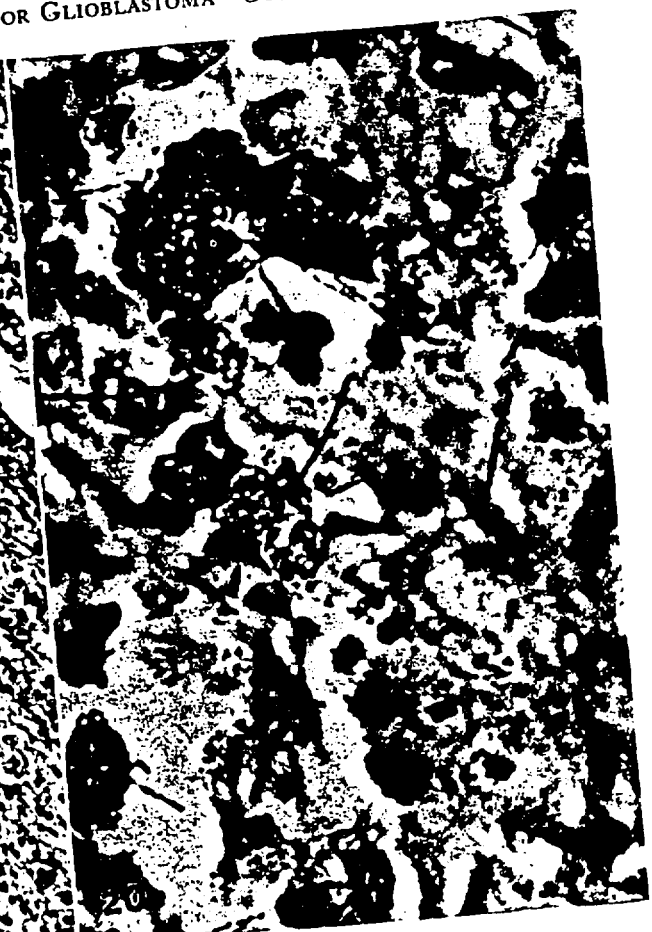

FIG. 19. Postirradiated specimen showing numerous giant tumor cells. Case P. P.
FIG. 20. Radioautograph of liver containing granules of thorotrast with alpha tracks. Case P. P.

cells, extracellularly in the triads, and in occasional hepatic cells.

Patient 4737 (T. F.) was a 59-year-old white man who developed neurological symptoms April 25, 1949, and upon whom a craniotomy was performed on June 20, 1949, for a glioblastoma of the right temporoparieto-occipital region. A second operation was performed on November 14, 1949, and a cystic area in the previous operative site was aspirated of 50 to 60 ml. of fluid. Neoplastic tissue was removed from the temporal lobe. On January 10, 1952, a third operation was performed at which time additional tumor was removed. On February 12, 1952, he was given neutron-capture therapy with a thermal-neutron skin dose of 0.86×10^{12} neutrons per square centimeter. He was discharged on February 19 without any change in his condition.

On April 29, 1952, he returned for a second treatment, which was given on May 2. At this time the skin exposure was 0.70×10^{12} neutrons per square centimeter. The boron dose was the same as before: 27 mg. per Kg. body weight. After this treatment he improved over his pre-therapeutic status. This improvement lasted for about two weeks, when he began to get progressively worse and died on June 27, 1952.

Pathological Findings. Autopsy findings are not available except for the brain. There were necrotic foci but nothing significant regarding irradiation changes. The operative specimen was similar to the irradiated tumor.

Patient 4709 (P. P.) was a 54-year-old white man who developed memory loss and mental confusion the latter part of December, 1951.

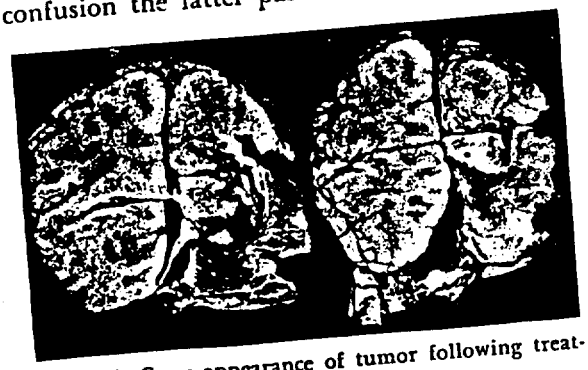

FIG. 21. Gross appearance of tumor following treatment. Case A. H.

4001409

FIG. 22. Segment of scalp showing gradual loss of hair shafts toward the right, the area of increasing irradiation. Case A. H.

FIG. 23. Scalp showing loss of hair shafts and early damage to sebaceous gland. Case A. H.

FIG. 24. Scalp showing loss of hair shafts and sebaceous glands, atrophic epidermis, scarring, and telangiectasis. Case A. H.

4001410

He was given 20 cc. of thorotrast for arteriography. On January 11, 1952, a partial removal of a left temporal glioblastoma multiforme was performed.

On January 22, 1952, he was admitted to the Brookhaven National Laboratory Hospital. His general condition was poor and he was semicomatose the greater part of the time. A right hemiparesis was present. Frequent removal of spinal fluid was necessary to reduce the increased intracranial pressure. On February 14 and 25, radioactive argon 41 was injected into the tumor area. No change was noted after this procedure.

On April 8 the patient was placed in position atop the nuclear reactor and given thirty minutes of neutron-capture therapy. The total skin exposure was 0.93×10^{12} neutrons per square centimeter. The dose of boron was 21 mg. per Kg. body weight. The same boron dose was given for the second and third treatments. During the first two weeks after this treatment he appeared somewhat less lethargic. On April 22, he was given neutron-capture therapy for the second time, the total skin thermal-neutron exposure being 0.70×10^{12} neutrons per square centimeter. On the third posttreatment day he developed a marked increase in intracranial pressure, elevated white blood count, and low blood pressure. Whole blood transfusions, ventricular taps, and supportive therapy were instituted.

In the area of scalp irradiation, dermatitis with secondary infection developed, which responded slowly to treatment. On May 12 the patient went into deep coma.

On June 20 neutron-capture therapy was given for the third time. The total skin exposure was 0.72×10^{12} thermal neutrons per square centimeter. He continued to decline steadily and on July 11 was noted to be deeply jaundiced. Death occurred on July 14, 1952.

Pathological Findings. Postmortem examination revealed the body to be well developed but emaciated. The skin and sclerae were icteric. There was a circular scar over the left temporofrontal area about 4 cm. in diameter. There were patchy areas of alopecia beginning slightly to the left of the mid-line, with complete epilation within the circumference of the scar and for 3 to 4 cm. posteriorly. The left cerebral hemisphere contained a granular, friable, grayish-white, neoplastic mass extending from the frontal to the occipital lobe (Fig. 16). Throughout the tumor were scattered yellow and red areas of old and recent hemorrhage. There were no gross differences in the areas that presumably received large numbers of thermal neutrons and those in which, because primarily of depth attenuation, the numbers of neutrons were significantly less.

Microscopic study of the liver revealed extensive centrolobular necrosis with fibrosis, pigment-laden macrophages, mononuclear infiltrate, and scattered homogenously pink-staining hepatic cells indicative of continuing cell death. There were extensive deposits of thorotrast throughout the areas of necrosis, which suggest a causal relationship, though a superimposed serum hepatitis could not be excluded.

The left lung showed foci of bronchopneumonia and atelectasis. There was a mild chronic prostatitis and cystitis. The left adrenal contained a small cortical adenoma.

The pituitary showed extensive scarring of the anterior lobe (Fig. 17). In some areas the scarring measured 1.5 mm. in diameter. There was no apparent alteration in the cells composing the remainder of the anterior lobe.

Examination of the brain revealed extensive necrosis, considerable tumor–giant-cell formation and spindle hyperchromatic nuclei suggesting possible radiation effects, particularly when compared with the preirradiation material. Figures 18 and 19 show the preirradiated and postirradiated specimens respectively for comparison. Whether these changes were the result of argon 41 radiation or neutron-capture therapy, we cannot say.

Radioautographic studies of the liver, spleen, and bone marrow revealed many alpha tracks (Fig. 20). The lung, adrenal, and kidney showed rare alpha tracks. The prostate, gut, gallbladder, thyroid, pancreas, and bladder were negative.

Patient 5144 (A. H.) was a 33-year-old white woman who developed diplopia, severe headaches, and left-sided weakness in April, 1952. On May 8, a right parietal craniotomy was performed with resection of a large glioblastoma multiforme. On June 27 a second craniotomy was performed in an effort to remove any residual tumor.

On September 12 the patient was given neutron-capture therapy. The skin exposure was 0.96×10^{12} thermal neutrons per square centimeter. The boron dose was 40 mg. per Kg. body weight, and this same dose was given for the following three treatments. She showed some slight improvement in motion of the left side of the body. On the fourteenth postradiation day, epilation and a dry scaly dermatitis were noted. She was discharged on October 8 and readmitted on November 5. Her condition was about the same as before. On November 7 a second treatment was given. The skin exposure was 0.91×10^{12} thermal neutrons per square centimeter. By November 10 there was marked erythema of the irradiated scalp, which progressed to superficial ulceration. This

4001411

healed slowly. On December 11 the patient appeared somewhat improved. On January 9, 1953, a third treatment was administered, with no change in the patient's condition. The thermal-neutron dose was identical with the first treatment. On February 6 a fourth treatment was given without significant change in the patient's condition. The thermal-neutron skin exposure was 0.90×10^{12} neutrons per square centimeter. On February 11 she suddenly became worse and died.

Pathological Findings. The essential postmortem findings included aspiration of gastric contents and focal atelectasis of the lung. The kidneys showed cortical scarring and small pelvic concretions. The scalp was epilated and crusted in the irradiated area.

After fixation coronal sections of the brain showed a hard, friable, grayish-white tumor in the inferior medial portion of the parietal lobe that extended into the posterior part of the right cerebral peduncle (Fig. 21). The tumor extended to the tip of the occipital lobe.

Sections of the scalp consisted of a piece of tissue, 7 cm. long, extending from relatively normal tissue into the central area of epilation. The nonepilated area showed normal epidermis, hair shafts, and sweat and sabaceous glands. There was a focal scarred area in the old surgical incision. In the tissue, progressing from the nonepilated area to the central portion of the epilated zone, there was a gradual loss of hair, sebaceous glands, and sweat glands, in this order (Figs. 22 to 25).

The epithelium showed loss of the rete pegs, slight thickening with enlargement of the nuclei, increased thickness of the granular-cell layers, and also slight hyperkeratosis. The areas formerly occupied by hair shafts and sebaceous glands showed hyalinized connective tissue, occasionally with a small focus of residual epithelial cells.

The vessels were dilated and the walls thickened by collagen. The nerves showed peripheral fibrosis. The sweat glands in the most involved area were disrupted by fibrous tissue, and the individual cells of the tubule showed cytoplasmic vacuolization and nuclear changes, in addition to being surrounded by a rim of hyalinized tissue.

One section of brain showed a superficial scarred area, 1.5 mm. in thickness. This was composed of dense collagenous tissue containing a few foci of hemosiderin deposits. There were occasional ganglion cells undergoing degeneration. The gray matter showed edema. Section of the pons revealed edema—particularly in the right inferior colliculus. Section of tumor showed large areas of collagenous deposition. The vessels showed surrounding hyalinization. There were many giant cells containing several small nuclei. These changes



FIG. 25. Sweat gland showing extensive damage. Case A. H. (PAS.)

4001412

these changes, although it would appear from the data at hand that the major contribution is from thermal-neutron reactions.

One of the more important aspects of this type of therapy is the estimation of the dose of irradiation delivered to the tumor and overlying tissues. At present no satisfactory conclusions have been reached as to the dose delivered by the boron–slow-neutron bombardment, i.e., alpha radiation, and the dose delivered by the contaminating gamma and fast-neutron component of the beam employed. One major problem in ascertaining the alpha-radiation dose has been the difficulty of obtaining an accurate method of boron assay of tissues.

Only three patients lived long enough for the delayed effects (principally demyelinization) of irradiation to occur and none was found.

Because of the frequency of hypothalamic and medullary damage, which was observed by Arnold[1] and by Clemente and Holst, any additional brains should be studied more extensively in these areas.

The presence of thorotrast and its distribution were shown by radioautography in two cases. This substance is of interest because of its fibrosing and possible late carcinogenic effects.[20] No cell inclusions were found in the pancreas as demonstrated by Fisher in boric acid poisoning, nor were there other changes attributable to this agent.[4]

SUMMARY AND CONCLUSIONS

A pathological study of the effects of neutron-capture therapy employing boron 10 has been recorded in eight patients. Of these, three patients given multiple irradiations revealed changes in the tumor that were suggestive of irradiation effects. Large areas of viable tumor were found in all cases.

At the present time it is not possible to ascertain the dose of irradiation attributable to the boron slow-neutron process. Therefore it is not possible to be certain that irradiation of an order expected to produce significant histological changes was delivered to the tumor.

Irradiation effects were present in the scalp of several patients, although material for adequate pathological study was obtained from only one. More recently, the scalp of another patient, not included in this report, from which adequate material was obtained revealed similar alterations. The distribution of thorotrast was demonstrated radioautographically in two cases in which it had been employed for arteriography.

REFERENCES

1. ARNOLD, A.: Effects of x-irradiation on the hypothalamus: a possible explanation for the therapeutic benefits following x-irradiation of the hypophysial region for pituitary dysfunction. *J. Clin. Endocrinol.* 14: 859-868, 1954.

2. ARNOLD, A.; BAILEY, P.; HARVEY, R. A.; HAAS, L. L., and LAUGHLIN, J. S.: Changes in the central nervous system following irradiation with 23-mev x-rays from the betatron. *Radiology* 62: 37-44; disc. 44-46, 1954.

3. ARNOLD, A.; BAILEY, P., and LAUGHLIN, J. S.: Effects of betatron radiations on the brain of primates. *Neurology* 4: 165-178, 1954.

4. BROOKE, C., and BOGGS, T.: Boric-acid poisoning; report of a case and review of the literature. *Am. J. Dis. Child.* 82: 465-472, 1951.

5. CLEMENTE, C. D., and HOLST, E. A.: Pathological changes in neurons, neuroglia, and blood-brain barrier induced by x-irradiation of heads of monkeys. *A. M. A. Arch. Neurol & Psychiat.* 71: 66-79, 1954.

6. CONGER, A. D., and GILES, N. H., JR.: The cytogenetic effect of slow neutrons. *Genetics* 35: 397-419, 1950.

7. DAVIDOFF, L. M.; DYKE, C. G.; ELSBERG, C. A., and TARLOV, I. M.: The effect of radiation applied directly to the brain and spinal cord. I. Experimental investigations on *Macacus rhesus* monkeys. *Radiology* 31: 451-463, 1938.

8. DURAN-REYNALS, F.: Studies on the localization of dyes and foreign proteins in normal and malignant tissues. *Am. J. Cancer* 35: 98-107, 1939.

9. FARR, L. E.; ROBERTSON, J. S., and STICKLEY, E.: Physics and physiology of neutron-capture therapy. *Proc. Nat. Acad. Sc.* 40: 1087-1093, 1954.

10. FARR, L. E.; SWEET, W. H.; ROBERTSON, J. S.: FOSTER, C. G.; LOCKSLEY, H. B.; SUTHERLAND, D. L.; MENDELSOHN, M. L., and STICKLEY, E. E.: Neutron capture therapy with boron in the treatment of glioblastoma multiforme. *Am. J. Roentgenol.* 71: 279-291; disc. 291-293, 1954.

11. FISHER, R. S.: Intracytoplasmic inclusions in the pancreas due to boric acid poisoning. [Abstr.] *Am. J. Path.* 27: 745, 1951.

12. JAVID, M.; BROWNELL, G. L., and SWEET, W. H.: The possible use of neutron-capturing isotopes such as boron[10] in the treatment of neoplasms. II. Computation of the radiation energies and estimates of effects in normal and neoplastic brain. *J. Clin. Investigation* 31: 604-610, 1952.

13. KRUGER, P. G.: Some biological effects of nuclear disintegration products on neoplastic tissue. *Proc. Nat. Acad. Sc.* 26: 181-192, 1940.

14. LOCHER, G. L.: Biological effects and therapeutic possibilities of neutrons. *Am. J. Roentgenol.* 36: 1-13, 1936.

15. LOCKSLEY, H. B.; ROBERTSON, J. S.; STICKLEY, E. E.: SUTHERLAND, D. L., and FARR, L. E.: Effects of neutron radiation on blood-brain barrier. In manuscript.

16. LUDFORD, R. J.: The vital staining of normal and malignant cells—II. The staining of malignant tumours with trypan blue. *Proc. Roy. Soc., London* B 104: 493-512, Pl. 32, 1929.

17. NEMENOW, M. I.: The effect of roentgen rays on the brain; experimental investigation by means of the

4001413

conditioned reflex method. *Radiology* 23: 94-96, 1934.

18. PENNYBACKER, J., and RUSSELL, D. S.: Necrosis of the brain due to radiation therapy; clinical and pathological observations. *J. Neurol., Neurosurg & Psychiat.* 11: 183-198, 1948.

19. PFEIFFER, C. C.; HALLMAN, L. F., and GERSH, I.: Boric acid ointment; a study of possible intoxication in the treatment of burns. *J. A. M. A.* 128: 266-273; disc. 273-274, 1945.

20. PREZYNA, A. P.; AYRES, W. W., and MULRY, W. C.: Late effects of thorotrast in tissues. *Radiology* 60: 573-578, 1953.

21. RUSSELL, D. S.; WILSON, C. W., and TANSLEY, K.: Experimental radio-necrosis of the brain in rabbits. *J. Neurol., Neurosurg. & Psychiat.* 12: 187-195, 1949.

22. STICKLEY, E. E.: Neutron flux distribution in tissue equivalent phantoms. *Am. J. Roentgenol.* In press.

23. STONE, R. S., and LARKIN, J. C., JR.: The treatment of cancer with fast neutrons. *Radiology* 39: 608-620, 1942.

24. SWEET, W. H.: The uses of nuclear disintegration in the diagnosis and treatment of brain tumor. *New England J. Med.* 245: 875-878, 1951.

25. SWEET, W. H., and JAVID, M.: The possible use of neutron-capturing isotopes such as boron[10] in the treatment of neoplasms. I. Intracranial tumors. *J. Neurosurg.* 9: 200-209, 1952.

26. TOBIAS, C. A.; WEYMOUTH, P. P.; WASSERMAN, L. K., and STAPLETON, G. E.: Some biological effects due to nuclear fission. *Science* 107: 115-118, 1948.

27. WACHOWSKI, T. J., and CHENAULT, H.: Degenerative effects of large doses of roentgen rays on the human brain. *Radiology* 45: 227-246, 1945.

28. ZAHL, P. A., and COOPER, F. S.: Localization of lithium in tumor tissue as a basis for slow neutron therapy. *Science* 93: 64-65, 1941.

29. ZAHL, P. A., and COOPER, F. S.: Physical and biological considerations in the use of slow neutrons for cancer therapy. *Radiology* 37: 673-682, 1941.

30. ZAHL, P. A.; COOPER, F. S., and DUNNING, J. R.: Some *in vivo* effects of localized nuclear disintegration products on a transplantable mouse sarcoma. *Proc. Nat. Acad. Sc.* 26: 589-598, 1940.

4001414