717345

149

Argonne National Laboratory

P.O. BOX 5207
CHICAGO 80, ILLINOIS
BUTTERFIELD 1400

Date December 1, 1947

To: Clinton Lab

From: Office Services, Inventory and Audit Unit

NOTICE OF DECLASSIFICATION

Classification of Report CH-3368 Title Report of Hand Study

Author : Margaret Hickson

has been cancelled by authority of the Atomic Energy Commission on 9-2-1947.

According to our records you have copy 21,22,23,24,25,26 (27 M.D. Whitaker).

Instructions for Declassifying your Copy

1. Remove and destroy the present classified cover page.
2. Cross out in black ink all classified markings and espionage stampings on the title page and every succeeding page of text or figures.
3. Clip a copy of this notice to the report, sign and return a copy to the Inventory and Audit Unit. This will indicate that you have complied with the instructions.

After these instructions have been followed, your copy of this report is unclassified and is no longer accountable on inventory records.

Carrol L. Cohen

I have complied with the above instructions

Signed N. T. Bray

Date 12-11-47

REPOSITORY AMES/X-10/Vault

COLLECTION Central Files

BOX No. CH-3368

FOLDER

1119117

A-00173

Human Subjects Project

[redacted]

[redacted]

CH-3368
-3

Contract No.

W-7401-eng-37

HEALTH DIVISION

R. S. Stone, Director
L. O. Jacobson, Associate Director

BEST COPY AVAILABLE

REPORT OF HAND STUDY

Problem Assignment No. 330 MLH 3610
248 MLH 3620
373 MLH 3610

DECLASSIFIED Per Letter Instructions Of
AEC 92-47 Copy 244

Prepared by Margaret Nickson, M.D.

August 1, 1945

[redacted]

Report Received: January 28, 1946
Figures Received: February 11, 1946
Issued:

[redacted]

[redacted]

1119118

Table of Contents

Part I - Radiodermatitis as reported in the literature.

Part II - Hand study program and technic.

(a) Skin appearance

(b) Hand photographs

(c) Finger ridge impressions

(d) Capillary studies

Part III - Results.

(a) Macroscopic abnormalities

(b) Finger ridges

(c) Nail fold capillaries

(d) Statistical analysis of capillary counts

(e) Capillary photography

Note: Technical assistance given by Louise Warner and J. A. McIntosh.

1119119

Abstract

Radiodermatitis has always been a serious problem among individuals working in experimental, diagnostic, and therapeutic radiology. At present there is a great increase in the number of individuals engaged in experimental and industrial work involving radioactive materials. There is considerable opportunity for dangerous hand exposures, but there is no reliable means for detecting when such exposures have reached a dangerous level.

Observations have been made here of the hands of 973 laboratory and office personnel. Deviations from normal have been noted and photographs taken. Finger ridge impressions have been made of 1287 individuals of whom 15% showed some abnormality. Capillary counts have been done on 838 individuals. The number of capillaries in a given area of nail fold shows some correlation with possible exposure to radioactive materials. Capillary photographs have been taken of 93 individuals. There is a rough correlation between the morphology of the capillaries and the exposure of the hands of young individuals.

Normal aging tends to produce the same or similar changes. Further capillary studies are necessary to confirm or deny the apparent relationship between hand exposure and increased or prematurely aged terminal capillaries.

REVIEW OF SKIN STUDIES

Part I

Several years ago it became apparent that individuals engaged in laboratory work here could under some conditions expose their hands to radioactive materials. Since the work was in a developmental and experimental stage the type, amount and duration of exposure was unpredictable. It seemed expedient therefore to make careful observations of the hands of all individuals potentially exposed and to record the information so obtained in a form that would be useful to anyone making subsequent observations over a period of years.

The hearly history of radiology is a grim record of over-exposure. One has only to read such accounts as Colwall's "Essay on the History of Electrotherapy" to appreciate the amount of injury done to the early experimenters. Lesions particularly of the skin of the hands became common among radiologists, physicists, and technicians. As early as 1896 there were reports of severe burns of the hands of individuals installing, demonstrating, and using x-ray equipment (Grubbe), (Lepping), (Nature), (Stevens).

One year later Scott was able to accumulate reports of 69 cases of skin damage due to roentgen rays, and by 1901 Codman reported 147 cases of accidental x-ray burns. The number of cases of acute x-ray and radium dermatitis increased as more workers entered this field. Within a few years of the first reports of acute lesions, chronic changes began to be recognized. The first reported case of x-ray carcinoma appeared in 1902 and occurred in a factory worker engaged in making x-ray tubes (Frieben). By this time telangectasia, keratoses, dry papery skin, thick brittle nails became recognized as late effects of radiation exposure. Such chronic changes assumed major importance as many of the pioneers in this field began to suffer mutilating deformities and malignancies which ultimately led to death (Meyer).

During the intervening years hundreds of persons have been seen with all degrees of radiodermatitis. Most of the acute reactions have occurred in patients receiving radiation therapy or in persons accepting "treatments" from unqualified operators for such things as hirsutism, acne, warts, and various skin diseases. Chronic changes are most often found on the hands of roentgenologists, orthopedists, dentists, physicists, and others engaged in occupations in which repeated small exposures can occur. Each type of dermatitis may include elements of the other but in general the acute reactions are detectable within a week or 10 days after exposure whereas chronic change may not be apparent for months or even years. (Bordier) (Browning) (Clunet) (Cole) (Hagen) (Hesse) (Krause) (Leddy and Rigos) (Porter) (Porter and White) (Saunders and Montgomery) (Witwer and Leucutia).

The earliest macroscopic reaction is a reddish blush of the exposed skin sometimes accompanied by a sensation of heat and tingling. The erythemamay appear within a few hours or after several days. It gradually fades, then recurs in waves of decreasing intensity. The crests of these waves appear about the same time after unequal doses but the intervals tend to disappear after heavier doses. There is considerable variation in the time of appearance, duration and intensity of the erythema. (Brauer) (Ellinger) (Flaskamp) (Holzknecht) (Kohler) (Miescher) (Pohle). An erythema may be the only visible reaction or it may be accompanied or followed by depilation, edema, vesiculation, desquamation, pigmentation, necrosis, and ulceration of the skin and underlying tissues. The hair follicles, sweat and sebaceous glands may be unaffected, or they may be diminished or completely destroyed. Acute reactions following small doses tend to heal spontaneously with a good return of function, whereas those following heavier doses heal poorly or not at all. In the case of severe burns attempts toward repair repeatedly break down until eventually a chronic painful indolent ulcer results. The type and degree of reaction depends not only on the amount of radiation but on the quality of the radiation, the rate and duration of exposure, the condition of the radiated skin, the size and shape of the exposed area, individual differences in sensitivity, and differences in sensitivity of the skin of various parts of the body. (Colwell and Russ) (Dresser, Rude and Cosman) (Evans and Kerr) (Failla) (Herrmann and Pack) (Jolles) (Lehmann) (Liberson) (Meyer and Mutscheller) (Pfahler, Klauder and Martin) (Stone and Robinson) (Warren).

The microscopic picture of radiodermatitis has been carefully observed in both animals and humans. Day to day observations indicate that the earliest detectable changes occur in the minute vessels of the skin. These are first visibly increased in numbers, dilate and become more permeable than the corresponding vessels of untreated areas (David) (David and Gabriel) (Flaskamp) (Lazarew and Lazarewa) (Mottram) (Pendergrass) (Pohle) (Pohle and Bunting) (Pohle and Wright) (Schugt) (Zurhelle). The reactivity of irradiated vessels is altered so that even after a sub-erythema dose the skin reacts atypically to stimuli. In 1928, Sielamgrotsky reported that adrenaline produced no capillary contraction in skin areas previously exposed to "1 skin unit dose of x-ray". Caffeine, and mustard oil failed to produce dilatation of these vessels. Pohle described this phenomenon as a "histamine refractory state" and found that it accompanied each wave of erythema. Between the waves the capillaries regained their ability to contract and dilate to some extent. Pohle found that 1 SED was sufficient to produce morphological as well as functional changes in the surface capillaries. These changes were still detectable 1 year after treatment. The capillaries were either decreased or increased in number, elongated and were non-reactive to heat and cold. He believed that a permanent injury to the capillaries had occurred and this explained the tendency for previously irradiated skin to undergo major changes after relatively minor injuries. Shaffer in 1940 described altered skin reactions following doses of x-ray insufficient to produce the visible erythema which Pohle thought was necessary for a histamine refractory state. He concurred with the theory that the release of a histamine like substance dilates the vessels and makes them refractory to further stimuli. David and Gabriel observed an increase in

number the visible superficial capillary loops and a reddening of the background after 3/4 SED. Pendergrass, Hodes and Criffeth counted the visible loops in the skin of the forearm before and after irradiation and after histamine injection. They observed opened and dilated capillaries and subpapillary plexus vessels 6 and 24 hours after irradiation. The degree of change seemed to be related to the rate and method of exposure. (Figure 1) A recent report by Brunet de Rochebrun describes an acute inflammatory reaction in dog's skin after "1/5 erythema dose." The reaction was maximal in 7 hours. Each phase of it was identical with an inflammatory reaction produced in corresponding areas injected with 0.01 cc of a 75% solution of formic acid.

Histologically detectable dilation of the vessels of the dermal papillae was reported by Thies to be apparent 1 hour after exposing guinea pigs to radium. Numerous reports have described congestion and dilation of vessels in 1 to 3 days after exposure. By the third day there is well defined perivascular infiltration and thickening of the vessel walls. The endothelium of the small vessels proliferates rapidly and often to such an extent that many of these vessels become thrombosed. The surrounding tissue is jeopardized by impaired circulation and either becomes necrotic or survives with considerably reduced resistance.

Obliterative endarteritis of the fine vessels can be produced with very low doses. Linser has reported obliteration of vessels exposed to doses which caused no detectable change in either hair follicles or glands, both of which are considered relatively radiosensitive.

The larger vessels are affected in the same way but because of their greater lumens and more complex wall structures they have a greater chance to escape obliteration. The changes which occur are found chiefly in the smooth muscle and elastica of the median layer. Collagenous hyaline material appears in scattered areas. Fibrous connective tissue proliferates in all layers but particularly just under the thickened intima. Smaller veins and lymphatics like the arterioles are frequently found to be obstructed by endothelial proliferation and subsequently obliterated. (Codman) (Dobrovalskaia-Zavadskaia) (Flaskamp) (Gassman) (Guyot) (Halkin) (Mottram) (Pohle) (Porter) (Rowntree) (Thies) (Wolbach).

The various layers of the skin and the skin appendages are also sensitive to radiation, although probably not to the extent of the vascular system. The corneal layer of epidermis is most resistant probably because of its cellular inactivity and its high content of keratin. (Warren) The granular layer, however, is very reactive and proliferates extensively as early as 6 days after exposure (Guyot). The result is an invasion of the corium by long fingerlike projections of epidermal cells which penetrate the papillary border and leave cell rests and whorls buried deep in the corium. These projections have all the characteristics of epidermoid carcinoma except that they gradually recede or tend to remain quiescent. The resulting distortion of the regularly scalloped papillary border is reflected in distortion of the finger ridges which normally parallel the folds of the corium. (Pardo-

Figure 1



Appearance of the capillaries and subpapillary venous plexus in the normal skin of the extensor surface of the forearm. Camera lucida drawing in natural colors.

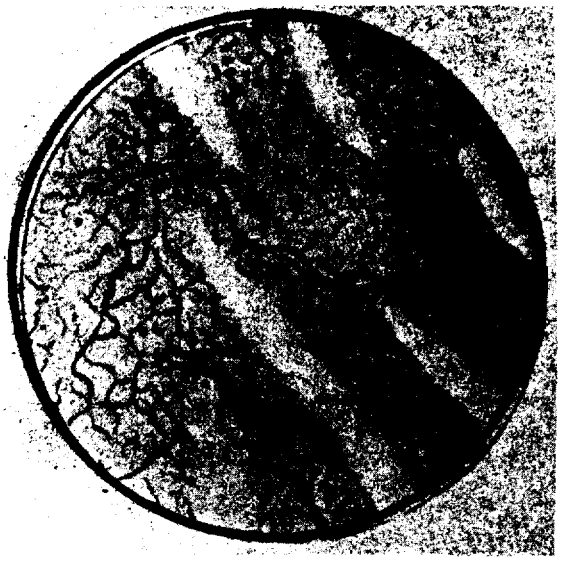

Appearance of the capillaries and subpapillary venous plexus in the skin of the extensor surface of the forearm after maximal dilatation following a burn. Camera lucida drawing in natural colors.

Costello) (Wolbach). The epidermis may also proliferate outwardly producing local thickenings, acanthoses and keratoses, such as are commonly found after repeated small doses. In some instances the epidermis becomes atrophic so that the skin looks very glossy, papery and transparent. Such skin is particularly non-resistant to further trauma of any variety. Its ability to repair is largely lost. Minor injuries or an additional exposure have been known to precipitate irreversible degenerative changes. Skin which has been exposed to a high dose may lose its epidermis completely by a necrosis and sloughing. The intact border of such areas shows the typical epidermal proliferation and invasion seen after smaller doses. These proliferative changes persist long after the acute lesion has healed. (Guyot) (Rowntree) (Thies) (Wolbach).

The skin appendages, hair follicles, sweat and sebaceous glands are quite sensitive. Depilation may follow doses insufficient to cause any other macroscopic reaction. For this reason x-ray has been injudiciously used for its epilation effect and in numerous instances the victims have suffered severe burns and chronic degenerative changes. (S. Davis) (Saunders and Montgomery). Temporary epilation in man follows doses of about 400 to 500r at 200 kv, while permanent epilation occurs after about 700 r (Warren). Sebaceous glands are destroyed simultaneously with hair follicles and both are affected by doses which spare the coil glands. Any exposure of sufficient intensity to produce necrotic changes in the corium usually causes permanent loss of hair and glandular structures. Repeated small exposures over a long period of time have the same end result. (CH-2189) (CS-2372) (Desjardins and Smith) (Ellinger) (Flaskamp) (Guyot) (Linser) (Rowntree) (Warren) (Wolbach).

Skin which has undergone an acute radiation reaction with subsequent healing retains 3 microscopic characteristics for a long time, perhaps indefinitely. These are:

1. Thickening, dilation and obliteration of some small vessels and lymphatics.

2. Persistence of epidermal cell rests and whorls deep in the corium.

3. Loss of hair follicles and glandular structures of the corium.

It has been suggested that such residual damage is largely responsible for subsequent chronic changes. (Dobrovolskaia-Zavadskaia) (Gassman) (Guyot) (Pohle) (Pohle and Bunting) (Thies) (Wolbach).

Chronic radiodermatitis may or may not be preceded by an acute reaction. Often the skin gradually loses its normal texture. Its surface becomes smooth, glossy, dry, and appears tightly stretched. Hair, sweat glands, sebaceous glands are diminished in numbers or lost. The normal skin ridges are smoothed. Nails become brittle, cracked, and deformed, nail folds are reddened and thickened. Multiple telangiectases appear in the skin. Keratoses are found varying from the most minute epidermal thickenings to areas as large as a dime. These are frequently very tender and have a tendency to undergo malignant degeneration (Duffy). The chronic radiation effects tend to progress long after exposure has ceased. Consequently they have been variously ascribed to such things

as altered local metabolism (Lieber) (Magath) (Meltzer and Kutz), primarily endarteritis and thrombosis (Davis) (Linser) (Unna) (Woloach) (Wyss), loss of essential fats and oils from the tissues (Burrows, Jorstad and Ernst) (Jorstad and Lane) (Wile, Cameron and Eckstein), and primary tissue injury exacerbated by vascular impairment (Fahr) (Rowntree). The changes have been aptly described as speeded up senile changes. A skin area so involved has lost much of its resistance and reparative powers. Its tone and elasticity are diminished. Minor trauma often precipitates the formation of indolent ulcers or malignant degeneration (Colwell and Russ) (MacKee).

Chronic reactions like acute reactions occur in all degrees and combinations. They differ from other types of traumatic effects in that they can be progressive without any further exposure to radiation. The progress can be somewhat ameliorated by persistent care of the skin, careful cleansing, constant lubrication and protection from any additional trauma. Lack of such care permits more rapid advance of the lesions or precipitates non-healing areas of necrosis and ulceration.

The appearance time of chronic radiation effects has been reported to vary from 1/2 to 10 years. Unna's four cases had symptoms within three years of exposure. Of 200 cases seen at the Mayo Clinic with telangectasis, sclerosis, pigmentation, alopecia, atrophy, and asteatosis the average appearance time was 4.0 years. In the same group severe lesions such as large ulcers appeared in an average time of 1.8 years after the last treatment. (Saunders and Montgomery) Of 17 patients with malignant roentgen neoplasms studied elsewhere the changes were noted in an average time of 1.0 years from the last treatment, although some of these patients had begun treatment four or more years earlier. Eight died within 1 to 10 years of the first signs of malignancy. (Witwer and Leucutia). Porter, who analyzed 47 cases of x-ray carcinoma and allied conditions found a latent period of 3 to 11 years with detectable changes usually occurring in 5 to 7 years. Hazen has investigated the previous exposures of 111 patients of whom 97 developed signs of radiodermatitis within 1 year. In none of these patients was the latent period greater than four years.

The most common chronic change in this group was telangiectasia, which was evident in 80% of the patients. Keratoses and ulcers occurred in 25% while cancer was seen in less than 3%. This report appeared within 2 years of the most recent exposures, therefore the incidence of the various types of chronic damage is significant only insofar as it indicates the earliest chronic lesions.

A survey by Leddy and Rigos of the types of lesions seen on the hands of 135 physicians over a 20-year period shows the incidence of epitheliomas and ulcers as follows:

	1919 to 1933	1934 to 1939
No. of patients	55	80
Epitheliomas	18	21
Ulcers	15	9

The majority of the lesions were on the dorsal surface of the fingers with the greatest number on the left index finger.

[redacted]

In the above mentioned series of Saunders and Montgomery epitheliomas were found in 10% and chronic non-healing ulcers in 52%. The hands were the site of injury in 78% of the patients of which only 10% were physicians or dentists. The photographs below illustrate the type of changes which can occur after multiple exposures to low doses.

1119127

Figure 2

1119128

Figure 3



1119129

Part II

Hand Study Program and Technic

a. Skin Appearance.

Our first efforts to study hands for radiation effects consisted of routine hand inspection for gross changes. Special attention was paid to color and texture of the skin, nails and hair. Notes were made of flattening of finger ridges, dryness or glossiness of skin, particullarly in the nail fold area, telangiectases, keratoses, pigmentation and the presence or absence of hair. Repeat hand examinations were made at 6-month intervals, also at the time of employment of new individuals going into "exposed" groups, and at the time of transfer or release.

b. Hand photographs.

Very soon it became apparent that descriptive notes on the gross appearance of hands were rarely objective and complete. Too often the appearance of things not noted on previous examinations led to controversy over their time of appearance, rate of growth, etc. In the summer of 1944 we began photographing hands in such a way as to accentuate pigmentation and surface texture as much as possible. After much testing in collaboration with the photostating department we adopted the following technic. A table was built with an opal glass top on which the hands are placed. Two 100-watt bulbs under the glass eliminate shadows cast by the fingers. Four photo flood No. 2 lamps obliquely placed are used for sharp surface illumination.

An Eastman precision enlarger is supported on the table so that it moves freely up and down. A camera back adapter and film holder for 2¼ x 3¼ inch cut film is attached. This size was selected for convenience and economy. The resulting pictures are sharp enough to permit enlargements up to 8 x 11 inches to be made for closer examination of any questionable area. Routinely, however, the 2¼ x 3¼ negatives with contact prints are filed for each individual. A contrast process orthochromatic film has been used most successfully to demonstrate both the texture and pigment distribution in the skin and nails. (Figs. 4, 5 and 6).

Our next step was to look for a means of recording the distribution and intensity of a skin erythema. Kodachrome 35 mm film used in a camera back adapter on the same unit proved to be unsatisfactory, because of difficulty in getting sharp focus. We then tried 2¼ x 3¼ inch cut film and had no difficulty focusing but had considerable difficulty getting uniform color reproduction. An erythema could be photographed easily but the accuracy of color reproduction was unpredictable and could not be duplicated on successive photographs when all other factors were controlled. In our hands Ansco color film was no more satisfactory; hence we have used color photography only to record distribution of erythemas or interesting lesions and not as a means for comparing redness at one examination to that at another. Should

Figure 4





1119131

Figure 5



1119132

Figure 6



such a problem become important in this work, an adaptation of the Keuffel and Esser color analyzer could be used for a precise objective measure of color changes. (Harris, Leddy and Sheard).

Infra red sensitive film was tried briefly in an attempt to photograph the subsurface vascular pattern. The veins on the back of the hand are accentuated by this technic. As anticipated the surface texture, scars and blemishes did not appear in the photograph, nor did an erythema which appeared on both contrast process orthochromatic and Kodachrome film. The special features of this type film added nothing to our previous knowledge, so no further investigations along this line have been done.

c. Finger ridge impressions.

In the fall of 1943 we were advised of some work being done by Dr. Roger Harvey on the effects of radiation on finger ridge detail. (AM-1592 CH). This study was suggested by observations made earlier that year when a federal agent was sent to Rochester to finger print local hospital personnel for security purposes. It was found that some local radiologists had such flattened ridges that good ink prints could not be obtained. Dr. Harvey and his group investigated means for studying these changes and arrived at a simple and effective technic. The material selected for making impressions is Kerr dental compound which softens at 132°F. By means of warming the surface of the wax and pressing a finger firmly on it good impressions can be obtained. Sticking can be prevented by dipping the fingers in water before imprinting. (Fig. 7). Harvey was able to recognize characteristic changes in the ridge detail of persons with histories of repeated exposure to radiation. He adopted the following system of grading:

1. No change.
2. Early flattening of ridges, localized, patchy, or generalized.
3. Localized atrophy of minimal degree.
4. Localized atrophy of moderate degree.
5. Localized atrophy of advanced degree.
6. Generalized atrophy of minimal degree.
7. Generalized atrophy of moderate degree.
8. Generalized atrophy of advanced degree.
9. Atrophic fissures.
10. Proliferative changes.

In a survey of 1033 radiologists, 67% were found to have abnormalities in ridge detail. Among orthopedists and dentists also surveyed the abnormal findings were 55% and 40% respectively. These figures are compared with the 1% of similar or confusing changes found in a control group of individuals without known radiation exposure.

Arrangements were made with Dr. Harvey to have Kerr dental compound sent here (correspondence). Routine finger ridge impressions were made at 3 month intervals for exposed personnel and at longer intervals for control groups. The wax impressions and information

Figure 7



1119135

concerning the probable exposure of each individual were sent to Dr. Harvey's laboratory. The wax plates were examined and a report was returned to us. The information so obtained was recorded in our files. To date (July 1, 1945) 1287 individuals have been studied in this manner. The results are given in part III.

d. Capillary studies.

An erythema produced by x-ray requires in the hundred of r as a single dose. It appeared highly unlikely that such exposures would occur here. On the contrary hand exposures anticipated would probably be repeated exposures at very low doses and of varying qualities. All evidence and speculation suggested that under such conditions any changes which occurred would be unheralded by grossly detectable acute reactions. Skin effects if occurring at all would more nearly approximate the slow insidious chronic dermatitis of physicians, dentists and other professional people exposed similarly. There is some evidence that the mildest forms of chronic reactions have the longest latent intervals and further that many of the late chronic changes can be attributed to underlying vascular damage such as obliterative endarteritis and thrombosis of the smaller vessels and lymphatics.

For these reasons we proposed a program to study capillaries in the skin of personnel working here. The technic for making direct capillary observations was introduced many years ago by Lombard after preliminary notes by Heuter that such observations were possible. The

1119136

method has been applied to irradiated skin surfaces by Schugt, David, Pohle, Shaffer, Pendergrass, and others. In most instances the skin of the forearm has been used for experimental studies but for our purposes the skin of the nail fold proved to be a more satisfactory site for the following reasons:

1. This area is quite sensitive to radiation.

2. It is in a position to receive larger doses under laboratory conditions than skin of the forearm.

3. It requires no special preparation other than cleaning.

4. The exact site can easily be relocated.

5. The capillaries are morphologically and physiologically well suited to repeated observations.

6. The procedure is not inconvenient nor painful to the patient.

Nail fold capillary observations have been made by many investigators interested in a variety of problems so the behavior of these vessels in health and disease is well known.

The normal nail fold consists of a thin layer of skin extending a short distance over the nail plate in such a fashion as to present a slightly curved area of skin roughly 5 x 6 mm which can be illuminated and observed under a microscope. (Fig. 6) The epidermis growing outward on the nail plate is seen microscopically as a translucent homogenous layer which joins the corium in a series of scallops or papillae. This papillary border is sensitive to touch and encloses a tissue fluid filled space surrounding the terminal vascular loops (Heimberger).

In a normal nail fold the papillae are regular and evenly spaced with about 7 to 10 per mm. Each contains a centrally spaced capillary loop, the tip of which is 0.1 to 0.3 mm within the border of the corium. (Deutsch). These first row capillaries are seen in profile with their long axes parallel to the surface of the skin. Each has an afferent or arterial limb and an efferent or venous limb of slightly different calibers. The arterial limb is narrower and has been measured as 0.007 to 0.016 mm with an average diameter of 0.009 to 0.012 mm. The blood cells can pass in single file without distortion. The venous limb is slightly wider, measuring 0.009 to 0.020 mm and permits two cells to pass simultaneously. The widening of the caliber occurs at the tip or just before the tip on the arterial side of the loop. The flow is one directional in this area and normally goes from the narrower to the wider limb. The rate of blood flow varies from one capillary to another and under different conditions in the same capillary. Occasionally there are gaps in the stream where there are no cells. At those points the capillary outline cannot be seen since the walls are not visible and only the presence of cells enables us to determine the capillary pattern. (Bordley, Grow and Sherman) (Brown) (Brown and Giffen) (Carrier) (Crawford) (Deutsch) (Packing and Brown) (Redisch and Polzer).

Figure 8



1119138

It has been reported that nail fold capillaries, unlike those of the skin elsewhere, do not open and close intermittently but remain open all of the time. (Carrier) (Crawford). In other respects they are like skin capillaries in that they respond to heat, cold and chemical stimuli in the same way. Their arrangement is such that prolonged and accurate observations can be made of the same capillary or group of capillaries.

It was here, for example, that studies have been made of the average time required for the small vessels to return to normal after the injection of histamine, adrenaline, and other stimulants. (Brown) (Carrier) (Jahsman and Durham) (Wright). When the capillaries are chilled or treated with adrenaline or adrenaline like substances, contraction occurs primarily on the arterial side of the loop. The column of blood on the afferent side is narrowed. In the skin of the hand and forearm some of the vessels completely disappear. Warmth and histamine or histamine like substances dilate the capillaries and induce increased blood flow. The dilatation which follows asphyxia and anoxema is different in that it affects primarily the venous segment of the loop without inducing increased blood flow. Under these conditions the skin remains cold and has a purple cyanotic hue. (Bruns and Konig) (Carrier) (Grant) (Lewis). It has been known for many years that persons with vasomotor instability have exagerated and prolonged vascular reactions. (Mueller) (Parrisius). These have been observed and timed by studies of the nail fold capillaries. Deutsch reports observations on a series of 42 individuals of whom 29 had clinical signs of Raynaud's disease. The capillaries were very irregular in size and pattern. In early or mild cases many capillaries had narrowed spastic arterial limbs. The venous limbs and the subpapillary plexus were dilated and congested. In more severe cases the entire capillary loop was a wide atonic structure in which the blood flow was sluggish. Some vessels were thrombosed and leaking. Observations were made on 15 of these patients after preganglionic sympathectomy. There was no change in the number of capillaries. The large atonic loops became narrower. Blood flow was greatly increased. Patients with Raynaud's disease were also studied by Brown who observed the same large atonic loops and some partly filled contracted loops. It was his opinion that a pathological conditions existed when more than half of the capillary loops appeared abnormal in form or flow. In clinically normal individuals similar abnormalities appear as isolated phenomena.

In another study a group of draftees suspected of having incipient thrombo angiitis obliterans were observed. These young individuals had an abnormally high percentage of distorted terminal capillaries. There were many figure 8 forms, rosettes and coiled loops. Some of the normally shaped hair pin loops were seen to have beaded spastic arterial limbs through which the blood spurted irregularly. Chilling resulted in the marked contraction with obliteration of some vessels. The dilatation time was greatly prolonged (Jahsman and Durham). In polycythemia vera the capillary pattern is not altered but the venous segment of the loops and the collecting venules are seen to be engorged. In the skin on the back of the hand where normally only some of the capillaries are open there is an increase of 50% over the count of normal individuals. (Brown and Giffen) (Brown and Sheard). Chronic

nephritis is associated with irregular loops with dilated venous segments. (David and Gabriel).

Patients with cardio vascular disorders including arteriosclerosis, hypertension, luetic and rheumatic myocarditis, auricular fibrillation and aortic insufficiency all have normal capillary patterns providing there are no signs of decompensation. (Hisinger-Jagerskiold) (Jurgensen) (Neumann) (Schur) (Secher) (Weiss) (Weiss and Frazier). Decompensation begins a chain of events which results in permanent morphologic changes after a period of time. The venous limos and underlying plexus become engorged. The blood flow is seen to be very sluggish. Dilation, which begins on the venous side, extends to the arterial side and the capillaries become long and tortuous. With clinical improvement and recompensation, the capillaries resume a more normal appearance with increased rate of blood flow but not much change in caliber. (Crawford)

Migraine and myxedema are not associated with morphologic changes but the capillaries appear blurred and indistinct. Myxedematous patients sometimes appear to have an accumulation of visible material between the capillaries. After treatment the capillaries become more distinct and the accumulated material disappears (Zondek, Michael, and Katz). Patients in an attack of migraine, if given ergotamine tartrate, experience relief of their symptoms. Simultaneously their blurred capillaries become distinct. Recurrence of symptoms is synchronous with blurring of capillaries (Redisch and Polzer).

The picture is quite different in hypothyroid children whose capillaries have not yet reached a mature form. In such cases the nail fold retains the primitive pattern seen in infants. With early adequate treatment the terminal loops develop and mature, although the entire process is retarded. (Leader) (Powdermaker) (Wright and Duryee).

Arrested development at any point results in the persistance of immature forms. Mongolian idiots are found to have capillary development roughly corresponding to their mental age. Children with normal or superior intelligence, even when physically retarded have capillary patterns corresponding to their chronological age. (Leader) (Olkon) (Powdermaker) (Wright).

Normally, terminal loops are not seen in infants. In the newborn there is a flat corium in which is a flat network of anastomosing vessels. During the first few weeks the border of the corium begins to indent and short vascular loops can be seen sprouting from the plexus. At the end of the first year there is a well developed papillary border enclosing a full compliment or single looped terminal capillaries. From then on the only normal changes are increasing indentation of the corium, lengthening of the existing capillary loops and slowly increasing tortuosity with advancing age. The basic pattern and the number of terminal vessels remains the same (Brown) (Jaensch) (Leader) (Powdermaker) (Weiss and Frazier) (Wright and Duryee).

The capillaries in the skin of the forearm of normal individuals and patients with arteriosclerosis and hypertension were compared by Weiss and Frazier with the following results:

No. of patients	Condition	Ages	Average Cap/sq. mm.
20	Normal	12 to 61 yrs.	34.6
20	Hypertension	18 to 75 yrs.	35.2
20	Arteriosclerosis	50 to 74 yrs.	30.5

Age made no appreciable difference as is shown by the following grouping of the same series of counts.

Ages	Cap./sq. mm
10 to 29	33
30 to 49	36
50 to 82	33

The presence of marked capillary morphological changes and variations from normal in the number of loops cannot then be attributed to normal aging processes. In the absence of severe peripheral vascular disease, heart failure, and mental retardation, another condition has been reported to alter the capillary picture. Mental deterioration has been found to coexist with bizarre terminal capillaries. Olkon studied 2000 psychotic patients in good physical condition. He found a tendency toward fewer capillaries particularly in schizophrenics and hebephrenics. Many of the existing loops were spiral, stellate and dilated. There was little uniformity. Capillary disorganization was progressive as the mental state became poorer. Pastinf and Brown studied 176 patients with epilepsy. In this series the epileptic patients without signs of mental deterioration have normal hair pin loops predominating. The mentally deteriorated epileptics had many more tortuous vascular limbs and irregularly dilated branches. All of these patients were under forty. It is interesting that these authors also found more changes in the dactylographic patterns of the mentally deteriorated patients.

Griffith has examined 500 patients of which 8 were diagnosed as neurasthenias and had definite capillary morphologic abnormalities. Of the 8 all but 1 had psychotic symptoms dating from early life. The author concludes that abnormal capillary configuration in the absence of peripheral vascular disease indicates a constitutional instability which may be manifest as a psychopathic disorder.

A summary of the previously reported capillary observations then would indicate:

1. Normally the vascular capillary pattern is attained in early childhood.

2. The pattern persists essentially unchanged in healthy individuals until death.

3. Failure to develop a mature pattern is due to constitutional defects and severe metabolic disorders which interrupt or retard normal development.

4. Aberrations of a mature capillary pattern are associated with peripheral vascular diseases, chronic nephritis, cardiac failure and mental deterioration.

5. Marked morpholigical capillary variation in the absence of any of the above conditions must be attributed to some other major disturbance.

Because of the well-known radiation effects on the small vessels of the skin it is our feeling that detectable changes in the nail fold capillaries may follow exposure to radiation. It is consistent with capillary physiology that capillary functions should be impaired first, then be succeeded by deviations in pattern and structure.

Such structural and functional impairment may indicate the point at which radiodermatitis cannot be sustained without the danger of incurring progressive mutilating lesions.

Capillary observations were begun here 5 months ago as a routine part of the hand examination. The technic is simple. A Spencer microscope with a 6x ocular and an extra low objective (24 mm) has been used. With this we use reflected light from an ordinary projection type bulb in a housing equipped with a filter holder and condensing lens. Vertical light sources were tried unsuccessfully. Oblique light gives the most satisfactory illumination. A Corning glass filter (No. 4445) is used to remove most of the heat and to give a pale green light which affords good contrast between vessels and background.

The subject scrubs the nail fold area briefly with a soft brush to remove debris and loose squamous epithelium. A drop of mineral oil is placed on the nail fold. Immersion oil (cedar oil) can be used but has no particular advantage. The subject sits with his arm resting at cardiac level and his finger supported in a clamp on the microscope stage. (Figs. [illegible] and 10).

The light is adjusted at an angle to illuminate the capillaries and avoid surface reflection from the oil. For making the counts we use an ocular micrometer ruled into 30 small squares. The finger is moved by means of the mechanical stage so that the tips of the last capillaries just coincide with the outermost line of the micrometer. We count all capillaries appearing in the upper 6 squares which include an area on the nail fold of 3.0 x 0.5 mm. Fingers with marked curvatures need to be readjusted during the count so that the terminal capillaries are identically placed in each small square.

We learned very soon that the capillary tips proximal to the terminal row varied considerably while the terminal row capillaries changed little if at all in number or pattern even after vigorous stimulation. Variations in the count seemed to be due to actual changes in the number of visible capillary tips or to shifting the field so as to include more or less of the skin away from the cuticle. Therefore we record both the number of terminal row capillaries and the total number of vessels appearing in these 6 squares. The skin capillaries as previously noted appear and disappear in response to such stimuli as temperature changes and mechanical or chemical irritation. The terminal row capillaries of the nail

Figure 9



1119143

Figure 9a



1119144

Figure 10

1119145

fold do not seem to do this, perhaps because so much of their length is visible that even with contracted limbs they are still visible. We have found that vigorous scrubbing failed to alter the terminal row count of 2 individuals. Dry heat from an infra red lamp which produced a painful erythema also failed to change the number of visible terminal row loops. In each instance the vessels appeared more prominent and were filled with a solid stream of rapidly moving blood. Immersing the hand in water at 10°C and at 2°C for 10 minutes had no effect on the nail fold pattern or the count although the skin was noticeably cold and cyanotic. Soaking the hand in water or allowing oil to stand on the skin for more than 10 or 15 minutes caused a gradual clouding of the picture and obscuring of the finer vessels. The area regained clarity after drying and a half hour rest.

The effect of increased and decreased intravascular pressures was studied. A sphygmomanometer was applied to the upper arm and inflated to above systolic pressure. All blood flow in the nail fold capillaries stopped and wide clear places appeared in the loops between segments of cell-containing blood. As the pressure was gradually released to a point midway between diastolic and systolic pressures the blood began to flow again but appeared granular for several seconds before it resumed its solid appearance. As the pressure was maintained at about 90 mm the venous side of the loops became engorged. The flow was sluggish and in some places gradually stopped. Under these conditions the clear spaces did not reappear. Instead the loops were a solid color and very prominent. When the pressure was released completely the capillaries resumed their original appearance in a few seconds.

A few experiments were done using intravenous fluorescein because of some work done by Lange and Boyd on patients with peripheral vascular disease. With doses up to 2.cc there was no visible illumination of nail fold capillaries even several minutes after fluorescence was detected in the conjunctive and lips. There was, however, a gradual accumulation of dye just within the border of the corium. This technic which may be useful for capillary permeability studies was not studied further since visible light gives better capillary definition for our routine observations and counts.

Capillary photography has proved to be a complex problem, hence it has not yet become a routine procedure. It is difficult to get more than a few capillaries in focus simultaneously since the surface of the finger is convex and also since the more proximal capillaries exist on many different planes.

A special microphotographic unit (ML 3c254) has been designed and constructed for capillary photography. It consists of a rigid funnel shaped camera box with a 3 x 4 inch plate holder and a 24.3 mm Bausch and Lomb objective. The only moving part is the stage which moves by means of hand screws in 3 directions. This permits centering and focussing with a minimum of effort and insures uniform magnification. (Figs. 11 and 12).

The camera is equipped with a separate lens system which is adjustable to be in focus with the ground glass plate. Lights identical with those

Figure 11

1119147

Figure 12



1119148

used for observation are mounted on either side of the stage. For photography the only light filter necessary is one to remove some of the heat. For this we use a Corning filter #3966 in each lamp housing. The contrast process orthochromatic film requires 1/10 second exposure and color film 1/2 to 1 second.

Preparation of the finger for photography is the same as for observation. Frequent application of oil often helps eliminate highlights. The 3rd and 4th fingers have been used most often since the skin here is usually in the best condition. Subjects with thick skin, heavy pigment or underrolled nail fold margins have not been photographed successfully. To date we have been able to photograph successfully the capillaries of 32 individuals including several negroes.

[redacted]

Part III

Results (up to July 1, 1945).

In order to keep our records in a concise and accessible form we have used an alphabetical file of 5 x 8 inch cards on which information is recorded. (Fig. 13) At each hand examination notes are made of the appearance of skin and nails. Any deviations from normal are listed. Photographs of hands or capillaries are indicated by checks in the appropriate column. Finger ridge impressions are also indicated by a check, to which is added the report of the dermatoglyphic unit. Capillary counts and photographs are recorded in the final column.

The information obtained has been tabulated by sections since this gives a rough idea of the possibility of exposure of the individuals. It is true that many persons working in the so-called high exposure groups may have had little or no radiation. It is less likely that persons in low or non-exposed groups could have changes due to exposure. In general they were estimated as follows:

1. Administration - Low or none.

2. Chemistry C_1 - High
   C_2 - Medium
   C_3 - High
   C_4 - Medium

3. Health - Biological - High
   Clinical - Low or none

4. Physics - Experimental - High
   - Theoretical - Low or none.

5. Metallurgy - Medium.

6. Shop
   A (Ryerson) - Low or none
   B (Site B) - Medium.

a. Macroscopic abnormalities.

Routine hand inspection brought to our attention many superficial injuries of traumatic origin, several cases of neurodermatitis, and many instances of acute asteatosis which was particularly common during the winter. We were able to give treatment where necessary and to give advice for skin protection with resulting improvement in skin condition. This was felt to be important for two reasons:

1. Normal fat containing skin is more resistant to all types of damage.

2. Breaks in the skin surface afford a possible portal of entry into the body for active materials.

1119150

[redacted]

Figure 13

Name Group Section

Date	Skin Appearance	Photograph		Ridges	Capillaries
		Black and White	Color		

1119151

Whenever possible persons with open skin lesions were removed from work with active materials until healing had taken place. In combatting asteatosis which occurred chiefly among persons working with organic solvents, or among those who had to scrub their hands repeatedly, we advised the following precautions:

1. Use no abrasive or strong soap. Instead use a 28% soap solution (not tincture of green soap).

2. Apply aquaphor, lipoid cream, or lanolin after each wash and overnight if necessary.

3. When wearing rubber gloves use a glove talcum to which 1% fat has been added. (For this purpose we used 1% spermaceti.)

The results of the hand examinations are summarized in Table 1. Only the most common findings are listed. Dry skin includes all degrees from peeling of the finger tips to general asteatosis. If the skin was found dry and peeling over a period of three months, it was considered persistant dryness. The heading keratoses includes warts, callouses, or any localized thickening of the epidermis. Nail fold defects include glossy reddened skin and thickened or cracked margins. Nail ridging is subdivided into direction of markings since fine longitudinal ridges are normal and conform to the pattern of the dermal papillae as do the skin ridges. Only accentuated or irregular longitudinal ridges are tabulated. The chart shows no tendency toward clinical changes in the skin and nails of individuals in the exposed groups as compared with the others.

Table I (continued)

Keratoses		Nail Fold Defect		Telangec-tasia		Pitting		Longitudinal Ridges		Diagonal Ridges		Transverse Grooves	
No.	%	No.	%	No.	%	No.	%	No.	%	No.	%	No.	%
7	12	11	19	1	2	6	10	13	24	2	3	3	5
26	17	58	39	7	5	35	24	57	38	16	11	23	15
8	29	6	21	1	3	8	29	12	43	1	3	5	18
4	15	8	30	1	4	4	15	11	41	0	0	4	15
13	25	14	27	5	10	17	33	21	44	3	6	6	12
24	18	29	21	9	7	32	23	37	27	6	4	28	20
11	12	18	19	16	17	16	17	23	24	8	8	19	20
12	9	23	18	12	11	18	14	18	14	[illegible]	[illegible]	16	13
21	15	33	24	5	4	14	10	27	20	10	7	7	5
5	21	11	46	8	33	11	46	19	79	5	21	4	17
35	33	23	21	8	7	7	7	19	17	0	0	7	7
9	28	4	13	0	0	4	13	9	28	1	3	5	16
175	18	238	24	73	8	172	18	256	27	53	5	127	13

1119153

b. Finger ridges.

Impressions have been made of the ridges of 1287 individuals of all occupations on this project. A total of 2332 impressions were made here and analyzed in Dr. Harvey's laboratory. The individuals so studied have worked here for lengths of time varying from 1 week to 2½ years. In many instances pre-employment impressions were obtained but since the ridge study was begun some months after this project was organized a few individuals were working here before initial studies were made. There are also some cases of radiation exposure to the hands before employment here and for such individuals we have no pre-exposure record. Altogether we have reports of abnormalities in the ridges of 194 persons or 15% of those studied. Initially normal prints followed by abnormal changes were found in 61 cases. Initially abnormal prints followed by 1 or more normal impressions were found in 42 cases whereas consistent and repeated abnormal changes were found in 91 cases. We have been perplexed by those which appear abnormal on one occasion and subsequently produce a normal impression. It is our feeling that these may represent mechanical or abrasive flattening of the ridges with ultimate repair such as we have found among our machinists in a shop where no active material is handled. Thus the value of a single impression is questionable except in the case of marked degenerative or hypertrophic changes. Repeated studies avoid the chance of mistaking mechanical effects for true radiation changes. A real atrophy which in the case of radiation damage is based on destruction of the deeper skin layers does not repair itself. An analysis of the distribution of finger ridge abnormalities is given in Table II. With one exception the high percentages of abnormalities fall into the groups having the highest exposure, namely, Chemistry 1, Chemistry 3, Chemistry 4, Biology and Metallurgy. The surprisingly high figure of 27% for A shop personnel must be attributed to something other than radiation since the machinists there do not handle active material. Subsequent study should be made of the nature and the persistence of changes found there. The overall picture of 15% abnormal findings in our personnel is considerably higher than Dr. Harvey's 1% for his control group and considerably lower than the 40 to 65% among individuals with long histories of exposure.

Table II

Finger Ridge Abnormalities

		Number of Persons	Normal		Abnormal	
			No.	%	No.	%
Administration		152	147	97	5	3
Chemistry -	C-1	167	125	75	42	25
	C-2	33	32	97	1	3
	C-3	33	23	68	10	32
	C-4	108	92	85	16	15
Health	Biological	129	105	81	24	19
	Clinical	109	99	91	10	9
Metallurgy		201	166	83	35	17
Physics	Experimental	163	148	91	15	9
	Theoretical	15	15	100	0	0
Shop	A	109	79	73	30	27
	B	68	62	91	6	9
Total		1287	1093	85	194	15

1119155

c. Nail fold capillaries.

Capillary studies have been made of 838 individuals of all occupations. Altogether 1798 counts were made of which 1342 were total counts and 456 terminal row counts. The distribution of counts according to sex, color and possible exposure is given in Figs. 14 to 33. As can be seen there is no appreciable sex difference but there is an appreciable race difference. We attribute the tendency toward lower counts in the negro to pigment in the epidermis which obscures the finer vessels. In the nail fold of deeply pigmented or thickened skin, few or no capillaries may be seen. In most instances, however, the terminal row is visible and can be studied for morphological changes.

Exposure differences are less apparent but there is a tendency toward higher counts in the medium and high exposure groups. (Table III) Several factors may influence this and should be further studied. First there is a higher percentage of colored individuals in the control or low exposure group than in the medium or high exposure groups due to our placing the janitorial staff in this category. On the other hand many individuals in the medium and high exposure groups may have had little or no exposure and hence tend to obscure what might be a more appreciable difference in counts of non-exposed and exposed personnel. A third factor is the influence of age and state of health on capillary counts. Our results have not been analyzed from this point of view as yet. The mean values given in Table III are based on all counts including both total and terminal row counts. As can be seen from the distribution charts, terminal row counts fall within fairly narrow limits, usually between 19 and 25, whereas total counts vary more widely with their peak in the 60's.

Similarly an individual's terminal row counts tend to be fairly consistent, while the area counts may fluctuate more widely, probably due to appearance and disappearance of skin vessels proximal to the nail fold. Subsequent observations are necessary to determine which technic is more useful in this type of study.

d. Statistical analysis of capillary counts - G. Sacher.

Means and standard deviations were computed for the classes listed in previous tables. These statistics are based on the data of Figs. 14 to 31. The data were first grouped in steps of 10 counts.

The sex, pigmentation and hazard differences, with their standard errors and critical ratios are given in table III and IV. Both the medium and the high exposure groups have mean capillary counts which are significantly higher than the counts for the low group. The difference between medium and high exposure groups is not significant.

The difference between sexes is not significant, but the difference between pigmentation groups is very large. Since the breakdown into "white" and "colored" on the one hand, and into exposure groups on the other, is based on the same total population, the possibility exists that there is interaction between these categories. Thus, if the ratio of the different pigmentation groups changed from one exposure group to

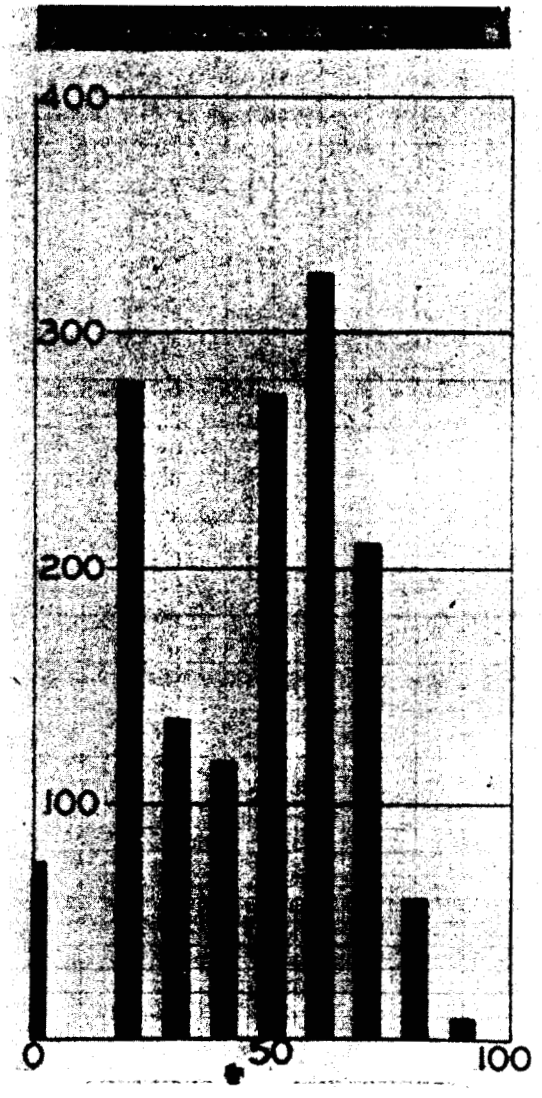



1119157



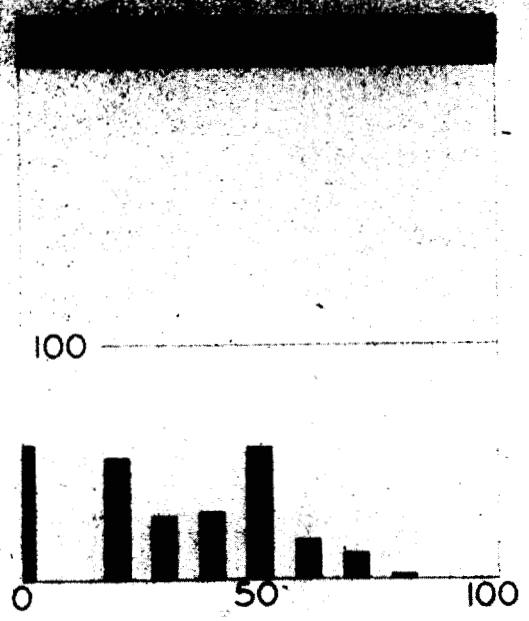

1119158

Figure 18. LOW EXPOSURE TOTAL COUNT

Figure 19. MEDIUM EXPOSURE TOTAL COUNT

Figure 20. HIGH EXPOSURE TOTAL COUNT

1119159



1119160

Figures 23 and 24

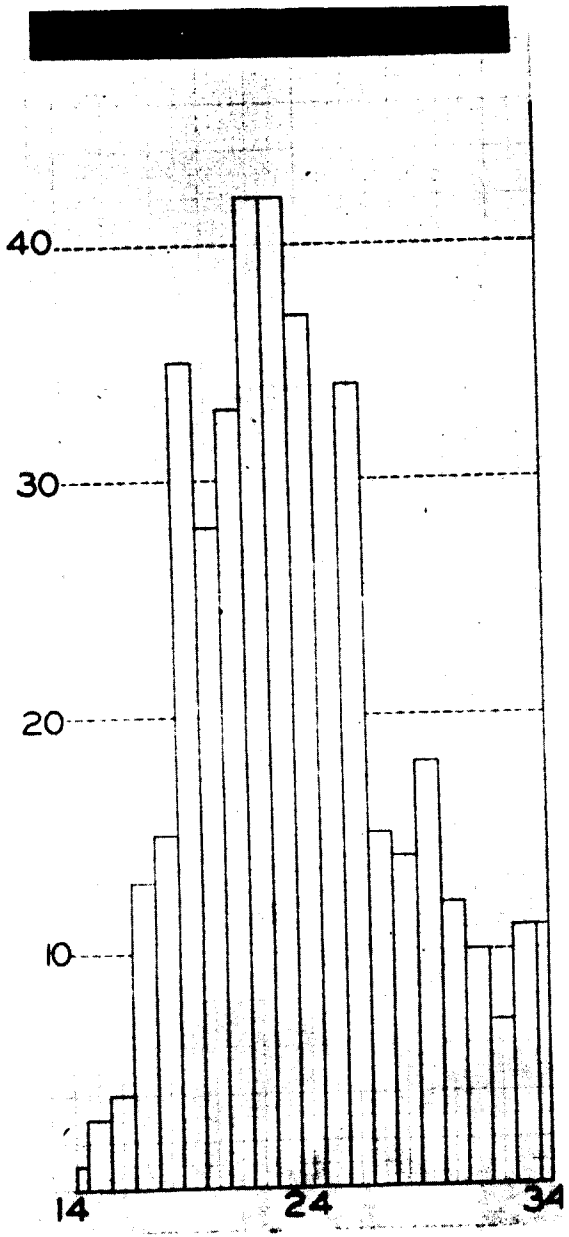

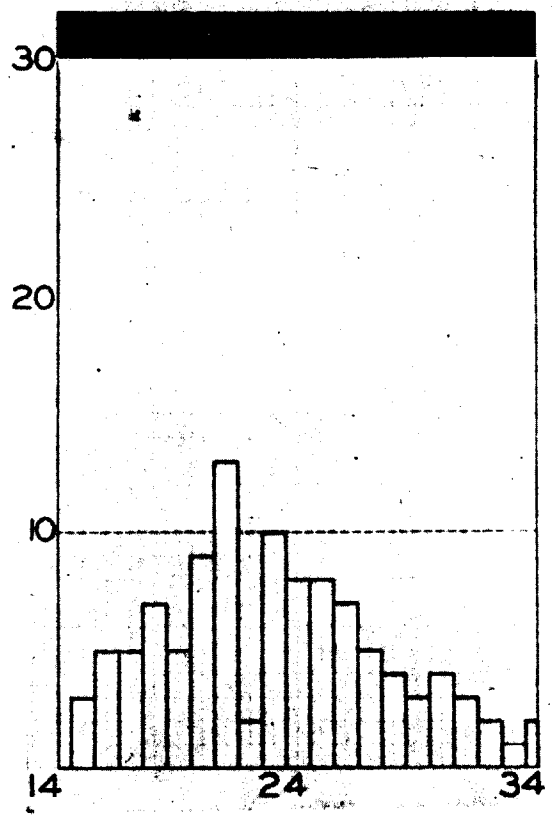

Figure 25 and 26

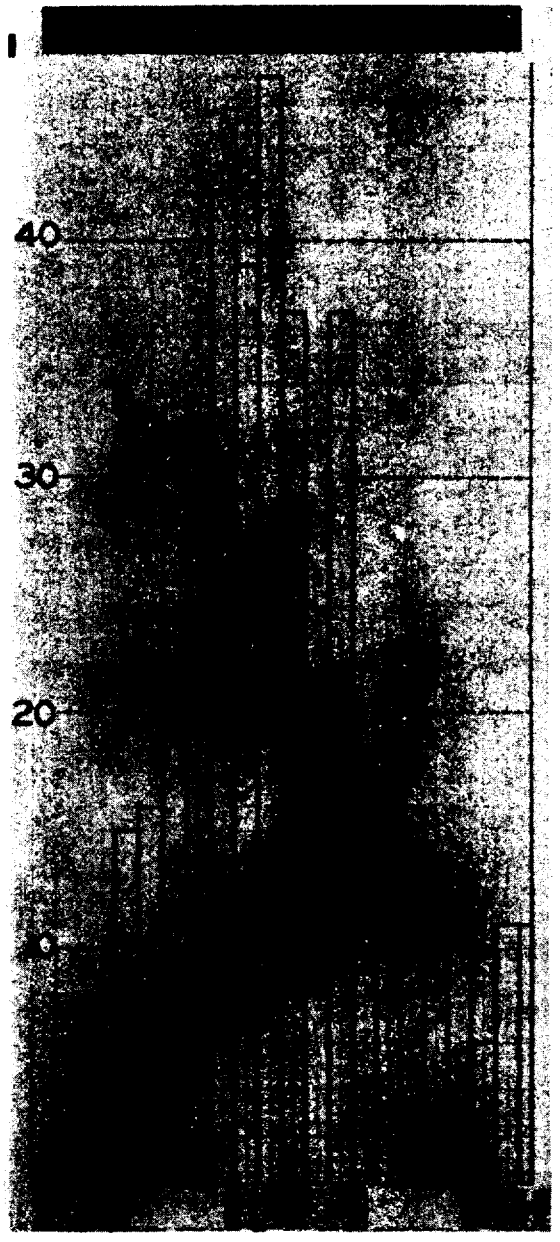



1119162

1119163

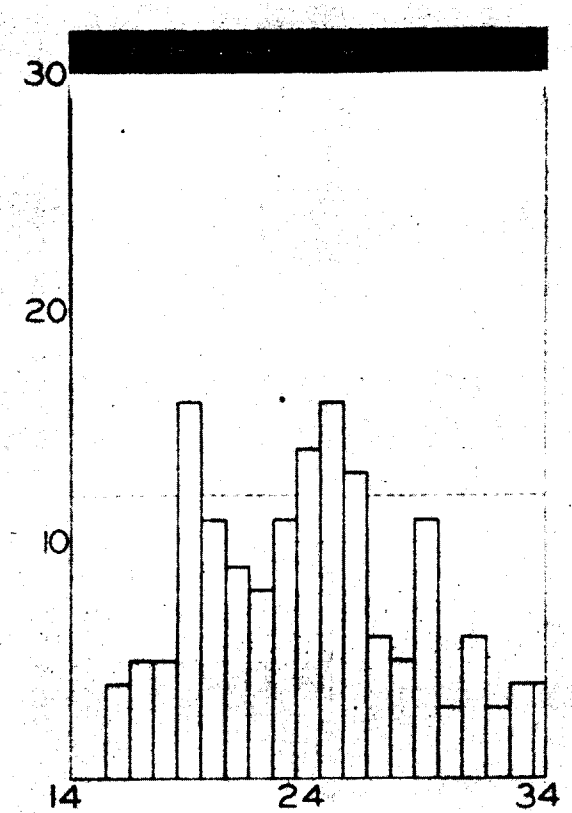

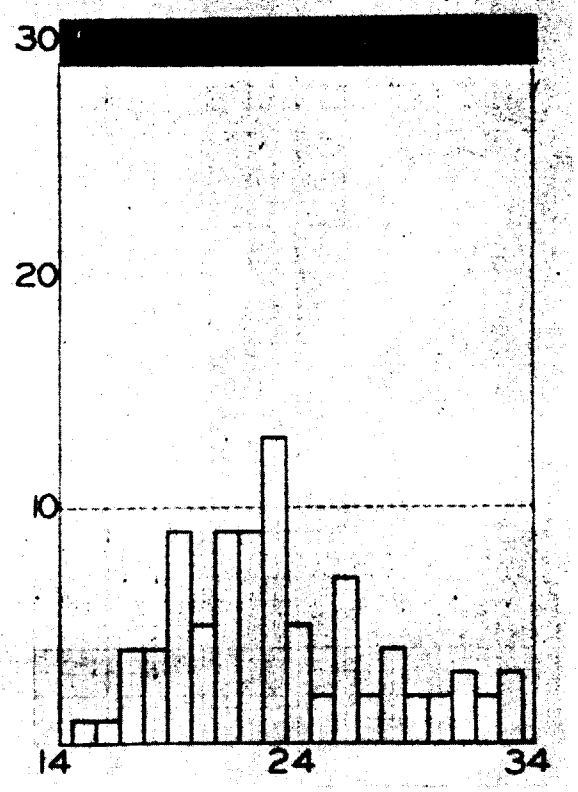

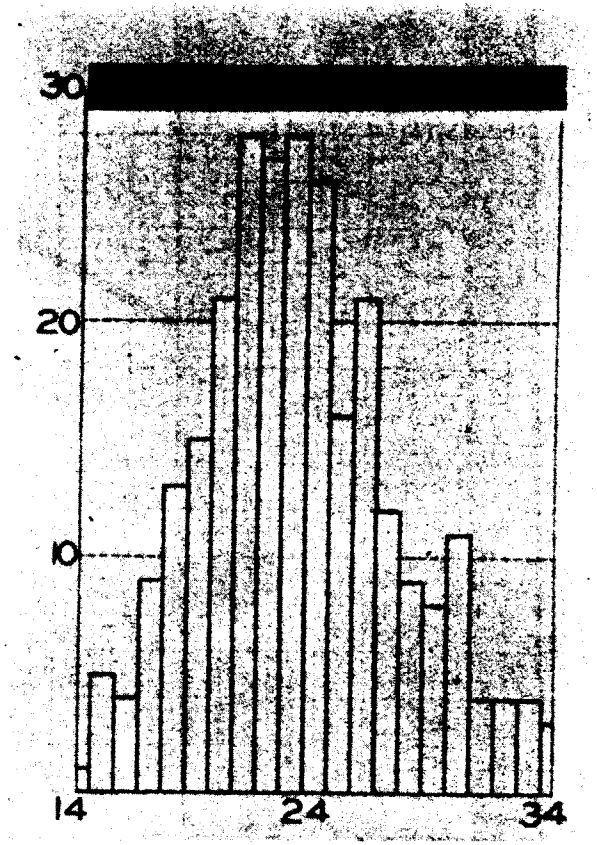

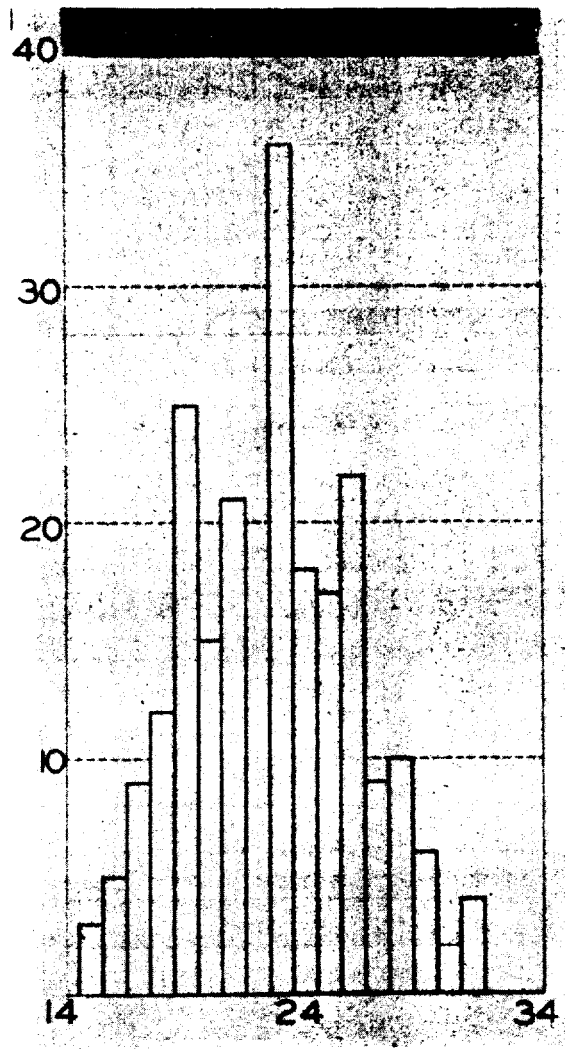
[redacted]
40
30
20
10
14
24
34

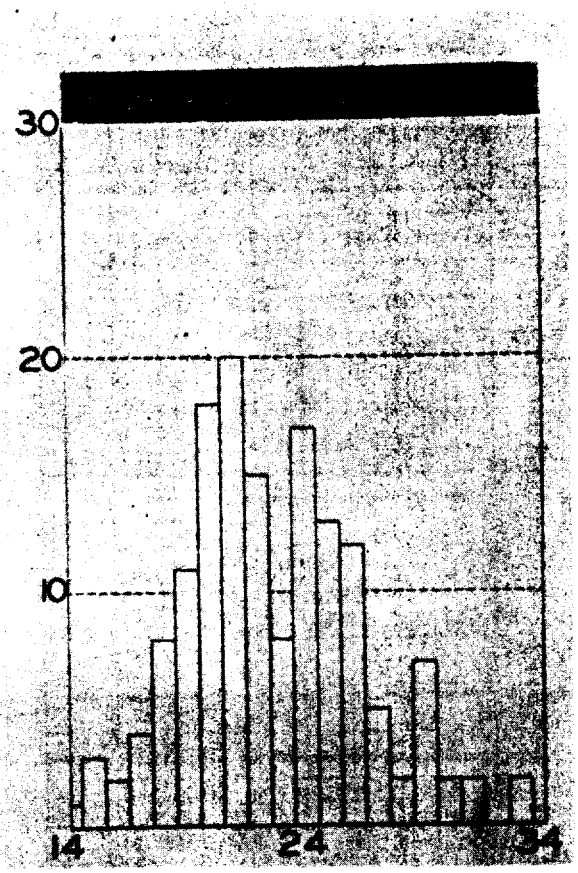
[redacted]
30
20
10
14
24
34

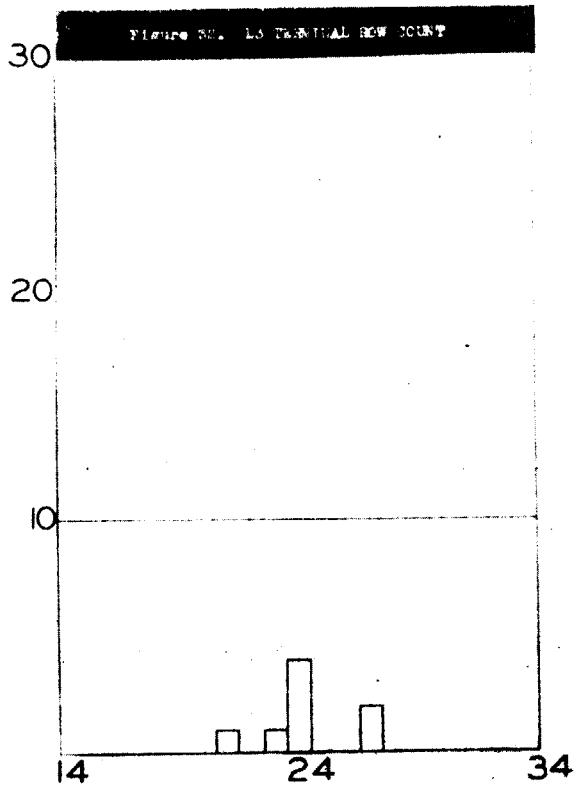

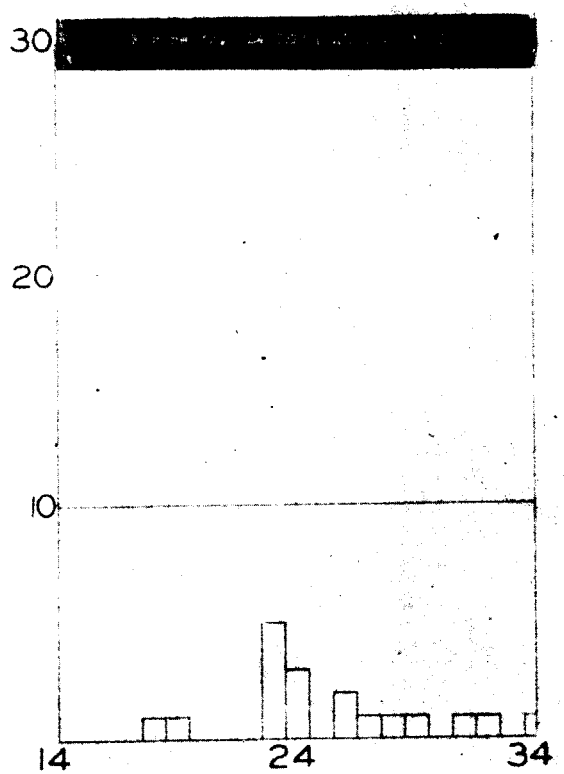

1119165

Table III

Means, Standard Deviations, and Standard Errors of Means of Capillary Counts on Various Classes

	M ± σ_M	σ	N	Total
Male	48.77 ± 0.50	18.86	1431	
Female	47.18 ± 0.86	17.40	407	1838
White	49.41 ± 0.46	18.63	1644	
Colored	40.45 ± 1.11	16.13	194	1838
Low	46.00 ± 0.80	17.59	482	
Medium	49.87 ± 0.93	18.23	381	
High	49.10 ± 0.62	19.20	965	1828
Med. + High	49.31 ± 0.52	18.09	1346	

Table IV

Differences Between Groups, and Their Significance

	Difference	σ_D	C.R.	P
Low - Medium	- 3.87	1.233	3.[illegible]	.001
Low - High	- 3.10	1.002	3.09	.002
Low - Med. & High	- 3.61	0.953	3.47	.0006
Medium - High	+ 0.77	1.102	0.70	.48
Male - Female	+ 1.59	0.996	1.60	.11
"White" - "Colored"	+ 8.96	1.205	7.40	≈ 0

1119166

another, the differences between exposure groups could be in part or entirely due to this cause. Further statistical analysis is projected which will give an unequivocal answer to this question.

e. Capillary photography.

Satisfactory capillary photographs have been taken of 93 individuals. (Figs. 34 and 35). Repeated photographs of the same area of 3 individuals shows no change in the size, shape, position, or relative widths of the limbs of the terminal row vessels over a 5 month period. With one exception the general capillary pattern found on any finger was repeated in the others except for scars or other evidence of specific local trauma. This one exception was that of a young man with marked tortuosity of the terminal row vessels of one finger while the others were only mildly tortuous. The patient could recall no specific injury to this finger. (Figure 36).

Capillary photographs can be taken whenever the vessels can be seen clearly on microscopic observation. Thick skin or heavy pigment obscures the vessels, in which case selection of another finger often proves satisfactory. Negroes can be photographed satisfactorily even when apparently darkly pigmented if the nail fold skin is thin. (Fig. 37).

In studying the photographs we have noted certain variations from normal which appear repeatedly. In some of our subjects the collecting vessels and the superficial venous plexus can be seen as wide, prominent dark channels. (Figure 38). The plexus according to earlier descriptions in the literature is normally not seen but can be made to appear by certain vasodilators or by increased venous pressure. Apart from this some individuals show a peculiar widening of the venous portion of one or more terminal loops. (Figure 39). Such loops have a fine hairlike arterial limb with an abrupt outpouching or sacculation just proximal to the tip. In some instances the tip and venous limb are 3 to 4 times the width of the arterial limb. Such loops are often found in a field of essentially normal capillaries and seem to represent local defects or loss of tone since the adjacent vessels are normal and there is no indication of generally increased pressure. The shape of these capillaries is not altered by varying blood pressure or by stimulation. They can be recognized unchanged weeks or months later. Occasionally this sacculation and venous dilation affects many capillaries in a field. In that case there are in addition some loops with both limbs widened and no evidence of sacculation. It seems likely that the first picture is an early stage of the second and that both precede a general loss of capillary tone and the development of wide non-reactive loops, such as seen in later peripheral vascular disease or multiple telangiectasia.

Occasionally we have observed very fine short loops budding off mature loops or plexus vessels. (Figure 40). The period of observation has been too short to ascertain if these represent new vessels which will continue to grow.

Figure 34

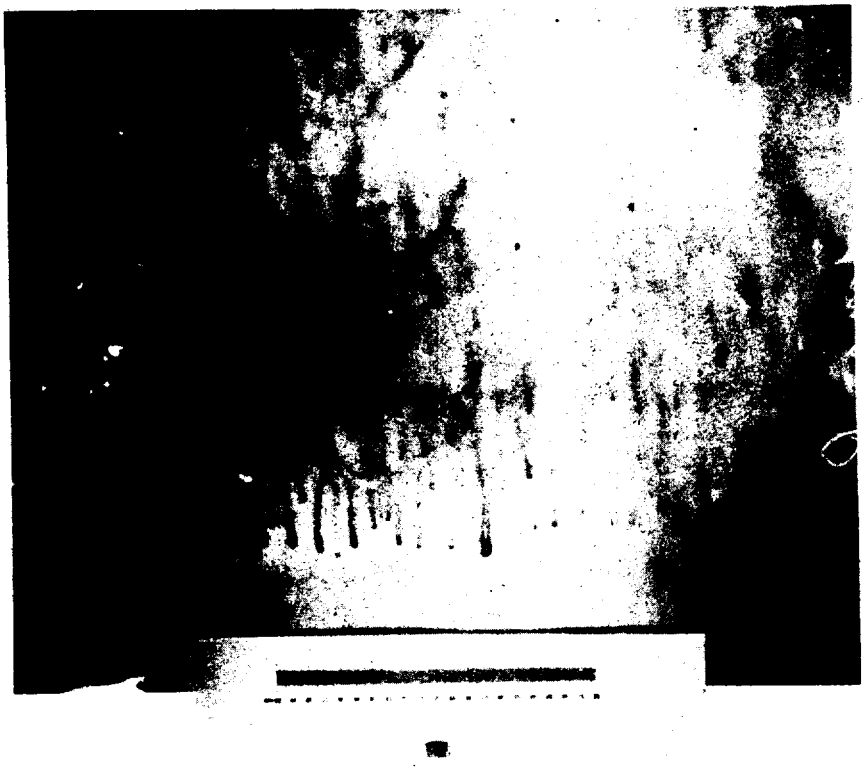

1119168

Figure 35

1119169

Figure 36

1119170

Figure 37

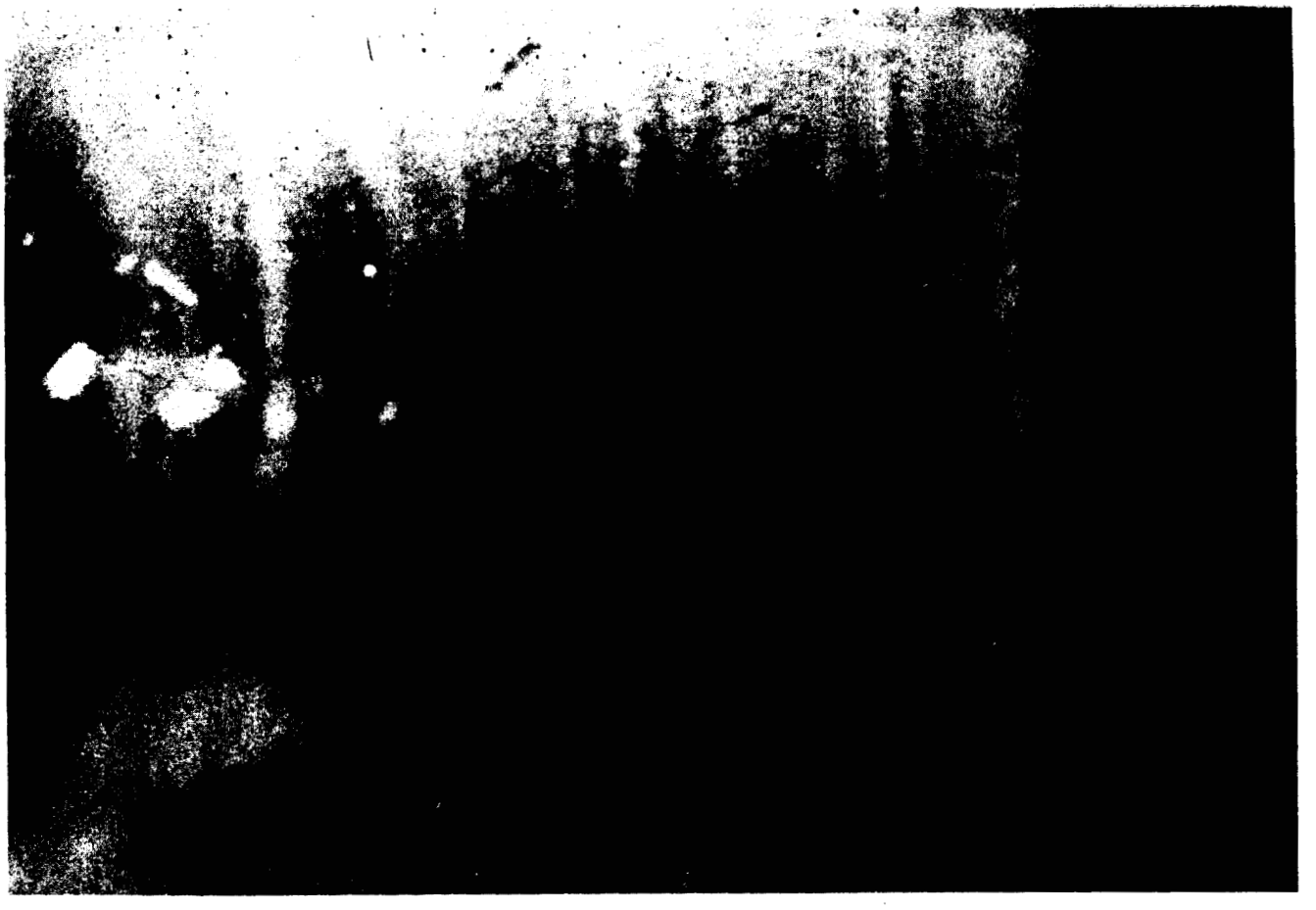

1119171

Figure 38

1119172

Figure 39

1119173

Figure 40

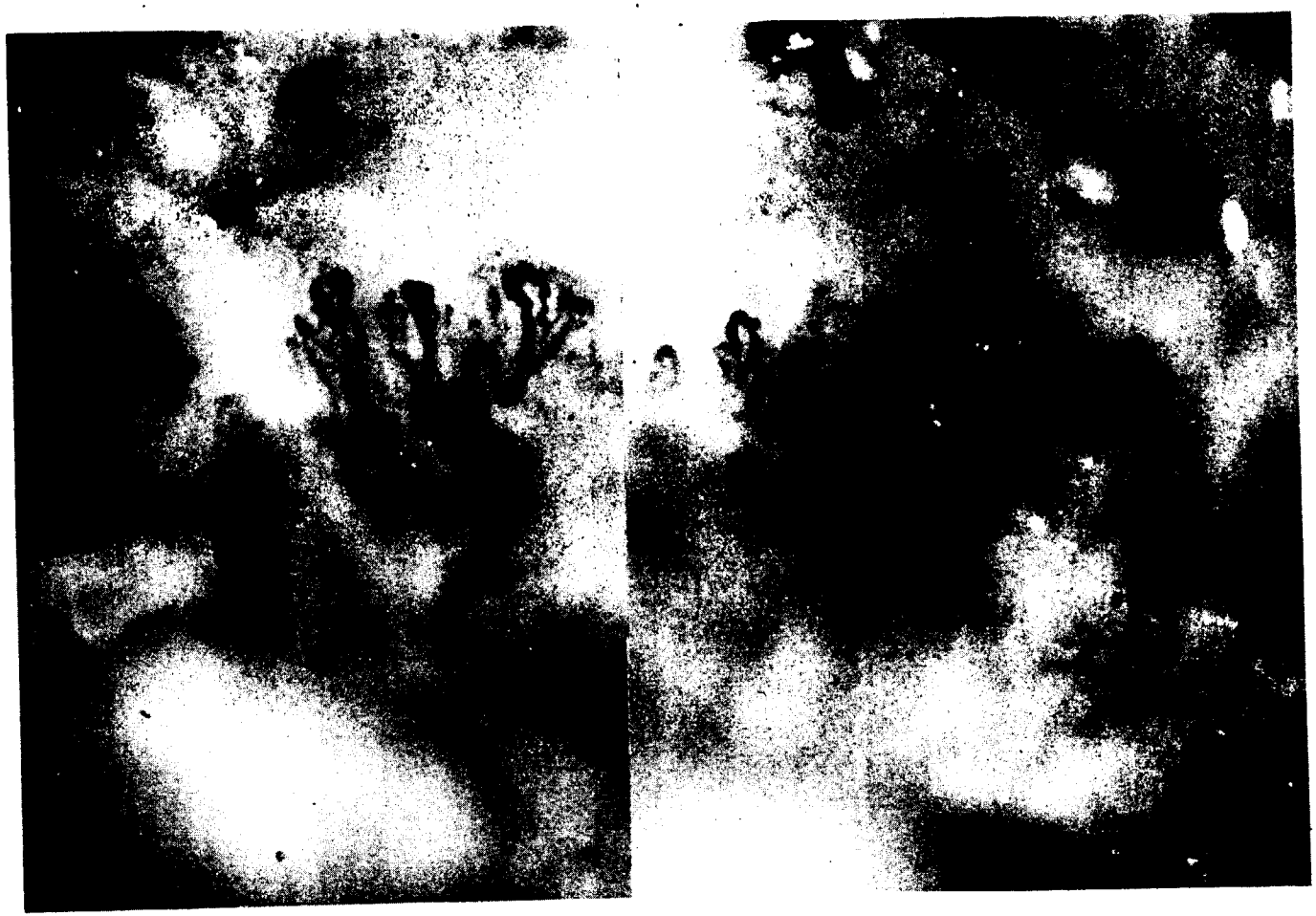

1119174

[redacted]

The photographs have been judged on a basis of 5 characteristics:

1. Increased number of visible loops.

2. Abnormal configurations of 50% or more loops.

3. Sacculations in 2 or more loops.

4. Widened venous limbs in 2 or more loops.

5. Visible subpapillary plexus.

Of the 53 individuals so studied 47 have changes in 1 or more categories. (Table V). Most of the deviations were of types 1 and 5. Type 1 changes were found in all exposure classifications. All 5 types of change were found in 3 individuals. One of these has clinical evidence of chronic radiation dermatitis with malignant changes. The other 2 are young men in highly exposed groups but with no clinical manifestations of skin damage.

Increased tortuosity and plexus visibility are not uncommon in individuals past middle age. A visible plexus may be found in young individuals with thin highly translucent skin. However, the occurrence of multiple deviations from normal in young subjects of exposed groups suggests the possibility that radiation even in very low doses has been a destructive influence on the vessels of the skin. Continued observations of these individuals and particularly of more heavily exposed individuals should establish this hypothesis.

1119175

[redacted]

Table V

Abnormal findings on 93 capillary photographs.

Exposure Group	Low		Medium		High	
No. of Subjects	31		14		48	
	No.	%	No.	%	No.	%
Abnormality						
None	16	52	8	58	23	49
Single	13	42	3	21	13	28
Multiple	2	6	3	21	12	25
Type of Change						
1	10	32	2	14	13	28
2	3	10	3	21	5	11
3	1	3	1	7	0	0
4	1	3	2	14	9	19
5	3	10	5	36	19	40

[redacted]

1119176

[redacted]

Bibliography

AM 1592 (CH): Report No. 1 - Dermatoglyphic Unit

Bordier, H.: Paris med. 1:109-114 1933
Cancer Consecutifs aux Radiodermites

Bordley, J., III, Grow, M. H., Sherman, W. B.: Bull. Johns Hopkins Hosp. 61:1 1938

Brauer, A.: Deutsche med. Wchnschr. 39:349-353 1911
Das Rontgen primarerythem

Browning, E.: Brit. J. Indust. Med. 1:170-175 1944
Medical Aspects of Radiations Used in Industry

Brown, G. E.: Arch. Int. Med. 35:56 1935
The Skin Capillaries in Raynaud's Disease

Brown, G. E. and Giffin, H. Z.: Am. J. M. Sc. 117:157 1926
Studies of the Vascular Changes in Cases of Polycythemia Vera

Brown, G. E. and Sheard, C.: J. Clin. Investigation 2:423 1926
Skin Capillaries in Polycythemia

Brunet de Rochebrune, W. F. H.: Dermatologica 87:1-11 1943
Effect of Small Doses of x-ray on Normal and Slightly Inflamed Skin of Rabbit

Bruns and Konig: (Cited by Carrier) 1920

Burrows, M. T., Jorstad, L. H., Ernst, E. C.
J. A. M. A. 87:86-90 1926
Cancer Vitamin Imbalance

Radiology 11:370 1928
Chemical and Biological Changes Induced by X-rays

Carrier, E. B.: Am. J. Physiol. 61:528-547
Studies on the Physiology of Capillaries

CH-2189: Clinton Report, Oct. 31, 1944

CS-2482: Information Meeting on Health, Dec. 12, 1944

Clunet, J.: J. Roentg. Soc. (London) 10:29-38 1914
(Cited by MacKee)

Codman, E. A.: Phila. Med. Record 9:438 1902
Accidental X-ray Burns

[redacted]

Cole, H. N.: J. A. M. A. 84:865-873 1925
Chronic Roentgen Ray Dermatoses in the Professional Man

Colwell, H. A.: Essay on the History of Electrotherapy 1922

Colwell, H. A. and Russ, S.: X-ray and Radium Injuries 1934
London, Oxford University Press

Correspondence File:

Friedell, H. to Stone, R. S. Sept. 6, 1943
Harvey, R. to Nickson, J. J. Nov. 13, 1943
Nickson, J. J. to Warren, S. Nov. 4, 1943
(MUC-HG-288)
Nickson, J. J. to Harvey, R. Dec. 18, 1943
(MUC-HG-292)

Crawford, J. H.: J. Clin. Investigation 3:381-374 1926

J. Clin. Investigation 4:307 1927
Studies on Human Capillaries

David, O.: Strahlentherapie 23:366 1926

David, O.: Zentralbl f. Inn. Med. 42:697-700 1921
Uber die Kapillarmikroskopie des Rontgenerythems

David, O. and Gabriel, G.: Strahlentherapie 15:125 1923
16:372 1923
17:192 1924

Davis, J. S.: Am. J. Roentgenol. 29:42-78 1933
Deep Roentgen Ray and Radium Burns

Desjardins, A. U. and Smith, F. L.: Surg. Clin. N. A. 4:479-493 1924
Radiodermatitis and Its Treatment

Deutsch, F.: J. Lab. & Clin. Med. 26:1723 1941
Capillary Studies in Raynaud's Disease

Dobrovolskaia-Zavadskaia, N. A.: Lyon chir. 21:397 1924
(Cited by Warren)

Dresser, R., Rude, J., and Cosman, B. J.: Radiology 34:13-16 1940

Duffy, J. A.: Am. J. Roentgenol. 42:540-544 1939
Irradiation Keratoses and Carcinoma

Duryee, A. W. and Wright, I. S.: Am. J. M. Sc. 185:664 1933
Study of Human Capillaries

Ellinger, F.: The Biologic Fundamentals of Radiation Therapy. 1941
Translated by R. Gross, New York, Nordeman Publishing Co., Inc.

1119178

Evans, T. C. and Kerr, H. D.: Am. J. Roentgenol. 50:629-635 1943
Radiosensitivity of the Skin

Fahr: (Cited by Pohle) 1925

Failla, G.: Am. J. Roentgenol. 16:154 1926
Effects of Combined and Radiation on Skin

Flaskamp, W.: Strahlentherapie (Sonderband) 12:1 1930

Frieben: (Cited by Colwell and Russ) 1902

Gassmar, A.: (Cited by Warren, MacKee, Wolbach) 1899 and 1904

Grant, R. T.: Heart 15:281 1930

Glasser, O.: Am. J. Roentgenol. 28:75-80 1932

Griffith, J. Q., Jr.: Am. J. M. Sc. 183:180 1932
Capillaries in Neurasthenic States

Grube, E. H.: Radiology 21:156 1933

Guyot, G.: Arch. f. Dermat. u. Syph. 97:211 1909

Halkin, H.: Arch. f. Dermat. u. Syph. 65:201-218 1903
Über den Einfluss der Becquerelstrahlen auf die Haut

Harris, M., Reddy, L. T. and Sheard, C.: Radiology 19:233-255 1932
Spectrophotometric Analysis of the Color of the Skin

Harvey, R. A.: A.M. 1892 (GH) 1944
Report of the Dermatoglyphic Unit

Hazen, H. H.: J.A.M.A. 97:1881-1885 1931
The Cause and Prevention of Radiodermatitis

Heimberger, H.: Ztschr. f. d. ges. exper. Med. 51:112 1926

Hermann, J. B. and Pack, G. T.: Am. J. Roentgenol. 51:504-507 1941

Hesse, O.: Fortschr. a. d. Geb. d. Röntgenstrahlen 17:82 1911

Heuter: (Cited by Lombard)

Hisinger-Jagerskiold, H.: Acta Med. Scandinav. 108-231 1923
Klinische Kapillarstudien

Jacobsi, W.: Die Hautkapillarmikroskopie 1929
Halle, Carl Marhold

Jehsmal, W. T. and Durham, R. M.: Ann. Int. Med. 18:164-176 1943
Incipient Thrombo-Angiitis Obliterans

1119179

Jolles, B.: Brit. J. Radiol. 14:110-112 1941
X-ray Skin Reactions and the Protective Role of Normal Tissues

Jorstad, L. H. and Lane, C. W.: Proc. Soc. Exper. Biol. & Med. [illegible]:886 1927
Skin Changes Produced by X-rays and Lipoid Solvents

Jurgensen, E.: Deutsches Arch. f. klin. med. 132:204 1920
Mikrokapillarbeobachtungen

Kohler, A.: Fortschr. a. d. Geb. d. Röntgenstrahlen. 6:193-194 1902-3
Rontgentherapie und Hautrotung

Krause, P.: Strahlentherapie 35:210-219 1930
Ein Beitrag zur Kenntnis des Rontgencarcinoms als Berufskankheit

Lange, K. and Boyd, L. J.: Arch. Int. Med. 74:175-184 1944

Lazarew, N. W. and Lazarewa, A.: Strahlentherapie 23:41-78 1926

Leader, S. D.: Am. J. Dis. Child. 44:403 1932
Capillary Microscopy in Children

Leddy, E. T. and Rigos, F. J.: Am. J. Roentgenol. 45:696-700 1941
Radiodermatitis Among Physicians

Lehmann, P.: Am. J. Roentgenol. 49:811-815 1943

Leppin, C.: Deutsche. med. Wchnschr. 22:454 1896

Lewis, T.: Heart 13:1 1926
Blood Flow through the Capillaries of Human Skin

Brit. M. J. 2:61-62 1926
Capillary Reactions

Lewis, T.: The Blood Vessels of the Skin and Their Responses
London: Shaw and Sons, Ltd. 1927

Lewis, T. and Love, W. S.: Heart 13:27 1926
Vascular Reactions of the Skin to Injury

Liberson, F.: Am. J. Roentgenol. 36:245-250 1936
The Use of the Lead Perforator and Reciprocal in Radiation Therapy

Lieber, G. D.: Strahlentherapie 20:93 1925
(Cited by Warren)

Linser, P.: Fortschr. a. d. Geb. d. Rontgenstrahlen. 8:97 1904-5

1119180

Lombard, W. P.: Am. J. Physiol. 29:335 — 1912
The Blood Pressure in Arterioles, Capillaries and Small Veins of Human Skin

MacKee, G. M.: X-ray and Radium in the Treatment of Diseases of the Skin
Philadelphia - Lea and Febiger

Magath, M. A.: Strahlentherapie 32:534 — 1929
(Cited by Warren)

Meltzer, H. and Kutz, E. H.: Strahlentherapie 62:406 — 1938
(Cited by Warren)

Meyer, H. Sonderbande zur Strahlentherapie 22 — 1937
Ehrenbuch der Rontgenologen und Radiologen aller Nationen

Meyer, W. H. and Mutscheller, A.: Radiology 28:215-222 — 1937
Heat as a Sensitizing Agent in Radiation Therapy

Miescher, G.: Strahlentherapie 16:334-371 — 1923
62:406 — 1938
Arch. f. Dermat. u. Syph. 148:540-592 — 1925

Mottram, J. C.: Nature (London) 132:317 — 1933
A reaction in the Skin following X-radiation

Müller, Otffried: Die Kapillaren im Gesunden und Kranken Tagen
Stuttgart, F. Enke — 1937

Nature: Editorial Note — Oct., 1896

Neumann: Berl. Klin. Woch. 57:826 — 1920
Kapillarstudien

Olkon, D. M.: J. Nerv. & Ment. Dis. 72:538 — 1930
Genuine Epilepsy. Studies of the Microscopic Changes in the Capillary System
Arch. Neurol. and Psychiat. 42:652-663 — 1939

Parrisius, W.: Deutsche Ztschr. f. Nervenh. 72:310:358 — 1921
Capillary Structure in Patients with Schizophrenia

Pardo-Costello, V.: Diseases of the Nails — 1941
Baltimore - Charles C. Thomas

Paskind, H. A. and Brown, M.: Arch. Neurol. & Phsychiat. 49:49-53 — 1943
Constitutional Differences in Patients with Epilsepsy

Pelzer, R. H. and Redisch, W.: Am. Heart J. 28:46-53 — 1944
Effect of Drugs on Surface Capillaries of the Rhesus Rhesus

Pendergrass, E. P., Hodes, P. J. and Griffith, J. Q.
Am. J. Roentgenol. 52:123 1944
Effect of Roentgen Rays on the Minute Vessels of the Skin in Man

Pfahler, G. E., Klauder, J. V. and Martin, J. L.
Am. J. Roentgenol. 16:150 1926
Combined Effects of Roentgen Rays and Ultra Violet Rays

Pohle, E. A.: Radiology 6:236-245 1926
8:185-194 1927
Studies of Roentgen Erythema of the Human Skin

Pohle, E. A. and Bunting, C. H.: Radiology 13:496-503 1929
15:647-659 1930
Skin Reactions Following Exposure to Roentgen Rays

Pohle, E. A. and Wright, C. S.: Radiology 14:351-359 1930
Studies of Roentgen Erythema of the Human Skin

Porter, C. A.: J. Med. Research 21:357-413 1909
X-ray Carcinoma and other Severe X-ray Lesions

Porter, C. A. and White, C. J.: Ann. Surg. 46:649-671 1907
Carcinomata Following Chromic X-ray Dermatitis

Powdermaker, F.: Arch. Neurol. & Psychiat. 22:1207 1929
Capillary Forms in Relation to Certain Problems in Development

Redisch, W. and Pelzer, R. H.: Am. Heart J. 26:598 1943
Capillary Studies in Migraine

Rowntree, C. W.: Brit. J. Radiol. 14:104 1909
(Cited by MacKee)
Arch. Middlessex Hosp. 15:182-205 1909
Study of X-ray Carcinoma

Saunders, T. S. and Montgomery, H.: J.A.M.A. 110:23-28 1938
Chromic Roentgen and Radium Dermatitis

Schugt, P. S.: München. med. Wchnschr. 69 (2): 1178-1180 1922

Schur, H.: Wien. klin. Wchnschr. 32:120[illegible] [illegible]
Mikroskopische Hautstudien am Lebenden

Scott, [illegible] Am. Array J. [illegible] 1897
(Cited by Glasser) X-ray Inuries

Secher, K.: Acta med. Scandinav. 106:295 1922
Klinische Kapillaruntersuchungen

Shaffer, B. J. : J. Invest. Dermat. 3:159-191 1940
Effect of Roentgen Rays on Skin Reactivity

Siedamgrotsky, K.: Am. J. Roentgenol. 14:485 1925

Stevens, L. G.: Brit. M. J. 1:998 1896
Early Skin Reactions from X-ray

Stone, R. S. and Robinson, J. M.: Am. J. Roentgenol. 44:601-609
A Comparison of Skin Reactions Produced by 200 KV and 1000 KV Radiations

Thies, A.: (Cited by MacKee) 1905

Unna, P. G.: Fortschr. a. d. Geb. d. Rontgenstrahlen 1904-5

Warren, Shields: Arch. Path. 34 1942
35 1943
Effects of Radiation on Normal Tissues

Weiss, E.: Deutsches Arch. f. klin. Med. 69:1 1916
Beobachtung und Mikrophotographische Darstellung der Hautkapillaren am lebenden Menschen

Weiss, S. and Frazier, W.: Am. Heart J. 5:511 1930
The Density of the Surface Capillary Bed of the Forearm

Wile, U. J., Cameron, O. J. and Eckstein, H. C.
Arch. f. Dermat. u. Syph. 32:69 1935

Witwer, E. R. and Leucutia, T.: Radiology 34:24-27 1940

Wolbach, S. B.: J. Med. Research 21:415-449 1909
Chronic X-ray Dermatitis and Early X-ray Carcinoma

Wright, I. S.: J.A.M.A. 101:439 1933
Clinical Value of Human Capillary Studies

Wright, I. S. and Duryee, A. W.: Arch. Int. Med. 52:545 1933
Human Capillaries in Health and Disease

Wyss: Beiträge z. klin. Chir. Tübingen 44 1906
(Cited by Wolbach)

Zondek, H., Michael, M. and Katz, A.
Am. J. M. Sc. 202:435 1941
The Capillaries in Myxedema

Zurhelle, E.: Dermat. Ztschr. 72:129-134 1935
The Influence of Radium Radiation on the Reactivity of the Skin

1119183