716236

Fertility Disturbances in Men and Women
S. KARGER — BASEL (Printed in Switzerland)
Separatum

Fertility Disturbances in Men and Women, pp. 48–64 (Karger, Basel 1971)

Embryology, Anatomy and Histology of the Male Sexual Organs

MAVIS J. ROWLEY and C. G. HELLER

Pacific Northwest Research Foundation, Seattle, Wash.

3001423

Embryology and Development

The testis originates as an indifferent primordial gonad capable of differentiating into an ovary or a testis.

Two areas of the primitive gonad are distinct, the cortex and the medulla. The cortex (of mesodermal origin) is a thickened ridge of celomic epithelium. The medulla (also of mesodermal origin) derives from the mesonephric blastema. These two components are separated by a narrow space of mesenchyme, the albuginia (fig. 1).

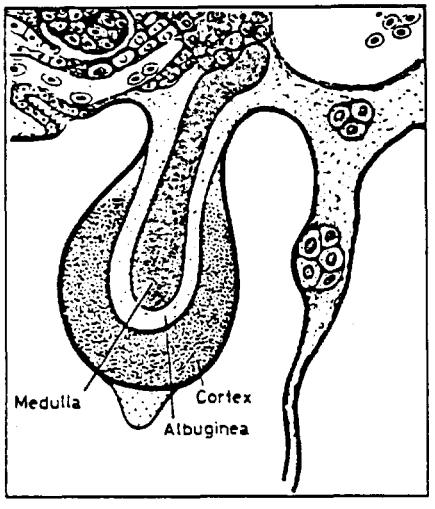

Fig. 1. Diagrammatic representation of basic arrangement of cortex and medulla before differentiation (fig. 4 in WITSCHI, 1951).

3001424

A third group of cells are the primordial germ cells which are scattered throughout the cortex and medullary cords. WITSCHI [1956] describes these cells as originating in the yolk-sac endoderm above the allantoic rudiment. They multiply from a small number (under 50) to over 1,000 and migrate by pseudopodial extensions through dense tissue to the areas occupied by the cortex and the medulla. Upon reaching their destination (5th embryonic week) they distribute themselves throughout the two layers.

During testicular differentiation the germ cells become the spermatogonia. The cortex and medulla form the seminiferous tubules and the mesonephros transforms into a network of ducts, the epididymus. Sexual differentiation is histologically apparent at the 7th embryological week. External sex differences are not seen until 8 to 10 embryonic weeks. The testes and the epididymes descend retroperitoneally through the inguinal canal and into the scrotal sac at 24 or more embryonic weeks. About this same time the interstitial cells or Leydig cells begin to show hypertrophy. They increase until the area occupied by Leydig cells is roughly equivalent to that occupied by the tubules. Regression of these cells occurs after birth because of the decrease in chorionic gonadotrophin and few Leydig cells can be found between birth and puberty.

The development of the testis after birth includes a long quiescent period followed by a time of differentiation and maturation as the gland responds to hormone changes. Before 10 years the tubules increase in length and tortuosity. Lumens also become apparent. No other significant changes take place. Between age 10 and final development changes are shown by steps. Mitotic activity is first observed. About one year later spermatogenesis has developed to secondary spermatocytes. Within another year spermatids are numerous and mature sperm are visible. Spermatogenesis then expands throughout all of the tubules until puberty is complete. This time can vary considerably with the individual.

The interstitial secretory cells (Leydig cells) develop more slowly than the germinal epithelium during puberty. The first indication of Leydig cell maturation is the presence of lipoid granules in fibroblast-like cells. They further develop in size and crystalloids of Reinke begin to appear. The final stages of puberty contain slightly larger numbers of Leydig cells than is found in the adult male.

Anatomy

The adult male genital system is composed of a sex gland or testis; excretory ducts, the epididymus, vas deferens and urethra; accessory glands;

3001425

and the external genitalia, the penis and scrotum (fig. 2). The testis is divided into two anatomical and functional areas, the seminiferous tubules which form spermatozoa, and the Leydig cells (interstitial area) which are hormonal in nature.

The testes or male sex glands are paired and suspended loosely by the spermatic cords in a divided bag of skin, muscle and subcutaneous tissue called the scrotum. The smooth muscle (dartos) and other fascia also extend between the testes to form the median septum. Each testis is oval about 1–½" in length and is covered by a fibrous, thick white covering called the

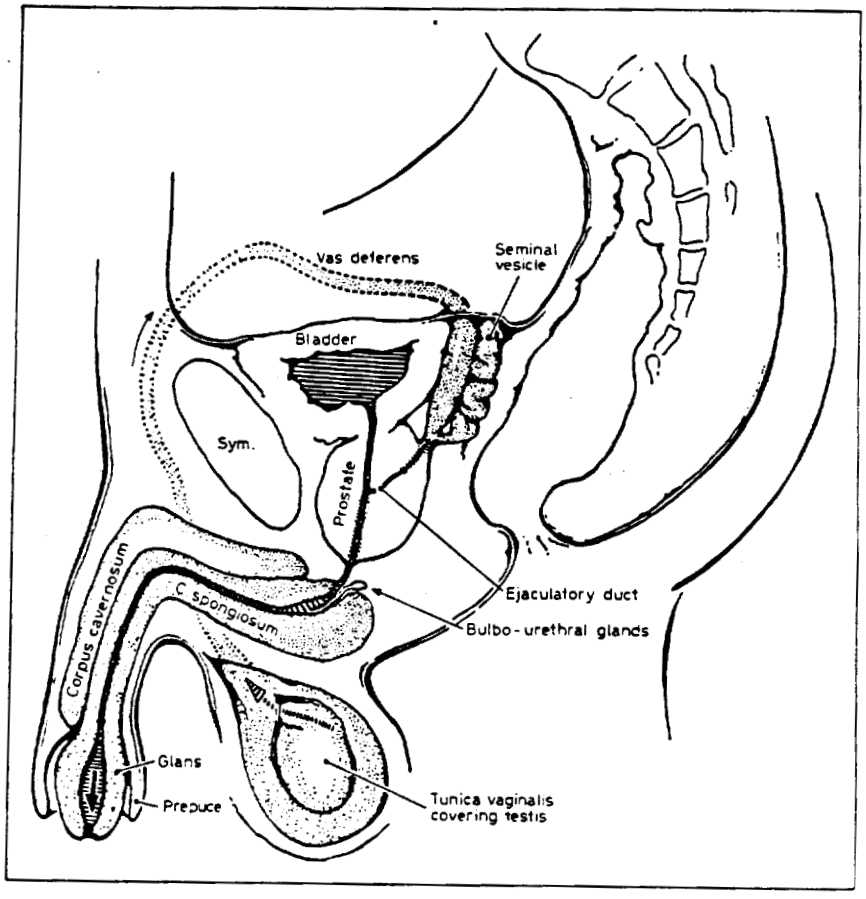

Fig. 2. Diagram of the male reproductive system (fig. 536 in HAM, 1957).

3001426

tunica albuginea (fig. 3 and 4). The tunica albuginea is in turn enclosed by a double layer of peritoneum called the tunica vaginalis. The tunica vaginalis is comprised of an outer parietal layer loosely covering the inside scrotum, and an inner visceral layer loosely covering the testis. This serous lining enables the testis to move freely within the scrotum. The inside of the testis is compartmented by fibrous septa into about 250 wedge shaped areas, the

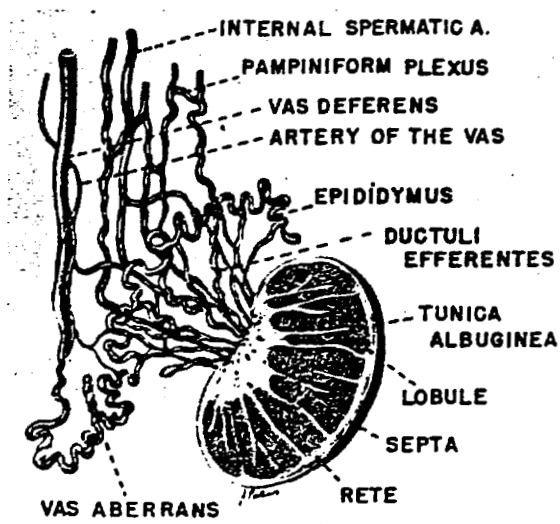

3

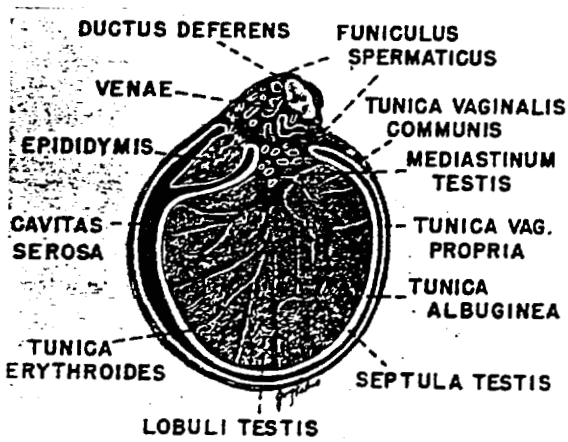

4

Fig. 3. Longitudinal section of testis with attached ductule system.
Fig. 4. Cross section of testis and membranes (fig. 451 in MAXIMOW and BLOOM, 1952).

3001427

lobuli testis. These areas peak at the mediastinum where the coiled seminiferous tubules in each lobule empty spermatozoa into the rete testis. From the rete testis the semen travels through the efferent ductules into the epididymus. The epididymus is a very convoluted long canal (4 to 6 m in length) with many blind outpouchings. This extreme length of tube provides surface area for reabsorption of fluid. It begins at the upper pole of the testis and folds upon itself along the posterior outer edge of the testis. The epididymus of each testis is connected by a ductus, or vas deferens (40–45 cm in length) to the urethra. The ductus deferens associates with blood vessels and nerves to form the spermatic cord as it traverses the abdominal wall and passes through the inguinal canal into the abdominal cavity. At the back of the urinary bladder, a blind outpouching known as the seminal vesicle, empties fluid into the duct. The ejaculatory duct, as it is now called, passes through the prostate and empties into the urethra. The urethra continues through the prostate and opens out through the penis as the common excretory duct of the urinary and genital systems.

Spermatogenesis

All cell descriptions to follow were made from Cleland's fixed tissues stained with iron hematoxylin and eosin unless other wise stated. All tissue handling was done as described by ROWLEY and HELLER [1966].

Three types of cells are involved in human spermatogenesis as described by HELLER and CLERMONT [1964]; spermatogonia, spermatocytes and spermatids (fig. 5).

The most immature cells, the Ad spermatogonia, are the stem cells. Two other spermatogonial cell types arise from Ad; the Ap and B spermatogonia. Spermatogonia undergo mitotic division only. *The A dark (Ad) spermatogonium* has an oval nucleus with fine dark chromatin which appears almost homogeneous. A large vacuole is often found within the nucleus. One or more nucleoli may be apparent along the nuclear membrane or within the vacuole. This cell adheres closely to the basement membrane. When fixed with Zenker-formol solution and using the periodic acid-Schiff technique, the cytoplasm is found to be filled with glycogen. Other fixatives and other stains show the cytoplasm as clear and unstained. The Ad divides mitotically to form two A pale spermatogonia. The first committed cell, *the A pale (Ap) spermatogonium* also lies along the basement membrane and contains a nucleus that is ovoid. The chromatin is fine and pale staining

3001428

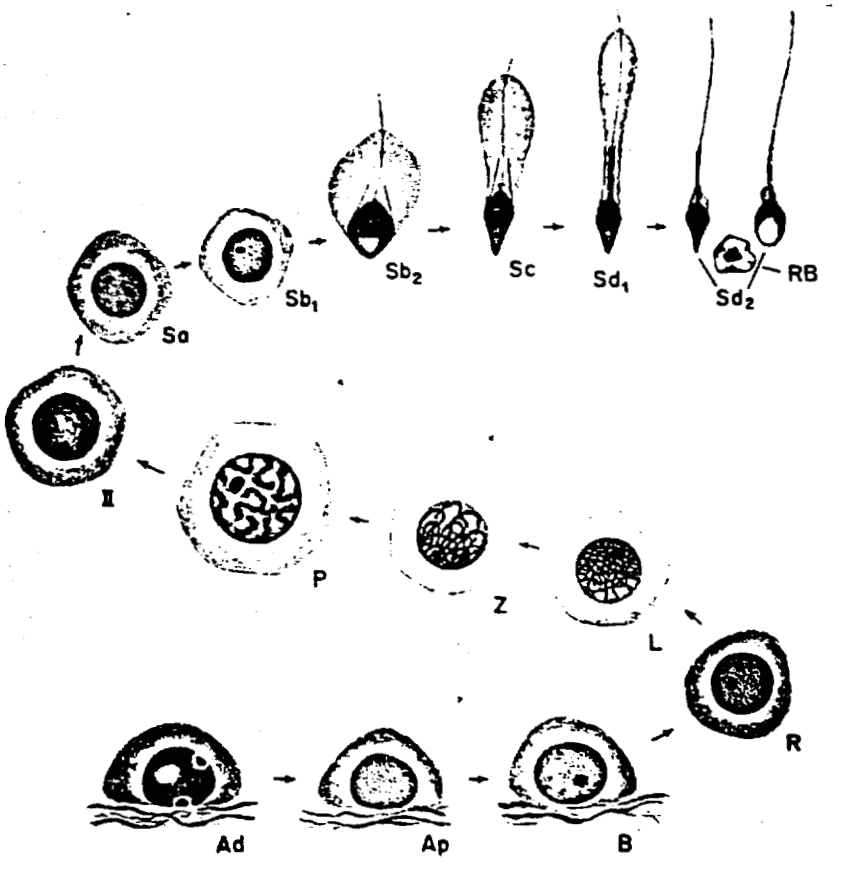

Fig. 5. Description of the steps of spermatogenesis in man. Ad, Ap and B are spermatogonia; R, L, Z and P are primary spermatocytes; II is a secondary spermatocyte; Sa, Sb, Sb_2, Sc and Sd, are spermatids; Sd_2 is a mature spermatozoa (front and side view); Rb is a residual body (fig. 1 in HELLER and CLERMONT, 1964).

with the appearance of ground glass. The nuclear membrane is thin and one or two nucleoli may be attached to it. The nucleoli do not have adhering chromatin. The cytoplasm of the Ap is generally free of glycogen. *The type B spermatogonium* arises from the mitotic division of the Ap. The nucleus is round in shape with a centrally located nucleolus that is covered by chromatin clumps. The nuclear membrane is coated with chromatin flakes. Other nuclear material maintains the same 'ground glass' appearance as the Ap.

3001429

The cytoplasm is clear with no glycogen. This cell is usually touching the basement membrane although it may occasionally be found above the Ad or Ap.

The second class of cells, the spermatocytes, mature from the mitotic division of the B spermatogonium. From this division to the formation of spermatids are the various steps of meiosis. The spermatocytes include all cells of meiosis from interphase to the second maturation division. *The resting or preleptotene (R) spermatocyte* contains the interphasic nucleus of the primary spermatocytes. It shows resemblance to the type B spermatogonium and the two cells can be confused. The R has a round nucleus and is usually not attached to the basement membrane. The dark chromatin is somewhat denser than the B and gives a more granular appearance to the nucleus. The nucleolus is centrally located and is covered with chromatin flakes. Large clumps of chromatin resembling small nucleoli may also be found either on the nuclear membrane or in the central part of the nucleus. It is at this time that DNA (desoxyribonucleic acid) is synthesized for the last time during spermatogenesis in preparation for the first maturation division.

The leptotene spermatocyte is the first cell of the meiotic prophase. It has a finely filamentous nucleus and is found above the basement membrane – usually above the spermatogonia. The *zygotene spermatocyte* has a distinctive nucleus with the long fine chromosome pairs forming a 'bouquet' arrangement. The nuclei of the *pachytene spermatocyte* enlarge in size and the chromosomes contract to become short and thick. During this change, which takes about 15 days, a large round nucleolus becomes apparent. The first maturation division follows diplotene and diakinesis to yield *secondary spermatocytes* (SS or II). These cells resemble immature spermatids except for their distinctly larger size. Multiple dark chromatin masses are apparent against a light homogenous chromatin background. They divide in the second maturation division to form spermatids. This large change from pachytene to spermatids through both maturation divisions occurs in about one day in man.

The third class of cells, the spermatids, arise from the maturation divisions of the spermatocytes. The spermatids are all cells which are haploid and are the daughter cells of the meiotic divisions. Spermiogenesis or the maturation of the spermatid includes the condensation and reshaping of the nucleus, the development of the acrosomic system, and the development of the sperm tail or flagellum. Six subdivisions of this maturation have been characterized by HELLER and CLERMONT [1964].

3001430

The *a spermatid (Sa)* has a round nucleus centrally located within the cytoplasm. The nucleus has pale granular chromatin containing a few dark flakes of chromatin. The acrosomic granule arises in the Golgi area of the spermatid and appears as an empty vesicle with all stains except periodic-acid Schiff. With this treatment of Zenker-formol fixed tissues the acrosome system stains bright pink. Because preservation of the acrosomic structures is more difficult in man than in rats or mice, nuclear morphology is used for cell differentiation. The b_1 *spermatid* (Sb_1) is characterized by a denser, smaller nucleus; slightly asymmetrical and still centrally located within the cytoplasm. The next cell is the b_2 *spermatid* (Sb_2). The nucleus is 'hatchet' shaped with the larger end touching the cell membrane. The nucleus is dark staining and appears homogeneous with further nuclear condensation occasionally apparent as small darker areas. The cytoplasm forms a caudal tube with a flagellum running down the middle from the nucleus toward the lumen. The *c spermatid (Sc)* has a greatly condensed nucleus with the tip pointing toward the basement membrane. The cytoplasm is long and nar-

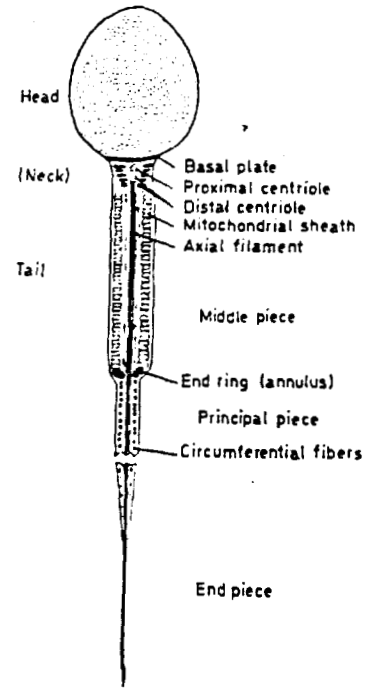

Fig. 6. Diagram of human spermatozoon (fig. 28–13 in GREEP, 1966).

3001431

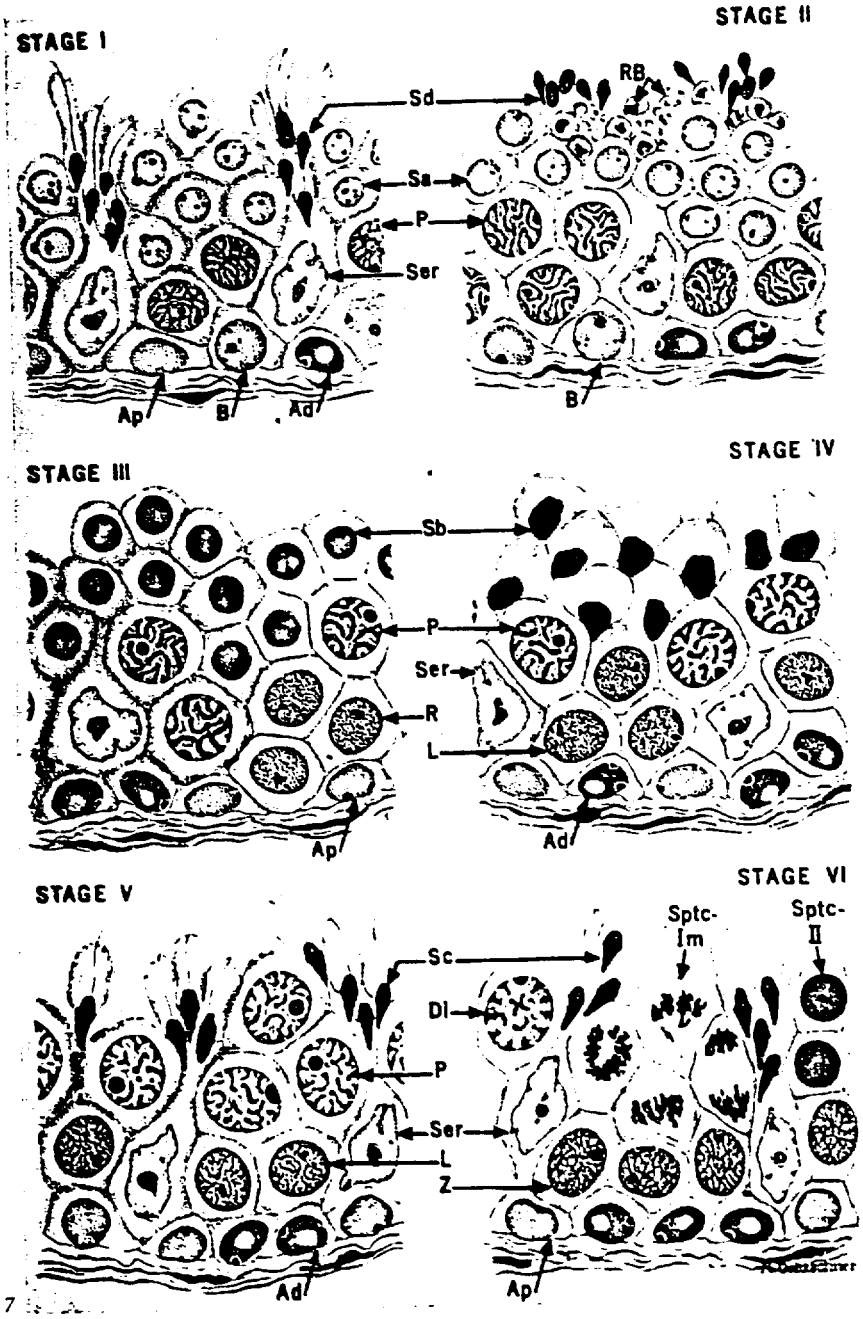
STAGE I
STAGE II
Sd
RB
Sa
P
Ser
Ap
B
Ad
B
STAGE III
STAGE IV
Sb
P
Ser
R
L
Ap
Ad
STAGE V
STAGE VI
Sptc-Im
Sptc-II
Sc
Dl
P
Ser
L
Z
Ad
Ap

7

3001432

row resembling the wake of a motorboat. The flagellum is visible and the caudal ring appears around the flagellum close to the nucleus. The step *d_1 spermatid (Sd_1)* nucleus flattens to resemble an arrowhead, the base of the head being thicker than the tip from a side view. The flagellum becomes more apparent and the cell is embedded deeply in Sertoli cell cytoplasm. The *d_2 spermatid (Sd_2)*, also called a spermatozoon, has a nucleus identical to the Sd_1. The cytoplasm is discarded and is now called a residual body (Rb) as it is left behind when the spermatozoon is released into the lumen. The flagellum is free of cytoplasm and the cell is usually perched on the lumenal surface of the tubule (fig. 6).

The Sertoli cell (Ser) (fig. 7) supports and possibly maintains the germinal epithelium nutritionally. The nucleus of the Sertoli cell is large and pale staining with one or more deep infoldings in the nuclear membrane. A large irregular distinctive nucleolus is centrally located within the nucleus. Other small chromatin flakes are apparent along the nuclear membrane. Cytoplasmic processes from the Sertoli cell extend between all of the cells of the germinal epithelium. The Sertoli cell membrane cannot be distinguished with the light microscope even when other cells of the tubule are absent.

Organization of the Germinal Epithelium

The organization of the seminiferous epithelium in man was thought to be chaotic until 1963. At that time CLERMONT outlined the cycle of the seminiferous epithelium in man. In 1964 HELLER and CLERMONT further typified the cycle and timed its duration.

Six cell associations (stages) have been delineated for the human testis. A cell association can be defined as germinal cells of four to six generations that remain associated with each other as they mature simultaneously (fig. 8). This maturation occurs from the basement membrane toward the lumen with the most primitive cells on the basement membrane and the most mature at the lumen. Figure 7 shows drawings representing the normal

---

Fig. 7. Diagrammatic representation of the cell associations with cells in natural position. Legend: Sa, Sd, Sd_2, Sb_1, Sb_2, Sc spermatids at various steps of spermiogenesis; P, pachytene spermatocyte; Ser, Sertoli cell; R, resting (or preleptotine) spermatocyte; L, leptotene spermatocyte; Di, diplotene spermatocyte; Ad, dark spermatogonia (stem cell); Ap, pale spermatogonia; B, spermatogonia; Sptc-Im, primary spermatocytes in division (fig. 2 in HELLER and CLERMONT, 1964).

3001433

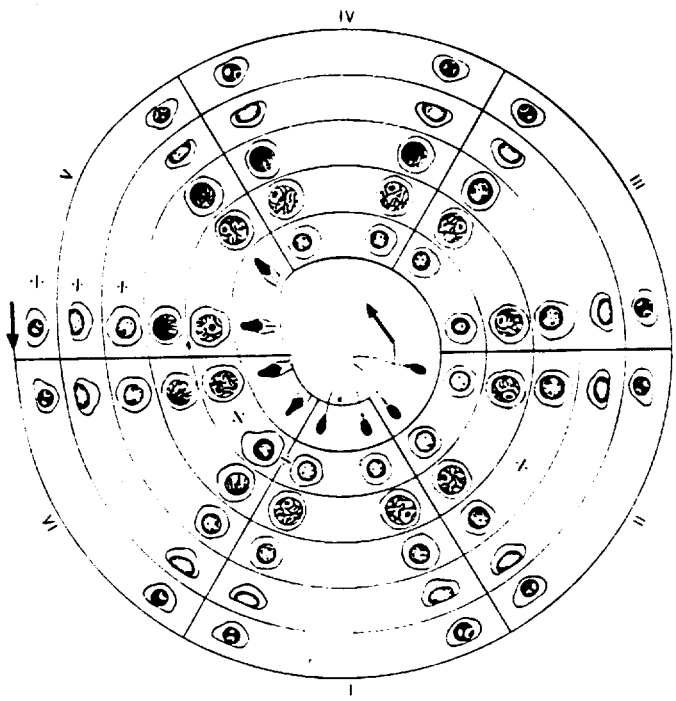

Fig. 8. 'Clock' arrangement of human spermatogenesis. One revolution takes 16 days.

cellular composition and arrangement in the six stages. The cells found in each cell association are as follows (fig. 9):

Cell association	I	Ad, Ap, B, P, Sa_1, Sd_1
	II	Ad, Ap, B, P, Sa_2, Sd_2
	III	Ad, Ap, R, P, Sb_1
	IV	Ad, Ap, L, P, Sb_2
	V	Ad, Ap, B, L, P, Sc_1
	VI	Ad, Ap, B, Z, P, SS, Sc_2

One cross section of a tubule may show more than one cell association (fig. 10A). This is unique to man. Other mammals usually show only one cell association per tubular cross section. This situation can cause confusion in the identification of cell associations as is shown in figure 10B and 10C. Further complications are introduced by the mixing of cell associations at their junctions. Despite these problems, cell associations are not difficult to identify and are plentiful in a biopsy from a normal individual (fig. 11).

3001434

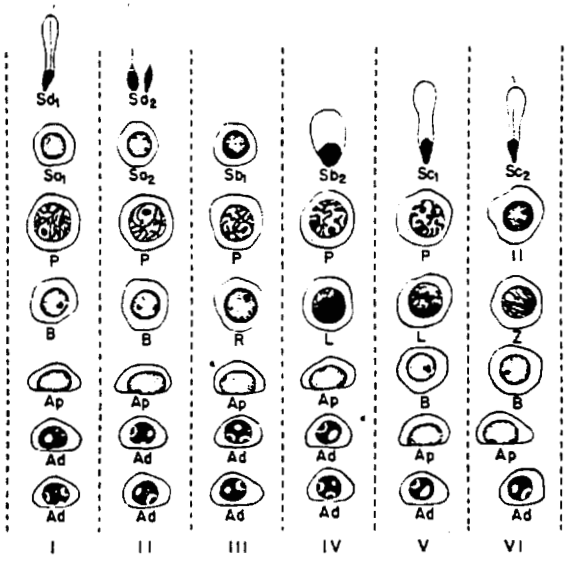

Fig. 9. Diagrammatic illustration of cells found in each cell association (fig. 1 in HELLER and CLERMONT, 1963).

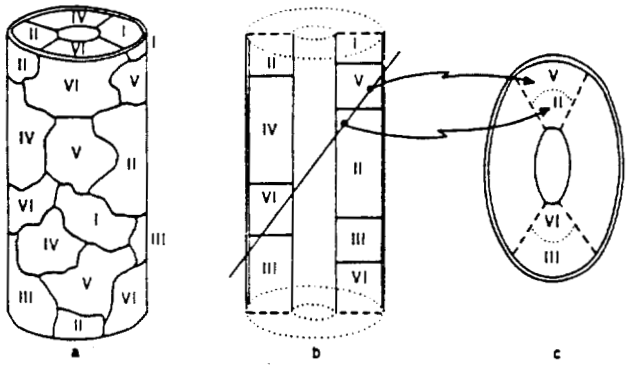

Fig. 10. Diagram of (A) whole tubule, (B) longitudinal section, and (C) oblique section, showing the possible distribution of cell associations (fig. 6 in HELLER and CLERMONT, 1964).

3001435

11 12

Fig. 11. Cell association IV. Ser, Sertoli cell; Ad, Adark spermatogonia; L, leptotene spermatocyte; P, pachytene spermatocyte; Sb spermatid. Basement membrane is at the bottom and lumen at the top (× 1000).
Fig. 12. Radioautograph of cell association III from a biopsy collected 3 h after thymidine-^{3}H injection. At 3 h after injection the resting spermatocyte (R) is labeled (× 850).

Timing of Spermatogenesis

The duration of one cycle, or the time it takes a cell to mature through all six cell associations once, has been determined by the use of tritiated thymidine. Tritiated thymidine was injected directly into the testis and biopsies taken at various times after injection. The biopsy slides were radioautographed and the most mature labeled cell was noted in each biopsy. The first biopsy was taken 1 h after injection and the most most mature labeled cell was found to be the resting or preleptotene spermatocyte in cell association III (fig. 12). The pachytene of cell association III was found to be the most advanced labeled cell exactly 16 days later (fig. 13). Another biopsy taken 32 days after injection showed the Sb_1 to be the most advanced labeled cell. Mature spermatids (Sd_2) in cell association II were labeled at 46 days after injection. The position of the arrows in figure 14 indicates the most advanced labeled cell at various times after injection. It was concluded

3001436



Fig. 13. Radioautograph of cell association III from a biopsy collected 16 days after thymidine-^{3}H injection. At 16 days after injection the pachytene spermatocyte (P) is labeled (× 850).

from these data that it takes 16 days for a resting spermatocyte in cell association III to go through the six cell associations (IV, V, VI, I, II, III) and become a mid-pachytene in cell association III. It also takes 16 days for a mid-pachytene in cell association III to go through the six cell associations to become an Sb_1 in cell association III. Therefore the duration of one cycle, or the time it takes a cell to mature through all six cell associations once, is about 16 days.

The duration of each cell association was determined by quantitation of the germinal epithelium [ROWLEY and HELLER, 1966]. It was assumed that the duration of each cell association is equal to the percentage of cells found in each cell association at any one time. The duration of each cell association is as follows: I–3.9; II–2.7; III–2.6; IV–2.0; V–3.7; VI–1.1 days. The total duration of one cycle being 16 days.

With this information, it was possible to determine the length of spermatogenesis. Assuming the division of the Ad into Ap as the beginning of spermatogenesis at mid cell association V, and ending with mature sperm in mid cell association II, spermatogenesis can be estimated as having a duration of 72.1 days. (Formula from HELLER and CLERMONT: $D^V/2 + D^{VI} + 4D$ cycles $+ D^I + D^{II}/2 =$ days; D being duration and Roman numerals indicating the cell associations.)

3001437

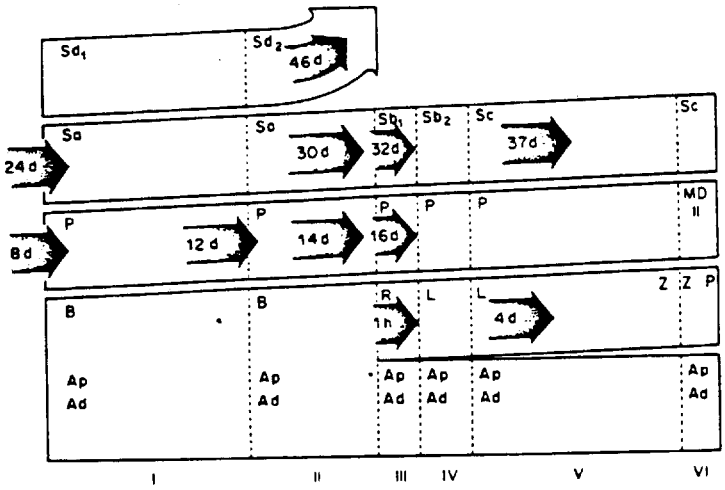

Fig. 14. Diagram illustrating the most advanced labeled cells at various time intervals after an intra-testicular injection of thymidine-^{3}H (fig. 11 in HELLER and CLERMONT, 1964).



15 16

Fig. 15. Radioautograph of seminal fluid collected 47 days following an intratesticular injection of thymidine-^{3}H. Arrow points out labeled spermatozoon (× 1150).
Fig. 16. Radioautograph of seminal fluid collected 58 days following an intratesticular injection of thymidine-^{3}H. Note labeled spermatozoa (× 1150).

3001438

Spermatozoa Travel Time

The time it takes for spermatozoa to travel from the tubule, through the epididymus, into the ejaculate has been determined from tritiated thymidine labeling. Seminal fluid was collected every three days after injection of tritiated thymidine. Labeled spermatozoa began appearing in the ejaculate 46–51 days (fig. 15) after injection; with the greatest number of labeled spermatozoa appearing 54–63 days after injection (fig. 16). Since we know that the most advanced cell labeled at injection (R) takes 46 days to become a mature spermatozoa, this indicates that the fastest sperm travel time is 1 to 5 days with the majority having a travel time of 8–17 days.

References

1. Albert, A.: The mammalian testis; in Young Sex and internal secretions, pp. 305–365 (Williams & Wilkins, Baltimore 1961).
2. Branca, A.: Les canalicules testiculaires et la spermatogénèse de l'homme. Arch. Zool. exp. gén. *62:* 53–252 (1924).
3. Charney, C. W.; Coulston, A. S. and Meranze, D. R.: Testicular developmental histology. Ann. N.Y. Acad. Sci. *55:* 543–742 (1952).
4. Clermont, Y.: The evolution of the acrosmic system of the spermatids in ram, bull and man. Anat. Rec. Suppl. *112:* 319 (1952).
5. Clermont, Y. and Leblond, C. P.: Spermiogenesis of man, monkey, ram and other mammals as shown by the periodic acid-Schiff technique. Amer. J. Anat. *96:* 229–253 (1955).
6. Clermont, Y.: The cycle of the seminiferous epithelium in man. Amer. J. Anat. *112:* 35–51 (1963).
7. Ebner, V. von: Arch. Mikr. Anat. *31:* 236–292 (1888).
8. Fawcett, D. W. and Burgos, M. H.: Observations on the cytomorphosis of the germinal and interstitial cells of the human testis. Ciba Found. Coll. Age *2:* 86 (1956).
9. Fawcett, D. W. and Burgos, M. H.: The fine structure of Sertoli cells in the human testis. Anat. Rec. *124:* 401–402 (1956).
10. Greep, R. O.: Histology; 2nd ed., pp. 701–742 (McGraw-Hill, New York 1966).
11. Ham, A. W.: Histology, pp. 803–828 (Lippincott, Philadelphia 1957).
12. Heller, C. G. and Clermont, Y.: Kinetics of the germinal epithelium in man; in Pincus Recent progress in hormone research, vol. 20, pp. 545–575 (Academic Press, New York 1964).
13. Heller, C. G. and Clermont, Y.: Spermatogenesis in man: An estimate of its duration. Science *140:* 184–185 (1963).
14. Heller, C. H.; Matson, L. J.; Moore, D. J. and Clermont, Y.: Rate of spermatogenesis in man determined by incorporating tritiated thymidine into testes. Proceedings of an International Symposium on the Effects of Ionizing Radiation, in the Reproductive System, pp. 263–267 (Pergamon Press, New York 1963).
15. Heller, C. G. and Nelson, W. O.: The testis-pituitary relationship in man. Recent Progress in Hormone Research, vol. 3, pp. 229–253 (Academic Press, New York 1948).

3001439

16. MANCINI, R. E.; NARBOITZ, R. and LAVIERI, J. C.: Origin and development of the germinative epithelium and Sertoli cells in the human testis: A cytological, cytochemical, and quantitative study. Anat. Rec. *136:* 477–489 (1960).
17. MANCINI, R. E.; VILAR, O.; LAVIERI, J. C.; ANDRADA, J. A. and HEINRICK, J. J.: Development of Leydig cells in the normal human testis: A cytological, cytochemical, and quantitative study. Amer. J. Anat. *112:* 203 (1963).
18. MAXIMOW, A. A. and BLOOM, W.: Histology; 6th ed., pp. 461–489 (Saunders, Philadelphia 1952).
19. ROOSEN-RUNGE, E. C.: The process of spermatogenesis in mammals. Biol. Rev. *37:* 343–377 (1962).
20. ROOSEN-RUNGE, E. C.: Kinetics of spermatogenesis in mammals. Ann. N.Y. Acad. Sci. *55:* 574–584 (1952).
21. ROWLEY, M. J. and HELLER, C. G.: The testicular biopsy: Surgical procedure, fixation and staining technics. Fert. Steril. *17:* 177–181 (1966).
22. ROWLEY, M. J. and HELLER, C. G.: The duration of each cell association (stages) of the human testis. Fed. Proc. (abstr.) *25:* 2 (1966).
23. SERTOLI, E.: Dell'esistenza di particolari cellule ramificati nei canalicoli seminiferi del testicule humano. Morgagni *7:* 31–39 (1865).
24. SNIFFEN, R. C.: Histology of the normal and abnormal testis at puberty. Ann. N.Y. Acad. Sci. *55:* 609–619 (1952).
25. SNIFFEN, R. C.: The testis. I. The normal testis. Arch. Path. *50:* 259–284 (1950).
26. WEISS, P. A. and HAMBURGER, V.: Analysis of development, p. 470 (Saunders, Philadelphia 1955).
27. WITSCHI, E.: Migration of the germ cells of human embryos from the yolk sac to the primitive gonadal folds. Contrib. Embryol. Carneg. Inst. *32:* 69–80 (1948).
28. WITSCHI, E.: Embryogenesis of the adrenal and the reproductive glands; in PINCUS Recent progress in hormone research, vol. 6, pp. 1–27 (Academic Press, New York 1951).
29. WITSCHI, E.: Development of vertebrates (Saunders, Philadelphia 1956).

3001440

REPOSITORY: DOE-RICHLAND
COLLECTION: GSS HUMAN TEST SUBJECTS STUDIES
PRISONER STUDY

BOX: 046264

FOLDER: 1780 - HELLER PACIFIC NW RES. FOUNDA.

ASSIGNED NUMBER: RLHTS 94-0028

300 14/40 A