DNA1.940708.002

AFRRI SR73-13
AUGUST 1973

AFRRI
SCIENTIFIC
REPORT

AFRRI SR73-13

# BASIC PRINCIPLES OF PANCREATIC SCANNING

J. S. Stevenson
C. D. Maynard

ARMED FORCES RADIOBIOLOGY RESEARCH INSTITUTE
Defense Nuclear Agency
Bethesda, Maryland

Approved for public release; distribution unlimited

AFRRI SR73-13
August 1973

# BASIC PRINCIPLES OF PANCREATIC SCANNING

J. S. STEVENSON
C. D. MAYNARD*

* Bowman Gray School of Medicine
Winston-Salem, North Carolina

JOE E. WEST
Lieutenant Colonel, USAF, VC
Chairman
Radiation Biology Department

MYRON I. VARON
Captain MC USN
Director

ARMED FORCES RADIOBIOLOGY RESEARCH INSTITUTE
Defense Nuclear Agency
Bethesda, Maryland

Approved for public release; distribution unlimited

ACKNOWLEDGMENT

The authors would like to thank the staff of the Department of Nuclear Medicine at the Bowman Gray School of Medicine for their contribution in enabling the review of the 80 patients presented in this paper. The authors would also like to thank R. Cowan for his assistance in interpretation and collaboration on the patients evaluated in this paper.

TABLE OF CONTENTS


| | Page |
|---|---|
| Foreword (Nontechnical summary) | iii |
| Abstract | iv |
| I. Introduction | 1 |
| II. Procedures | 1 |
| Normal pancreatic images | 2 |
| Abnormal pancreatic images | 2 |
| Interpretation | 4 |
| III. Results | 5 |
| IV. Discussion | 6 |
| V. Conclusion | 9 |
| References | 10 |

## LIST OF FIGURES


| | | Page |
|---|---|---|
| Figure 1. | Normal pancreatic scan | 3 |
| Figure 2. | Four commonly seen shapes of the normal pancreas | 3 |
| Figure 3. | Three patterns of abnormal images of the pancreas | 3 |
| Figure 4. | Four scintiphotograms depicting the value of obtaining a liver scan prior to doing the pancreatic imaging | 4 |
| Figure 5. | Identification that the apparent decreased uptake in the midportion of the pancreas represents aortic impression | 5 |


## LIST OF TABLES


| | | |
|---|---|---|
| Table I. | Patient Preparation | 2 |
| Table II. | Interpretation of Scans | 6 |
| Table III. | Results with Carcinoma of the Pancreas | 6 |
| Table IV. | Accuracy of Pancreatic Imaging | 8 |
| Table V. | Scintillation Scanning in Carcinoma of the Pancreas | 8 |
| Table VI. | Comparison of Radiographic Studies in Pancreatic Evaluation | 8 |

## FOREWORD
(Nontechnical summary)

The present techniques of pancreatic scanning have been severely criticized, and many physicians feel that it is not a worthwhile procedure. This study was done in an attempt to evaluate the true worth of pancreatic scanning, as routinely performed in the diagnosis of malignant disease, and is based upon a review of the literature as well as an evaluation of 80 patients who underwent pancreatic scanning at the North Carolina Baptist Hospital during a 12-month period. A brief description of the procedure for pancreatic scanning is presented, as well as a discussion of what represents normal and abnormal pancreatic images.

The evaluation revealed that a large percentage of false positive results occur with the presently utilized technique of pancreatic scanning. However, despite this, it is felt that pancreatic scanning has a place in the diagnostic armamentarium of evaluating pancreatic disease since pancreatic scanning is highly reliable in determining whether or not the pancreas is normal. It is only when a diagnostic interpretation beyond normal is made that pancreatic scanning is unreliable. Therefore, an abnormal interpretation must be followed by other diagnostic studies, such as radiographic angiography, to confirm whether the pancreas is or is not abnormal and to provide a clue as to the nature of the abnormality.

## ABSTRACT

The role and value of pancreatic scanning in the diagnosis of malignant disease were evaluated. It was found that, by employing the Anger scintillation camera and by utilizing dynamic visualization techniques, adequate pictures of the pancreas could be obtained. A literature review and evaluation of a total of 80 patients indicated that a large percentage of false positives were obtained using the present techniques of pancreatic scanning. However, it appeared that the interpretation of a normal pancreatic scan carried a high degree of reliability. It was therefore felt that with the present techniques of pancreatic scanning of those patients suspected of carcinoma of the pancreas a normal pancreatic scan carried a significant percentage of reliability for ruling out malignant disease of the pancreas. An abnormal scan carried a poor degree of reliability due to the high number of positives obtained with this procedure and, thus, other diagnostic procedures must be performed, such as angiography, for clarification.

## I. INTRODUCTION

Over 10 years ago, Blau and Bender[4] introduced pancreatic scanning and since that time there has been much controversy over the value of the procedure. Some physicians feel that it is worthwhile, while others feel it has not proven to be of significant clinical value.[9,16,18,21] The objective of this study was to evaluate pancreatic scanning prospectively in a series of patients to determine its proper place in the diagnostic armamentarium.

To evaluate the true worth of pancreatic scanning in relation to time, expense and radiation exposure to the patient against the information obtained, a literature review coupled with a study of 80 patients who had pancreatic scans at North Carolina Baptist Hospital was made. Since the Anger camera has been well established as a superior instrument for pancreatic scanning, scans performed prior to the acquisition of the camera were not included. The camera allows multiple images to be made during the hour following injection of the radiopharmaceutical, a beneficial feature for imaging this dynamic organ.[3,6,11,13]

## II. PROCEDURES

A majority of the 80 patients were prepared by placing them on a high-protein, low-fat, low-carbohydrate diet for 3 days prior to the study. These patients were then fasted overnight and were given a high-protein, low-fat, liquid meal 30 minutes prior to the injection of the radiopharmaceutical (Table I). Those patients who were not placed on specific diets had their procedures performed without fasting.

Following appropriate preparation, a single dose of 120 - 250 μCi of $^{75}$Se seleno-methionine was intravenously administered to each patient. Serial images were then

made every 10 minutes for 1 hour, with the detector angled 5 - 10 degrees toward the patient's head and 5 - 10 degrees toward the patient's midline. The center of the Anger scintillation camera's crystal was placed approximately 2 inches below the xiphoid process of the sternum and 2 inches to the left of midline, the usual landmark for locating the pancreas. If the initial image revealed that the position of the detector was unsatisfactory, then appropriate changes were made.[24, 25]

Table I. Patient Preparation

| |
|---|
| 1. Overnight or 12-hour fast |
| 2. Give oral test meal |
| 3. Wait about 30 minutes (to allow some gastrointestinal emptying) |
| 4. Inject 250 $\mu$Ci/kg of $^{75}$Se selenomethionine |
| 5. Begin scanning immediately with either a rectilinear scanner or Anger scintillation camera |

Normal pancreatic images. The normal uptake of $^{75}$Se selenomethionine in the pancreas is shown as a diffuse homogeneous pattern (Figure 1). Four commonly seen variations of the normal pancreas are (A) the classical shape, with head inferior to the transversely placed body and tail, (B) a club-shaped configuration, with the pancreas lying parallel to the liver, (C) a reversed S configuration, and (D) a horseshoe appearance[17] (Figure 2).

Abnormal pancreatic images. Three patterns of abnormal images of the pancreas are recognized: (A) focal defects, with part of the normal pancreas being visualized, (B) faint visualization of the pancreas due to a diffuse, poorly functioning organ, and (C) complete nonvisualization[5, 8, 15, 17, 20] (Figure 3).

Figure 1. Normal pancreatic scan

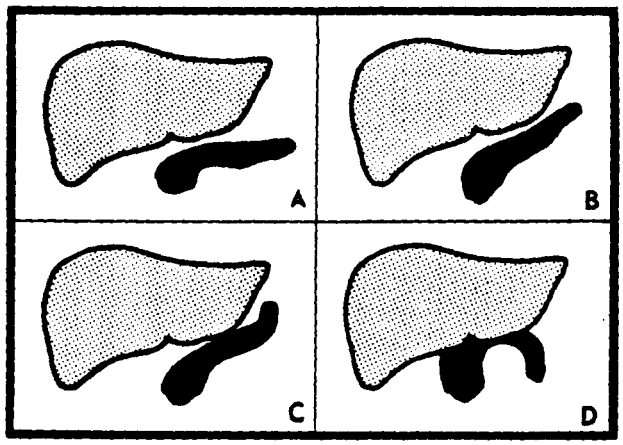


Figure 2. Four commonly seen shapes of the normal pancreas

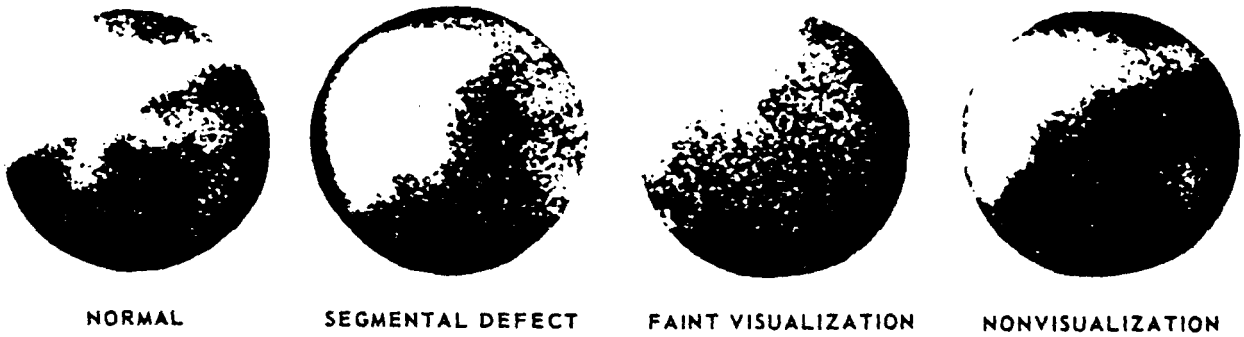


Figure 3. Three patterns of abnormal images of the pancreas

Interpretation. The most difficult aspect of interpreting images of the pancreas results from the fact that the pancreas may be positioned so close to the liver that separating the respective images is difficult. Although there are advocates for computer subtraction techniques, it is the general consensus that obtaining a liver scan (Figure 4) by using $^{99m}$Tc sulfur colloid prior to the pancreatic scan is a superior method of separating the pancreas from the liver.[14,19,23] In most instances, comparison of the separate liver scan with the pancreatic scan allows prompt identification of the pancreas. On several occasions, the finding of metastatic lesions in the liver has helped confirm the diagnosis of primary pancreatic tumors.[1,2,10]

An apparent decreased uptake of the radiopharmaceutical is normally seen in the midportion of the pancreatic scan and is attributed to the presence of the abdominal aorta. Although this can be a hindrance to properly interpreting pancreatic scans, once this pattern is seen a rapid dynamic study following the injection of a bolus of $^{99m}$Tc pertechnetate helps to confirm whether or not the defect is truly due to the aorta (Figure 5). It is of great importance, therefore, that the patient not be moved during the interval between the two studies, so that adequate correlation can be made.



Figure 4. Four scintiphotograms depicting the value of obtaining a liver scan prior to doing the pancreatic imaging. This study reveals nonvisualization of the pancreas, and those areas which show radiopharmaceutical concentration, other than the liver, represent renal uptake and not pancreatic uptake.

Figure 5. Identification that the apparent decreased uptake in the midportion of the pancreas represents aortic impression. The lower figures show radiopharmaceutical in the aorta obtained during a rapid dynamic study following the injection of a bolus of $^{99m}$Tc pertechnetate intravenously.

## III. RESULTS

Of the 80 patients evaluated, 96 percent (46/48) with normal interpretations were found not to have pancreatic disease (Table II). However, two patients who had later studies eventually were proven to have primary pancreatic carcinomas, a 4 percent false negative rate. Even in a retrospective examination of these latter patients, the original scans were felt to be within normal limits. Thirty-two of the scans were interpreted as abnormal, and 27 (84 percent) were proven by clinical diagnostic or pathological techniques to have pancreatic disease. Eighteen of these 27 patients wer found to have carcinoma of the pancreas, eight had pancreatitis, and one had a pseudocyst. Scans from five patients were interpreted as abnormal, and no evidence

of pancreatic disease could be established clinically or pathologically; a false positive rate of 16 percent.

Most pancreatic scanning is performed to evaluate patients in whom carcinoma of the pancreas is suspected. A diagnosis of this tumor was made in 20 of the 80 patients, 16 were confirmed by biopsy and four clinically. Of the 20 patients with confirmed pancreatic carcinoma, 18 had positive scans consistent with the diagnosis. Thus, in this series, pancreatic scanning had an accuracy rate of 90 percent and a false negative rate of 10 percent (Table III).

Table II. Interpretation of Scans

| Interpretation | | Pathological or clinical diagnosis | |
|---|---|---|---|
| | | correct | incorrect |
| Normal | 48 | 46 (96%) | 2 (4%) |
| Abnormal | 32 | 27 (84%) | 5 (16%) |
| Total | 80 | 73 (91%) | 7 (9%) |

Table III. Results with Carcinoma of the Pancreas

| | Abnormal | Normal |
|---|---|---|
| Total 20 | 18 (90%) | 2 (10%) |

## IV. DISCUSSION

Despite the controversy over the value of $^{75}$Se selenomethionine scanning of the pancreas,[7] the results of this study indicate that this technique has significant value in the diagnosis of pancreatic disease. It is readily appreciated that there are a number of variations in the normal configuration of the pancreas when this organ is adequately

visualized. Nevertheless, it appears that an interpretation of normal has a good degree of reliability. The false negative rate of 4 percent agrees favorably with that reported in the literature (Table IV). The main difficulty with pancreatic scanning is in the interpretation of what is an abnormal scan. The false positive rate of 16 percent agrees in general with that observed by others. This high false positive rate is responsible for the dissatisfaction of many physicians with this procedure. Most physicians readily accept the lack of an imaging procedure to identify 100 percent but find it difficult to accept a test which produces so many false positives.

In spite of all the attempts to improve pancreatic scanning, it appears that, for now at least, the presently employed procedure must be accepted as one which will give a high number of false positives. However, in the major clinical work-up of patients suspected of carcinoma of the pancreas, pancreatic imaging still appears to do a credible job of determining whether the pancreas is normal or not, particularly in the areas of the body and tail which are hard to evaluate with other routine radiographic procedures. In the North Carolina Baptist Hospital series, the scan was accurate in localizing 18 out of 20 carcinomas of the pancreas. The literature review revealed that 95 patients out of 103 were diagnosed as having carcinoma of the pancreas using pancreatic scanning, for a 92 percent accuracy (Table V). Indeed, it appears that, if the scan is positive in a patient suspected of carcinoma of the pancreas, substantiation must be obtained by other radiographic means such as angiography or by surgery (laparotomy).[16] However, if a normal scan is obtained in a patient who is a cancer suspect, the diagnosis of primary pancreatic neoplasm can be ruled out with high probability (Table VI).

Table IV. Accuracy of Pancreatic Imaging

| Investigators | False negative (percent) | False positive (percent) |
|---|---|---|
| Hatchette et al.[12] | 6 | 19 |
| Rodríguez-Antúnez[21] | 5 | 34 |
| Brown et al.[5] | [illegible] | 15 |
| Sodee[22] | 4 | 15 |
| Fink et al.[11] | 14 | 18 |
| Landman et al.[16] | 12 | 15 |
| Eaton et al.[9] | 9 | 19 |

Table V. Scintillation Scanning in Carcinoma of the Pancreas

| Investigators | Total | Scan interpretation | |
|---|---|---|---|
| | | Abnormal | Normal |
| Hatchette et al.[12] | 18 | 17 | 1 |
| Rodríguez-Antúnez[21] | 20 | 18 | 2 |
| Brown et al.[5] | 14 | 13 | 1 |
| Sodee[22] | 25 | 24 | 1 |
| Fink et al.[11] | 10 | 8 | 2 |
| Landman et al.[16] | 16 | 15 | 1 |
| Total | 103 | 95 (92%) | 8 (8%) |

Table VI. Comparison of Radiographic Studies in Pancreatic Evaluation

| | GI series (percent) | Hypotonic duodenography (percent) | Arteriography (percent) | Scanning (percent) |
|---|---|---|---|---|
| Correct | 57 | 78 | 55 | 72 |
| False + | 7 | 3 | 7 | 19 |
| False - | 36 | 19 | 38 | 9 |

## V. CONCLUSION

Pancreatic scanning with the Anger scintillation camera was evaluated in 80 patients. It was found that by utilization of the dynamic visualization technique, adequate pictures of the pancreas could be obtained. It appeared that a normal scan has a high degree of reliability. An abnormal scan, however, appears less accurate. It is therefore felt that in pancreatic scanning, especially in those patients suspected of carcinoma of the pancreas, a normal pancreatic scan carries a high reliability of ruling out the disease but an abnormal scan must be followed by other diagnostic procedures for clarification.

Until another diagnostic study is devised, or a new radiopharmaceutical for pancreatic scanning is found, pancreatic scanning will remain a simple screening procedure which has an ideal characteristic in its atraumatic technique of visualizing the organ. Until better radiopharmaceuticals and equipment for pancreatic imaging are available, pancreatic scanning must still be employed, fully understanding its true limitations.

## REFERENCES


1. Ben-Porath, M., Case, L. and Kaplan, E. The biological half-life of $^{75}$Se-selenomethionine in man. J. Nucl. Med. 9:168-169, 1968.

2. Blau, M. Biosynthesis of [$^{75}$Se]selenomethionine and [$^{75}$Se]selenocystine. Biochim. Biophys. Acta 49:389-390, 1961.

3. Blau, M. Pancreas scanning with Se$^{75}$-selenomethionine. In: Medical Radioisotope Scanning, Proceedings of the Symposium held in Athens, 20-24 April 1964, Vol. II, p. 275. Vienna, International Atomic Energy Agency, 1964.

4. Blau, M. and Bender, M. A. Se$^{75}$-selenomethionine for visualization of the pancreas by isotope scanning. Radiology 78:974, 1962.

5. Brown, P. W., Sircus, W., Smith, A. N., Donaldson, A. A., Dymock, I. W., Falconer, C. W. A. and Small, W. P. Scintillography in the diagnosis of pancreatic disease. Lancet 1:160-163, 1968.

6. Burdine, J. A. and Haynie, T. P. Diagnosis of pancreatic carcinoma by photoscanning. J. Am. Med. Assoc. 194:979-983, 1965.

7. Centi Colella, A. and Pigorini, F. Experiences in pancreas scanning using $^{75}$Se-selenomethionine. Brit. J. Radiol. 40:662-669, 1967.

8. Dupré, J. Regulation of the secretions of the pancreas. Ann. Rev. Med. 21:299-316, 1970.

9. Eaton, S. B., Fleischli, D. J., Pollard, J. J., Nebesar, R. A. and Potsaid, M. S. Comparison of current radiologic approaches to the diagnosis of pancreatic disease. New Engl. J. Med. 279:389-396, 1968.

10. Eaton, S. B., Potsaid, M. S., Lo, Hing Har and Beaulieu, E. A potential method for increasing pancreatic accumulation of $^{75}$Se selenomethionine. Radiology 89:933, 1967.

11. Fink, S., Ben-Porath, M., Jacobson, B., Clayton, G. D. and Kaplan, E. Current status of dual-channel pancreas scanning. J. Nucl. Med. 10:78-82, 1969.

12. Hatchette, J. B., Shuler, S. E. and Murison, P. J. Scintiphotos of the pancreas: analysis of 134 studies. J. Nucl. Med. 13:51-57, 1972.

13. Haynie, T. P., Svoboda, A. C. and Zuidema, G. D. Diagnosis of pancreatic disease by photoscanning. J. Nucl. Med. 5:90-94, 1964.

14. Kaplan, E., Ben-Porath, M., Fink, S., Clayton, G. D. and Jacobson, B. Elimination of liver interference from the selenomethionine pancreas scan. J. Nucl. Med. 7:807-816, 1966.

15. King, E. R., Sharpe, A., Grubb, W., Brock, J. S. and Greenberg, L. A study of the morphology of the normal pancreas using $Se^{75}$ methionine photoscanning. Am. J. Roentgen. 96:657-663, 1966.

16. Landman, S., Polcyn, R. E. and Gottschalk, A. Pancreas imaging -- is it worth it? Radiology 100:631-636, 1971.

17. Melmed, R. N., Agnew, J. E. and Boucher, I. A. D. The normal and abnormal pancreatic scan. Quart. J. Med. 37:607-624, 1968.

18. Miale, A. Pancreas scanning: myth or reality. In: Hematopoietic and Gastrointestinal Investigations with Radionuclides, Gilson, A. J., Smoak, W. M., III and Weinstein, M. B., editors. Springfield, Illinois, Charles C. Thomas, 1972.

19. Overton, T. R., Heslip, P. G., Barrow, P. A. and Jelinek, J. Dual-radioisotope techniques and digital image - subtraction methods in pancreas visualization. J. Nucl. Med. 12:493-498, 1971.

20. Powell, M. R., Miale, A., Jr. and Anger, H. O. Pancreas visualization with the scintillation camera. J. Nucl. Med. 7:372 (Abstract), 1966.

21. Rodríguez-Antúnez, A. Photoscanning of the pancreas. J. Am. Med. Assoc. 205: 347-348, 1968.

22. Sodee, D. B. Pancreatic scanning. Radiology 87:641-645, 1966.

23. Staab, E. V., Babb, O. A., Klatte, E. C. and Brill, A. B. Pancreatic radionuclide imaging using electronic subtraction technique. Radiology 99:633-640, 1971.

24. Tabern, D. L., Kearney, J. and Dolbow, A. The use of intravenous amino acids in the visualization of the pancreas with seleno 75 methionine. J. Nucl. Med. 6:762-766, 1965.

25. Wheeler, J. E., Lukens, F. D. W. and György, P. Studies on the localization of tagged methionine within the pancreas. Proc. Soc. Exptl. Biol. Med. 70:187-189, 1949.

DOCUMENT CONTROL DATA - R & D

(Security classification of title, body of abstract and indexing annotation must be entered when the overall report is classified)

1. ORIGINATING ACTIVITY (Corporate author)
Armed Forces Radiobiology Research Institute
Defense Nuclear Agency
Bethesda, Maryland 20014

2a. REPORT SECURITY CLASSIFICATION
UNCLASSIFIED

2b. GROUP
N/A

3. REPORT TITLE

BASIC PRINCIPLES OF PANCREATIC SCANNING

4. DESCRIPTIVE NOTES (Type of report and inclusive dates)

5. AUTHOR(S) (First name, middle initial, last name)

J. S. Stevenson and C. D. Maynard

6. REPORT DATE
August 1973

7a. TOTAL NO. OF PAGES
16

7b. NO. OF REFS
25

8a. CONTRACT OR GRANT NO.

b. PROJECT NO. NWED QAXM

c. Task and Subtask C 906

d. Work Unit 06

9a. ORIGINATOR'S REPORT NUMBER(S)

AFRRI SR73-13

9b. OTHER REPORT NO(S) (Any other numbers that may be assigned this report)

10. DISTRIBUTION STATEMENT

Approved for public release; distribution unlimited

11. SUPPLEMENTARY NOTES

12. SPONSORING MILITARY ACTIVITY
Director
Defense Nuclear Agency
Washington, D. C. 20305

13. ABSTRACT

The role and value of pancreatic scanning in the diagnosis of malignant disease were evaluated. It was found that, by employing the Anger scintillation camera and by utilizing dynamic visualization techniques, adequate pictures of the pancreas could be obtained. A literature review and evaluation of a total of 80 patients indicated that a large percentage of false positives were obtained using the present techniques of pancreatic scanning. However, it appeared that the interpretation of a normal pancreatic scan carried a high degree of reliability. It was therefore felt that with the present techniques of pancreatic scanning of those patients suspected of carcinoma of the pancreas a normal pancreatic scan carried a significant percentage of reliability for ruling out malignant disease of the pancreas. An abnormal scan carried a poor degree of reliability due to the high number of positives obtained with this procedure and, thus, other diagnostic procedures must be performed, such as angiography, for clarification.

DD FORM 1 NOV 65 1473

UNCLASSIFIED
Security Classification