725145

P

STUDIES OF RADIOGALLIUM AS A DIAGNOSTIC AGENT IN BONE TUMORS

COMDR. W. C. MULRY, MC, USN
and
COMDR. H. C. DUDLEY, MSC, USN
Bethesda, Md.

Reprinted from
THE JOURNAL OF LABORATORY AND CLINICAL MEDICINE
St. Louis

Vol. 37, No. 2, Pages 239-252, February, 1951

(Printed in the U. S. A.)

REPOSITORY Records Holding Area Bldg. 49
COLLECTION Protocols - Clinical
BOX No. 4
FOLDER Human Protocols 1950-1963

1176174

STUDIES OF RADIOGALLIUM AS A DIAGNOSTIC AGENT IN BONE TUMORS

COMDR. W. C. MULRY, MC, USN,* AND COMDR. H. C. DUDLEY, MSC, USN†
BETHESDA, MD.

INTRODUCTION

THIS is a report of the first eighteen human subjects in whom radiogallium tracer studies have been made at this medical center.

Laboratory studies of the pharmacology and biochemistry of gallium have shown that this element is selectively localized in osteoid tissues[1, 2] and particularly in centers of osteogenesis.[3, 4]

The purpose of the present study was (a) to develop methods for the localization of Ga^{72} in the human body, by an externally positioned Geiger tube, and (b) to determine the degree of localization of Ga^{72} in patients with neoplastic lesions involving bone. The present study reports results of the study of eighteen cases of primary and secondary bone malignancies.

Gallium is a metallic element having many of the chemical properties of aluminum. The radioactive isotope (Ga^{72}) is a β and γ emitter, of energetic spectrum (max. β 3.1 mev, γ 2.5 mev). This isotope is contained in carrier gallium (0.1 mc. per milligram Ga) and administered as the citrate.[5]

LABORATORY METHODS

Counting Techniques.—There are many factors which must be considered when attempting to localize in the human body, by external counting methods, a particular organ or structure which contains a quantity of some radioactive substance. The principal factors are (1) volume of tissue containing a high concentration of the isotope, (2) differential distribution of the isotope between the localized area and the adjacent tissues, (3) depth of center of mass, i.e., distance to counter tube, (4) degree of collimation obtainable with jacketed Geiger tubes, (5) the nature of the radiation and its absorption characteristics in tissues, and (6) absorption characteristics between counter and source.

In order to study the effectiveness of (I^{131}) radioiodine diagnostic and therapeutic procedures, various end-window Geiger tubes were fitted with lead shells. This was an attempt to produce a collimated beam of gamma radiation which would more closely define areas of active thyroid hyperplasia. Considerable success was obtained in these studies.[6] It was found that the same general type of jacket was satisfactory for such studies of Ga^{72}, but a considerably larger and denser shield was needed in order to produce a sharply collimated beam from the skin surface of a patient receiving Ga^{72}. In Fig. 1 is presented a sketch of the Geiger tube and the surrounding jacket (weight 7 kilograms) as used in these studies.

In Fig. 2 are presented graphically results of a study of the collimating ability of the tube and jacket described in Fig. 1. This study was made using a 2 cm. planchet of Ga^{72}. The "theoretical cutoff zone" is the geometric projection of lines passing through the edges of the tube window and the shield port. This zone delineates the area beneath the tube which emits radiation directly (disregarding scattered radiation) into the tube.

The opinions or conclusions contained in this report are those of the authors. They are not to be construed as necessarily reflecting the views or endorsement of the Navy Department.

Received for publication, July 28, 1950.

*Radioisotope Laboratory, Naval Hospital.
†Biochemistry Division, Naval Medical Research Institute.

1176175

The "line of 50 per cent cutoff" is the *observed* lateral distance at which the counting rate is reduced to one-half the maximum observed if the sample was placed opposite the shield port.

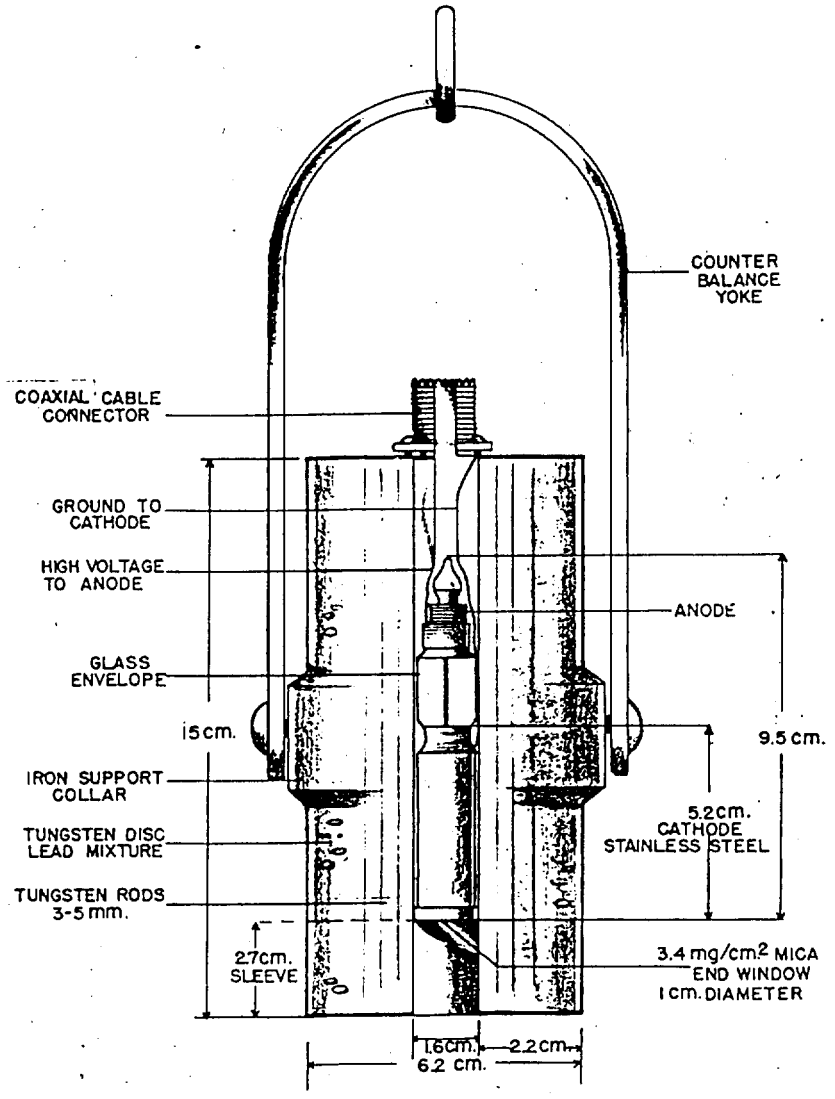

1 cm. GEIGER MUELLER TUBE - DIRECTIONAL SHIELD ASSEMBLY.

Fig. 1.

The lines denoting the relative counts per minute indicate the counts observed as the target was moved laterally in front of the tube at some definite distance (tube to target distance) i.e., 40, 90, 120, or 150 millimeters.

Study of Ga[72] *in Phantom.*—The purpose of this phase of the investigation was to study the methods which were being used clinically and to evaluate their significance under controlled laboratory conditions.

1176176

A simulated human torso was made by filling a wooden box (60 cm. by 52 cm. by 24 cm.) with hulled rice (sp. gr. 0.825). To the rice was added, by scattering through the mass, a water solution of Ga^{72}. The rice was then thoroughly mixed. A concentration of 0.07 to 0.08 μc Ga^{72} per liter of rice gave a count of 1,200 to 1,500 counts per minute at a distance of 2 cm. from the surface. This approximates what had been obtained in surface counts of human beings who had been administered 300 to 400 μc Ga^{72} intravenously. The jacketed Geiger tube shown in Fig. 1 was used throughout these phantom studies.

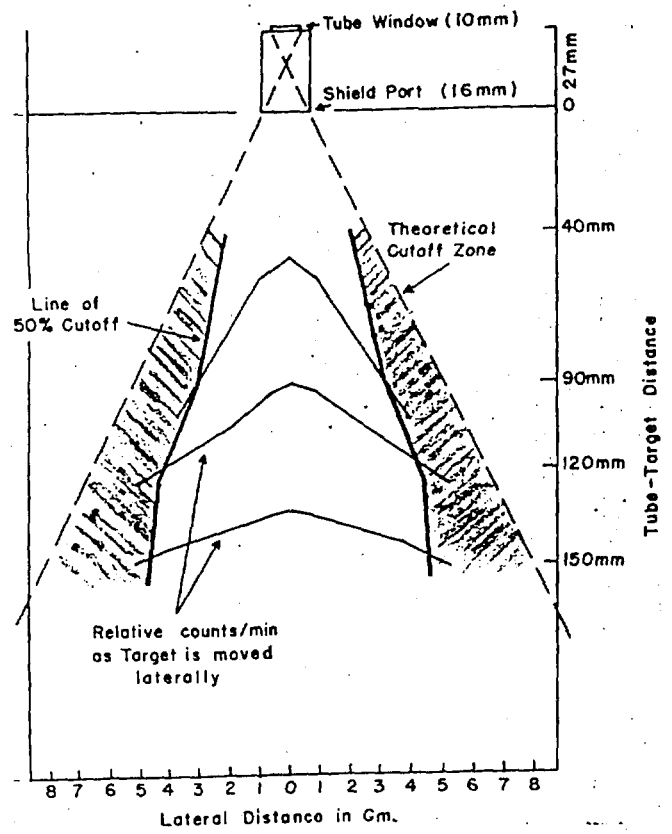

Fig. 2.

In order to give reproducible geometry, a steel rail arrangement was made so that the placement of the Geiger tube relative to the surface and center of the mass of the "phantom" was constant. A series of volumetric flasks from 10 c.c. to 2,000 c.c. were filled with a water solution having a concentration of Ga^{72} (microcuries per liter of water) from two to forty times the concentration of Ga^{72} (microcuries per liter of rice) contained in the phantom. These flasks were prepared in order to simulate organs or structures of different sizes and having different concentrations of Ga^{72}.

In making a study of the effect of the counts obtainable at the surface of the rice, the Geiger tube was successively placed at each of the five counting points (Fig. 3). When a satisfactory base line had been obtained, one of the flasks was buried in the rice beneath the center point. In each series the center of the mass of the flasks was located at some predetermined distance below the surface of the rice (4 or 9 cm.). Counts were taken at

1176177

all five points across the surface of the rice after burying the flasks. In Fig. 3 is shown a graphic representation of the counts obtainable with various flasks containing Ga^{72} concentrations five and twenty times the concentration of Ga^{72} in the body of the phantom. These findings are typical of the results obtained at other concentrations.

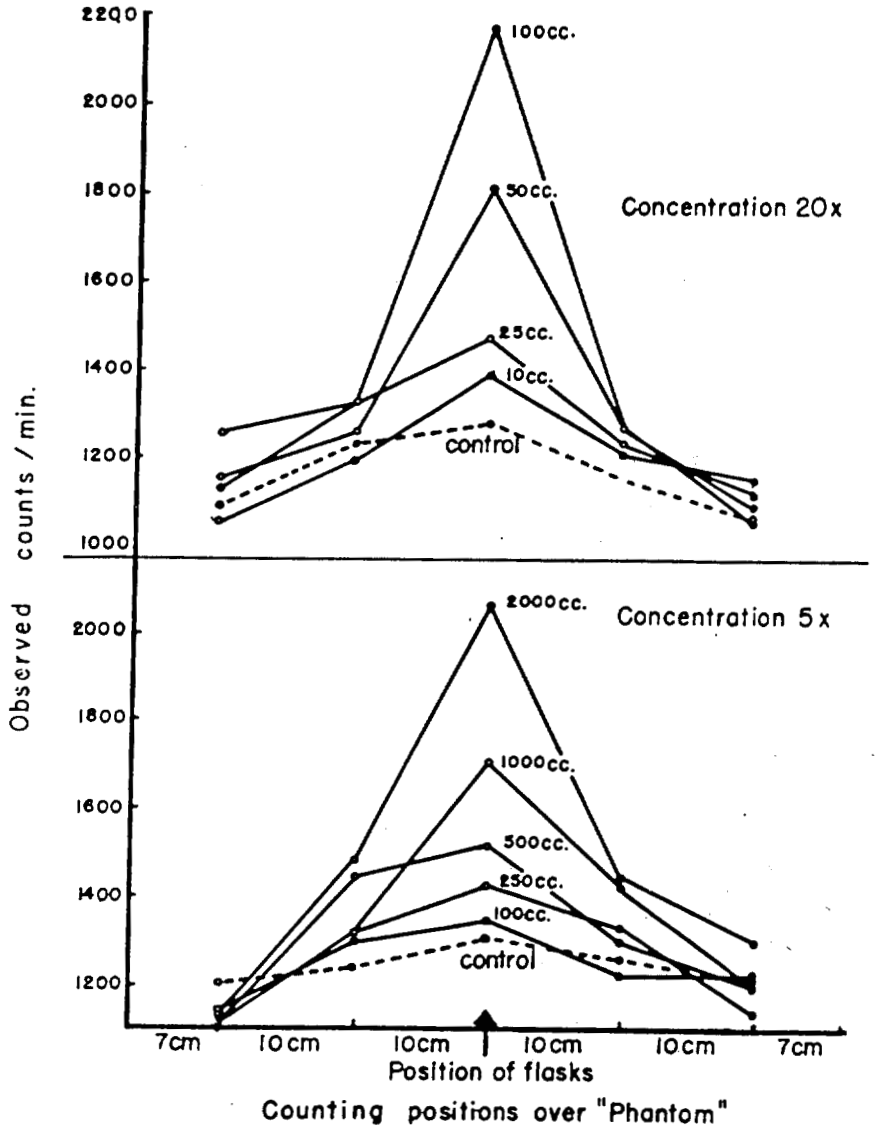

Fig. 3.—Influence of the size of the flask, the concentration of Ga^{72} therein, and position of the Geiger-Müller tube on the observed counting rate.

In Fig. 4 is shown graphically a résumé of the results of this phase of the study. In this figure is plotted the relative percentages of counts obtainable at the center point of the phantom plotted against the diameter of the flask containing various concentrations of Ga^{72}. These findings indicate the counts obtainable at the surface are a function of

1176178

both the size of the buried flask and the concentration of the Ga^{72} contained therein. There are factors in these findings which limit their usefulness, particularly in the smaller-sized flasks or at the lower concentrations of Ga^{72}. When the counts over a buried flask do not exceed the background by more than 5 per cent, the significance of the result is questionable.

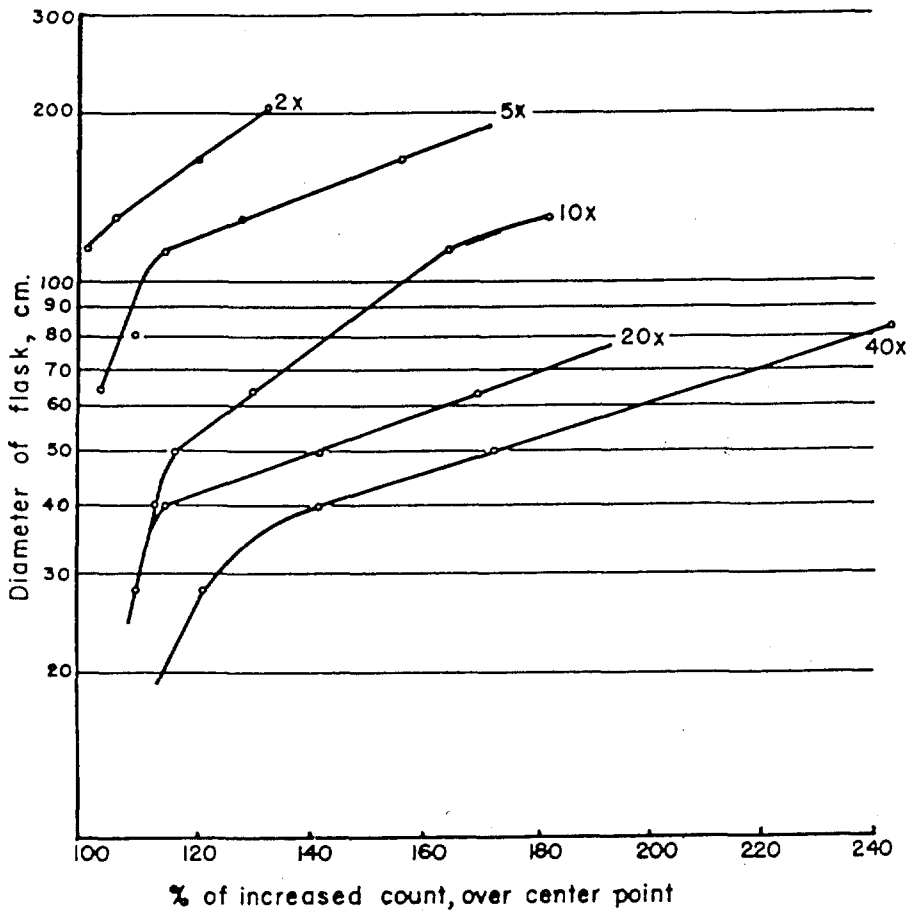

Fig. 4.—Relationship of the diameter of the flask, the concentration of the Ga^{72} therein, and the increased count obtained over these flasks in the phantom.

To approximate the concentration or degree of localization in diagnostic studies with Ga^{72}, the findings shown in Fig. 4 are of significant aid. The diameter and depth of the lesion can be estimated from x-ray films. By external counts over the body, using the Geiger tube described in Fig. 1, a series of counts will be obtained. If one determines the percentage of count over the lesion to be, for example, 115 per cent of the count over adjacent tissues and the diameter of the lesion to be 8 cm., at a depth of 4 cm., then, as an approximation, the concentration of Ga^{72} in the lesion is five times that in the surrounding tissue. If the diameter of the lesion is 2 cm., at a depth of 9 cm., and the observed count is 125 per cent of the general average, the concentration of Ga^{72} in the lesion approximates forty times the general body concentration. Within limits the curves shown in Fig. 4 may be used to approximate the concentration in various lesions in human beings, in cases of malignancies.

1176179

It is realized this indirect method of determining concentration of a chemical substance in a specific location in the human body is only an approximation. It is, however, based on sound physical principles and seems to be the only means, short of biopsy, of estimating the concentration of this isotope in osteoid structures. More significantly for diagnostic procedures, these laboratory findings indicate that an increase of 10 to 20 per cent of counts over a localized area is evidence of marked localization of Ga^{72} in some structure beneath the surface.

CLINICAL METHODS

Selection of Cases.—The patients were primarily selected from those with proved malignancies, having x-ray evidence of new bone production, or metastatic lesions in bone. Later it was found that patients having localizing bone symptoms but without x-ray confirmation were also suitable for these diagnostic studies.

Administration of Ga^{72}.—(Radiogallium (Ga^{72}) was administered as a citrate complex (300 to 400 μc) accompanied by 3.8 to 5.0 mg. carrier gallium, contained in 1 c.c. of solution.[5] The Ga^{72} citrate solution was measured in a lead-shielded tuberculin syringe[7] and injected into the rubber tubing of an intravenous infusion drip apparatus. The antecubital vein of the arm was used as the point of administration. The injection was made in one minute. No adverse local or generalized reactions have been observed in any case to date.

Surface Counting.—Suitable points on the body of the patient were marked with indelible ink. Posteriorly, these included twelve points, every 5 cm. along the spine and two series of points laterally over the pelvis. Anteriorly points were marked as follows: two rows of six points, from each groin superiorly to the second intercostal space. Two additional points were located on the upper and lower points of the sternum.

The Geiger tube (Fig. 1) was localized over each point at the surface of the body and a one-minute count recorded. By counterbalancing the jacketed tube, it was possible to maintain the end of the shield gently pressed against the skin surface. No undue discomfort to the patients resulted.

The pattern of counting areas included forty points. Time of each series of counts required approximately one hour. Counts were made at three, ten, and twenty-four hours after the intravenous injection of the tracer dose of Ga^{72} (300 to 400 μc). With this dose it was possible to obtain counts of 600 to 1,100 per minute at the skin surface of the patient three hours after administration of the Ga^{72}. The background rate of the tube used is 7 to 9 counts per minute. In Fig. 5 are shown details of the results of a routine examination of a patient by this method (Case 8).

The addition of counts, taken directly over the xyphoid process at 30 cm. and 90 cm. distances, each count for three minutes, was made in the last five cases of the series. This would tend to indicate the rate of concentration change in the trunk of the patient and act as a base line for comparison of concentrations within each localized area. The biologic half-life as determined by the method in the human patient is 12 to 13 hours.

A significant aid in determining the areas of localization of gallium in various tissues has been the determination of the relative increase of Ga^{72} during the three hour to twenty-four hour period after intravenous injection of the gallium citrate.

The observed Geiger-Müller count over a certain point at three hours after injection is taken as a reference value. The counts over this exact point at ten hours and twenty-four hours, when corrected for decay to the three hour time ($T_{1/2}$ = 14.3 hr.), will indicate whether there has been an increased deposition of gallium in the structures beneath the counting point.

In many normal tissues the amount of gallium will decrease, as indicated by the foregoing calculations. However, in many areas of bone involvement there is a marked increase in deposition of gallium, as indicated by the external counts. This fact has proved most significant in these diagnostic studies.

1176180

Gallium^{72} Tracer Study

Surface Counts

A

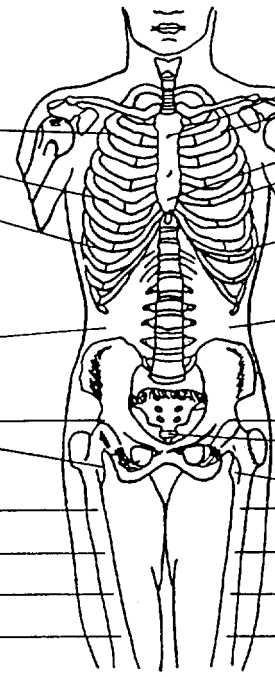

24 hr.	10½ hr.	3 hr.
336	709	1100
349	730	1232
540	632	991
544	763	974
302	591	972
237		
192	355	601
141	296	491
133	313	511
156	268	385

3 hr.	10½ hr.	24 hr.
1792	891	388
1193	684	292
1266	759	386
997	673	320
987	615	289
973	611	368
936	621	306
1765	767	338
		250
754	488	236
756	516	313
652	459	192
380	285	139

Gallium^{72} Tracer Study 3-7-50

Surface Counts

B

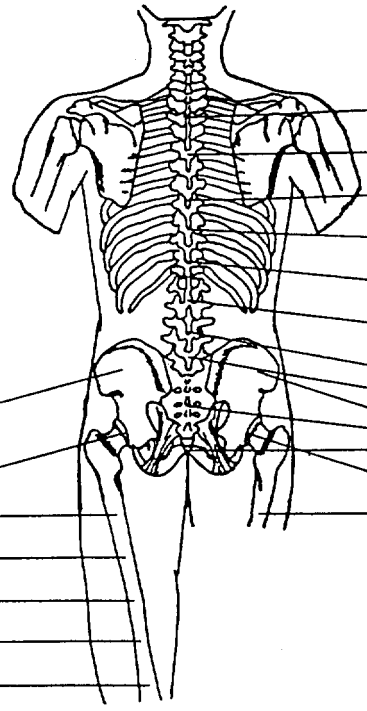

24 hr.	10½ hr.	3 hr.
336	636	915
313	550	811
271	434	633
194		
191		
240		
179		

3 hr.	10½ Hr.	24 hr.
669	643	358
		384
1108	753	388
		399
683	706	396
		424
1065	748	404
		396
954	628	30.7
		327
935	618	334
694	485	258
642	397	246

Fig. 5.—*A*. Anterior of body surface. *B*, Posterior of body surface. The pattern and record of the Geiger-Müller counter rates per minute as made in Case 8. The time period of each count series is from the time of intravenous injection of the tracer dose.

1176181

Case Histories.—In Table I are shown the clinical findings and histories of the first eighteen patients, during the first seven months of the use of Ga^{72}. Of this group, fifteen resulted in positive localization of significant metastatic or primary bone tumor areas, two gave negative results which are consistent with the limited clinical follow-up to date, and in one case a small osteolytic lesion of the ischial spine was missed.

Osteogenic Lesions.—One primary bone tumor is included in the series, an osteochondrosarcoma. This case (Case 7), in a 39-year-old man, had been followed clinically for a period of more than eight years. During this time the patient had had three complete resections of the tumor and two courses of deep x-ray therapy.*

Case 6 was that of a malignant degeneration of an area of myositis ossificans with a locally infiltrating osteogenic sarcoma. This young man, who is now 29 years of age, had received a course of prophylactic deep x-ray therapy for carcinoma of the testes. The areas of treatment included three over the lower abdomen and two areas in the lower half of the spine. The malignant degeneration apparently originated in the upper of the two posterior areas. Following a biopsy of the lesion, the skin failed to heal and at the time of the tracer study there was a large (15 cm.), friable, bleeding, open area. For this reason, it was difficult to get exact counts over the different nodules and to position the patient as much as desired. The standard pattern of counting was modified. All palpable nodules gave significantly increased counting rates. A single isolated lesion on the anterior chest wall could be well studied and indicated a concentration of Ga^{72} of fifteen times that of the surrounding apparently normal tissue. This finding agrees well with what has been found in the other cases.

The remaining cases of the osteogenic group consist of five carcinomas of the prostate. In general, these cases were collected as the original choice for study because the osteogenic nature of the lesion would make them most comparable to growing bone as determined from the animal studies. Significant localization was found in each of these five cases to be proportional to the lesions as indicated by x-ray examination. It was noted in Case 4 that while at the time of the study only one lesion had been localized by the tracer studies, follow-up x-ray films taken one month after the tracer study showed a beginning bone change in each of the two areas; the smaller of these two areas, in the ilium, was approximately 3 cm. in diameter. Case 5, that of a 60-year-old man, had been followed for approximately four years as a fairly typical

*The amount of bone proliferation as compared with the cartilage contained in the tumor mass was relatively small. Areas of increased G.M. counting rates were confined to these areas of bone production and were significantly higher than the counting rates of adjacent areas overlying cartilage. The general level of counting over the palpable tumor was lower than over the opposite area presumed to be normal. The repeated operations and two courses of x-ray therapy may have interfered with the blood supply to the area and prevented absorption and concentration. This is the only case in the series to date in which the counting rate over an area of a clinically suspected lesion or an area of x-ray change was decreased below the adjacent or opposite normal area.

1176182

Paget's disease. Two years ago a positive diagnosis of carcinoma of the prostate was made. At the time of this study the Paget's disease, which had been localized in the right pelvis and right femur, had changed very little. Scattered areas of well-circumscribed osteogenic lesions, 1 to 2 cm. in diameter, were found in the wings of both ilia and in the upper portion of the shaft of the left femur. It is believed on the basis of the prostatic tumor that this represents a separate condition of bone involvement of carcinoma of the prostate. The radiogallium seemed to localize and concentrate equally well in the lesions of both the Paget's disease and the carcinoma of the prostate.

Osteolytic Lesions.—These eleven cases are all secondary metastatic lesions or strongly suspected metastasis in the presence of known carcinoma. The first case of this group which was studied was Case 8, a bronchogenic carcinoma. This patient had developed a large soft tissue tumor associated with an area of destruction of the proximal shaft of the left femur. The patient was approximately one year postoperative for the chest lesion and there was no evidence of a local recurrence. It was considered that if no other areas of metastasis could be localized, and none had been found by x-ray film study, the treatment of the area in the left femur might be more definitive and complete. Concentration and localization within the known area of metastasis was equally as good as in the most striking of the osteogenic lesions. The area went on to pathologic fracture, but in the past four months no evidence of other bony metastases have been found. The localization as found in this case encouraged us to try other osteolytic lesions.

Case 9 was that of a 55-year-old man with gastric carcinoma. This patient had progressed from a symptom-free stage to that of an inoperable carcinoma of the stomach within three months, and within two months after the operative procedure, a total of five months, had at least four separate areas of metastases to the spine. The general progress of the patient was rapidly downhill, and there was marked jaundice as evidence of liver metastasis. Radiogallium Ga^{72} as concentrated in the liver was the lowest of any case of this series. The tracer study localized the known lesions well and in addition indicated possible involvement in the pelvis.

Case 16, a 54-year-old white woman with carcinoma of the breast, had evidence of widespread bony metastasis at the time of her original operation more than one year ago. Hormone therapy with testosterone given over a period of approximately nine months had changed the bone lesions from markedly osteolytic to a significant osteoblastic quality. The hormone therapy was causing a considerable amount of nausea, vomiting, and other generalized symptoms. The bone pain as a result of this therapy had completely disappeared and the patient experienced only a tired feeling after doing a considerable amount of housework. This therapy was therefore discontinued. In the following three months, the x-ray findings were seen to change from the osteoblastic quality into almost the original osteolytic quality. Because of the far-advanced nature of the bone lesions, it was desired to use the Ga^{72} tracer study as a method of determining areas of possible pathologic fracture. The

1176183

PRIVACY ACT MATERIAL REMOVED

TABLE I

CASE	AGE AND SEX	DIAGNOSIS*	EXTENT OF LESION	SIGNIFICANT CONCENTRATION† OF Ga^{72}	24-HOUR URINARY EXCRETION OF Ga^{72} (%)	CONFIRMATORY EVIDENCE AND REMARKS
			Osteoblastic Lesions			
1 11/29/49	49-M	Ca. prostate—P	X-ray—Progressive metastasis: Spine—Bodies of thoracic and lumbar Pelvis—Bilateral widespread Femurs—Proximal ends, most on right	Spine—Proportional to x-ray changes Pelvis—Most in area of greatest osteoblastic activity Femurs—Significant localization	6.9	Concentrations were so definite that differential counts from normal to involved bone areas with even partially shielded and nonshielded G. M. tubes gave significant results
2 12/28/49	69-M	Ca. prostate—P Adenocarcinoma	X-ray—Generalized metastases Thoracolumbar spine Pelvis	Spine—Proportional to x-ray changes Pelvis—Generalized increased activity. Left ilium increased over right. Conc. 8 ×	6.6	Follow-up x-ray studies Patient discharged to home on stilbestrol therapy
3 1/17/50	49-M	Ca. prostate—P	X-ray—Generalized metastases Thoracolumbar spine Pelvis All bones, even ribs and extremities showed mixed destructive and osteoblastic changes	Generalized throughout bone structures, all bony prominences had an increased counting rate Spine and pelvis most, proportional to the x-ray film changes	6.3	Follow-up x-ray studies. Post mortem
4	82-M	Ca. prostate—P	X-ray—Spine—localized Collapse of L-2	Spine—Only area of concentration centered over L-2 Increased Conc. 10 × Pelvis—Right ilium Femur—Left proximal shaft Increased Conc. 30 ×	5.8	Lesions confirmed by x-ray films one month following tracer study Post mortem
5 1/24-50	60 M	Ca. prostate—P Paget's disease of right ilium X-C	X-ray—Pelvis—localized Expanding lesion right ilium Circumscribed areas both ilia Right femur—Expanding mixed lesion Left femur—Circumscribed areas	Pelvis—Generalized increased activity Right ilium increased over left Conc. 16 × Femurs—Both increased Righ increased moderately more	11.2	Follow-up x-ray studies

PRIVACY ACT MATERIAL REMOVED

1176184

PRIVACY ACT MATERIAL REMOVED

6 12/20/49	29-M	Osteogenic sarcoma—P Malignant degeneration of myositis ossificans following deep x-ray therapy for Ca—testicle	X-ray—Trabecular bone identified in several of the larger subcutaneous nodules General—Widespread subcutaneous nodules over mid-back and spreading around to left chest	Back—All nodules showed increased concentration Chest—Localized 6 cm. nodule Conc. 15 ×	11.0	Areas as palpated
7 1/10/50	39-M	Osteochondrosarcoma Recurrent—P	X-ray—Right ilium with extension into left pelvis and right flank	Small areas within extent of lesion gave as much as Conc. 5 × as compared with adjacent areas	13.5	Distribution consistent with pattern of cartilage and bone proliferation
			Osteolytic Lesions			
8 3/7/50	62-M	Bronchiogenic Ca.—P Epidermoid carcinoma	X-ray—Destructive lesion of the proximal shaft of the left femur, 3 × 5 cm., associated with palpable soft tissue mass	Left femur—Limits of destructive lesion indicated by pattern of counts. Conc. 40 × Pelvis—Hip area significantly high	3.6	Known lesion well localized No clinical evidence of other bone metastasis in 4 mo.
9 4/4/50	55-M	Gastric Ca.—P	X-ray—Spine—Multiple areas of destruction including: C-6, T-6, T-10, T-11 and L-5	Spine—Areas as noted on x-ray films C-6 Conc. 8 × T-10 Conc. 8 × L-5 and S-1 Conc. 7 × Right ilium—Anterior and posterior localization Conc. 8 ×	24.8	Known lesions well localized Right ilium confirmed at post mortem
10 4/11/50	64-M	Abdominal mass 15 cm. in diameter. No indication of exact diagnosis after G.I., B.E., or I.V.P. studies X-C	X-ray—No changes at time of study Bone pain—Acute and increasingly severe pain and aching over L-3 Deep tenderness—localized within a small area of L-3	Spine—Lumbar area, centering over L-3 extending from L-1-L-5 Conc. 12 ×	16.5	X-ray—Lesion of destruction was identified 1 mo. after tracer study in the body of L-3 X-ray therapy—Given immediately after tracer study to lumbar spine gave very satisfactory palliative relief
11 4/18/50	28-F	Ca. breast—P	Spine—Bone pain and deep tenderness proximal lumbar region Atonic bladder and bowel X-ray—No bone lesion	Spine—Increased and localized concentration over L-1, L-2, L-3 Conc. 15 × Pelvis—Right mid-section Conc. 8 ×	20.0	X-ray therapy—Moderate and significant palliative response to deep x-ray therapy over lumbar spine
12 4/25/50	45-F	Ca. breast—P Adenocarcinoma	X-ray—No bone lesions seen on repeated series Bone pain—Lower back and left hip 2 yr., increased frequency and more localized previous 3 mo.	None	33.0	No change in clinical picture in past 2 months

(*Continued on following page.*)

PRIVACY ACT MATERIAL REMOVED

1176185

PRIVACY ACT MATERIAL REMOVED

1116186

TABLE I—CONT'D

CASE	AGE AND SEX	DIAGNOSIS*	EXTENT OF LESION	SIGNIFICANT CONCENTRATION OF Ga^{72}	24-HOUR URINARY EXCRETION OF Ga^{72} (%)	CONFIRMATORY EVIDENCE AND REMARKS
13 5/2/50	45-M	Ca. of bladder—P Transitional cell Grade III	X-ray—No lesions found Bone pain—increasing pain in the lower spine and left hip Local tenderness—in lower thoracic, mid-lumbar and upper sacral areas	Spine—Localization at: T-8, T-9, T-10 Conc. 7 × L-1, L-2, L-3 Conc. 8 × S-1, S-2 Conc. 7 × Pelvis—Some increased concentration, more on the left	10.7	X-ray therapy—Significant relief of pain after palliative treatment to lumbar spine
14 5/10/50	48-M	Ca. of lip—P Squamous cell Grade III	X-ray—Left ischial tuberosity Bone pain—Spine and pelvis Soft tissue extension to neck and shoulders with generalized subcutaneous nodules	None	23.5	Known area by x-ray too close to bladder for localization
15 5/23/50	49-M	Multiple myeloma—P 50% replacement of sternal marrow	X-ray—Generalized, medium sized lesions in skull, ribs, spine, pelvis, and femurs. Collapse of body of T-10. Lesions progressive on serial films	Spine—Generalized increase of concentration, most over T-10, T-11 Conc. 10 × L-2, L-3 Conc. 8 × Pelvis—High area over right iliac crest	9.7	Consistent with degree of involvement as seen on x-ray films Highest concentration over area of collapsed vertebral body
16 6/1/50	54-F	Ca. breast—P Carcinoma simplex	X-ray—Generalized, moth-eaten, most prominent over: Lumbar spine Pelvis Mixed osteoblastic-osteolytic lesions	Increased concentration within all bone areas studied, most in Spine—lumbar Conc. 7 × Pelvis—right post Conc. 5 × Femurs—both increased, left most	15.9	X-ray changes in spine and pelvis consistent with localization Concentration in femurs significant as compared with minimal x-ray findings
17 6/13/50	39-F	Ca. thyroid—P Papillary adenoma	X-ray—Area of rarefaction left humerus Bone pain—localized areas with deep tenderness over: Left humerus Spine L-3 Right femur—mid-shaft	None	13.9	X-ray opinion modified after this study, to have serial films as follow-up Negative I^{131} tracer study for functioning thyroid except in the neck region
18 6/20/50	62-M	Ca. of bladder—P Transitional cell Grade III, recurrent	X-ray—Destruction of articular facets of right side of L-2 and L-3 Bone pain—Lumbar spine with radiation into right leg	Spine T-8 and T-9 Conc. 7 × L-2 and L-3 Conc. 9 × Pelvis—Bilaterally, front and back, most just superior to acetabula Femurs—Possible bilateral involvement	17.1	Known lesion highest concentration, other areas had good comparable amounts

*Diagnosis: P, pathologic sections; X, x-ray impression; C, clinical impression.

†Concentration: Estimated in terms of the apparent concentration in the lesion as compared with an uninvolved area of bone opposite or adjacent. In reference to the spine, the counting rate for an area is compared with the average of all points on the spine. Conc. 8× means a concentration of eightfold greater than the bone area used for comparison, etc.

PRIVACY ACT MATERIAL REMOVED

counting rate over all of the bony prominences was increased, with significant concentration within the lower spine and pelvis. Since the gallium study, the patient has had an increasing amount of bone pain to the extent that gallium therapy has been considered. The hormone therapy has been reinstituted in an effort to enhance the concentration of the radiogallium.

Included with the osteolytic lesions is a single case of multiple myeloma. This patient, Case 15, a 49-year-old white man, had a very recently diagnosed multiple myeloma. Although the lesions were of moderate size and widespread, there was only one area of collapse within the spine. A sternal marrow count showed approximately 50 per cent replacement with typical plasma cells and multinucleated plasma cells. Palliative x-ray therapy had been given over the area of the known collapse in the region of T_{10}. This had resulted in significant relief of bone pain. It therefore seemed consistent that an isotope was the logical means of therapy. The first choice was radiophosphorus (P^{32}). A tracer study with radiogallium was done at this time in order to avoid a delay in starting radiogallium therapy in case the radiophosphorous therapy was unsatisfactory. The results of this study were quite comparable to those seen in Case 3 of carcinoma of the prostate with generalized metastases and Case 16 of carcinoma of the breast. In the five-week follow-up period following P^{32} therapy, a general improvement of the patient has been sufficient so that to date it has not been necessary to consider any other type of therapy.

Urinary Excretion.—The urinary excretion in these eighteen patients has been studied in considerable detail. Each separate urine specimen voided by the patient during the first twenty-four hours of the study was radiometrically measured. In general the excretion pattern is similar to that of radioiodine I^{131} [6, 8]; the principal amount excreted is within the first six hours after the dose. The rate of excretion rapidly drops after that period and is negligible after twenty-four hours. From Table I it can be seen readily that in carcinoma of the prostate the amount of excretion is remarkably small. Osteogenic lesions tend to retain more of the total amount of the tracer dose than osteolytic lesions. In the majority of the cases, the amount of Ga^{72} excreted is inversely proportional to the extent of bone involvement. However, in a significant number of cases the pattern and amount of Ga^{72} excretion differ from the rest of the findings.

Additional study of these differences indicated that a tracer dose of 300 to 500 μc of Ga^{72} is sufficient to get reasonably accurate counting rates during the time of measurement of the urine activity. The radiometric method has been checked in a number of cases against the total amount of carrier gallium as excreted in the urine and determined by chemical methods.[1] The agreement between the two methods is sufficient to indicate the practical accuracy of the radiometric method.

The frequency and the total amount of urine voided seem to have an effect on Ga^{72} excretion. In relative polyuria with amounts of urine over 3,000 c.c. in twenty-four hours, there tends to be an increased excretion of gallium.

1176187

SUMMARY AND CONCLUSIONS

Geiger counting techniques applied to the skin surface of human beings have been shown to be useful for the localization of radiogallium (Ga^{72}) citrate in osteoid structures.

Intravenous tracer doses of Ga^{72} citrate have been selectively concentrated in the osteoid lesions, both osteogenic and osteolytic, in fifteen of eighteen cases of primary and secondary bone malignancies.

Concentration of Ga^{72} in malignancies involving bone approaches twenty times that found in the adjacent bone.

Early metastases to bone have been identified through the use of tracer amounts of Ga^{72} before changes could be identified by x-ray film study.

The authors wish to acknowledge the assistance of the personnel of the Radiation Technology Division, NMRI, for the preparation and standardization of the radiogallium samples, and of H. Friedman, Department of Optics, Naval Research Laboratory, for his assistance in the design and construction of the special Geiger tube and shield.

REFERENCES

1. Dudley, H. C.: Determination of Gallium in Biological Materials, J. Pharmacol. & Exper. Therap. 95: 482, 1949.
2. Dudley, H. C., Maddox, G. E., and LaRue, H. C.: Studies of the Metabolism of Gallium, J. Pharmacol. & Exper. Therap. 96: 135, 1949.
3. Dudley, H. C., and Maddox, G. E.: Deposition of Gallium in Skeletal Tissues, J. Pharmacol. & Exper. Therap. 96: 224, 1949.
4. Dudley, H. C., Munn, J. I., and Henry, K. E.: Studies of the Metabolism of Gallium II, J. Pharmacol. & Exper. Therap. 98: 105, 1950.
5. Dudley, H. C.: Gallium Citrate and Radiogallium (Ga^{72}) Citrate, J. Am. Chem. Soc. 72: 3822, 1950.
6. Mulry, W. C.: Skin Surface Localization of I^{131} Within the Thyroid. To be published.
7. Dudley, H. C., Bronson, J. F., and Taylor, R. O.: Shielding of Syringes Used for Injecting Radioactive Solutions, Science 110: 16, 1949.
8. McArthur, J. W., Rawson, R. W., Fluharty, R. G., and Means, J. H.: The Urinary Excretion of Radioactive Iodine as an Aid in the Diagnosis of Hyperthyroidism, Ann. Int. Med. 29: 220, 1948.

1176188