OAK RIDGE INSTITUTE OF
INCORPORATED
P. O. BOX 1
OAK RIDGE, TENNESSEE
TELEPHONE 483-8

723941

January 27, 1965

AUG 24 1965

CODE NO.
E-11
Iodine

Dr. Walter S. Snyder
Building 4500-S, Room G-256
Oak Ridge National Laboratory
Oak Ridge, Tennessee

Dear Dr. Snyder:

Enclosed is a pre-print of an article that will be published soon that I thought you might be interested in.

Yours truly,

R. J. Cloutier
Radiation Safety Officer

RJC:w
Enclosure

BEST COPY AVAILABLE

REPOSITORY MMES- ORNL
COLLECTION 45605 Attic
BOX No. KZ morgan
FOLDER E-9

A-00541
Human Studies Project

1168219

CONGENITAL HYPOTHYROIDISM FROM INTRAUTERINE ^{131}I DAMAGE

Peter Pfannenstiel, MD, Gould A. Andrews, MD, and Donald W. Brown, MD

Gould A. Andrews, MD, Chairman, the Medical Division, Oak Ridge Institute of Nuclear Studies, Box 117, Oak Ridge, Tennessee.

Work done during the tenure of an appointment [illegible] in Clinical Investigation (Dr. Pfannenstiel) and as Postgraduate Assistant in Medicine (Dr. Brown).

Present addresses: Dr. med. Peter Pfannenstiel, [illegible]-Abteilung der Medizinischen Universitaetsklinik, Hugstetter [illegible], 7800 Freiburg i. Br., Germany; Donald W. Brown, MD, Section [illegible] Medicine, University of Colorado, 4200 East Ninth Avenue, [illegible] Colorado 80200.

From the Medical Division, Oak Ridge Institute of Nuclear Studies, Oak Ridge, Tennessee, under contract with the United States Atomic Energy Commission.

1168220

Radioiodine damage to the fetal thyroid gland may occur as a result of ^{131}I treatment during pregnancy. Russell et al[1,2] reported accidental ^{131}I therapy with 225 millicuries and 75 millicuries of ^{131}I in two pregnant women with thyroid malignancies at approximately the thirteenth week of gestation. The first offspring was hypothyroid, the second athyroidic (postmortem diagnosis). Hamill et al[3] treated a woman with 77 millicuries of ^{131}I for thyroid cancer when she was unknowingly three months pregnant. At about twelve weeks of age the child was found hypothyroid, although there was no initial evidence of cretinism. Ray et al[4] reported the treatment of a thyrotoxic patient with 14.5 millicuries ^{131}I during the fifth month of an unsuspected pregnancy. Her child developed hypothyroidism in early infancy. The clinical data on these four known instances of iatrogenic congenital hypothyroidism are tabulated in summary by Fisher et al[5] in a follow up study of the last case.

A number of other reports are available on the inadvertent use of ^{131}I during pregnancy as a therapeutic agent in hyperthyroidism, and as yet no untoward effects have been noted. Chapman et al[6] treated one patient in the second and another in the sixth month of pregnancy with ^{131}I. No evidence of hypothyroidism had appeared in the infants when they were more than one year old. Clever[7] described normal development up to the age of five months in a child whose mother received 5 millicuries of ^{131}I at eight weeks of gestation. Hodges et al[8] administered 6.1 millicuries of ^{131}I during the nineteenth week of pregnancy, but no signs of hypothyroidism were found in the child during a follow-up of one year. Avanzini and Marinoni[9, 10] observed normal development in an infant up

1168221

to the age of five years after treatment of the mother with 5 millicuries of ^{131}I when she was 2½ months pregnant. Silver[11] treated "on several occasions" women with ^{131}I in the face of unrecognized early pregnancy without deleterious effects to the fetus. There are doubtless similar unreported cases.

Therapeutic and diagnostic use of ^{131}I during pregnancy has also been reported to be associated with malformations in the offspring. Valensi and Mahum[12] made the clinical diagnosis of "complete destruction of the fetal thyroid gland" in a premature malformed child after ^{131}I (dose not stated) was given to the mother for thyrotoxicosis at the twenty-eighth to thirtieth day of gestation. Falk[13] reported similar malformations in a child whose mother received only 15 microcuries of ^{131}I for a diagnostic thyroid test on the twenty-fifth or fortieth day of pregnancy. Zalcutti et al[14] calculated a fetal whole-body dose of 0.008 r and a fetal thyroid dose of 300 r from 15 microcuries of ^{131}I given to the mother; however, the data presented are inadequate for reviewing the calculation.

Case Report

For two years we have had the opportunity of observing the child of a young mother who had received a therapeutic dose of ^{131}I during an unrecognized pregnancy. The mother is a single woman with papillary and follicular carcinoma of the thyroid gland. By December 1961, she had received a total of approximately 1600 millicuries of ^{131}I after total thyroidectomy and approximately 4200 r of local irradiation from a cobalt-60 source. On March 20, 1962, when 18 years old, the patient was

1168222

given 99 millicuries of ^{131}I orally because of evidence of persisting functioning thyroid tissue. Within two days after the administration 92% of the dose was excreted and only a faint uptake of ^{131}I could be demonstrated by scans of the neck.

Subsequent events revealed that the patient must have been about 2½ months pregnant at the time of the ^{131}I treatment. The last regular menstrual period began on December 25, 1961. The patient stated that she was exposed to pregnancy only on January 7, 1962. According to this information the age of the fetus was about 72 days or 10 weeks, computed on the assumption that conception took place 14 days after the last menstrual period. When the pregnancy was discovered in its sixth month, the substitutional therapy with 3 grains of desiccated thyroid daily was increased gradually to 10 grains of desiccated thyroid daily to prevent the offspring from the possibility of developing hypothyroidism (Carr et al[15]; Bederwaltes[16]).

After an uneventful gestation a full term male child was delivered on October 29, 1962, with prophylactic low forceps. The newborn was reported to appear normal. The pertinent physical findings are summarized in Table 1. The child was not seen by us at birth nor did we have an opportunity to follow him during the early months of his life. His physicians were informed about the possibility of congenital hypothyroidism. It was not until the age of eight months that we saw him and noted lethargy, hoarseness, frequent upper respiratory infections in conjunction with a typical cretinoid appearance (Fig 1). Serum protein-bound iodine (PBI) was 2.8 μg/100 ml (normal range at this age is 6.3 ± 1.0 μg/100 ml,

1168223

Dunowski et al[17]) and the roentgenological bone age was less than three months (Fig 2).

At this time 1 microcurie of ^{131}I was given to the child orally and the total-body retention was measured with a 2-in. by 2-in. NaI (Tl) crystal in a 6-in.-thick shielded box. At the first day after the ^{131}I administration the baby retained 54%, at the second day 24%, and at the third day less than 10% of the dose. A similar study was carried out at the age of 25 months in the about 15 times more sensitive low-level whole-body counter after the intramuscular injection of 1 microcurie of ^{131}I. Thyroid replacement therapy had been discontinued one week previously and 10 USP units of thyrotropic hormone (TSH) were administered intramuscularly 24 hours before. Figure 3 shows that only about 1% of the administered dose was retained at three days. Only 0.5% was detected with a 2-in. NaI (Tl) crystal over the infant's thyroid area 24 hours after the ^{131}I injection. This radioactivity probably represented circulating inorganic ^{131}I. No ^{131}I-activity was found in the child's neck at two and three days. The data were entirely compatible with a total absence of functioning thyroid tissue (Lushbaugh[18]). The low PBI level can be explained as merely reflecting ingested iodine as it would be found in milk.

For his hypothyroidism, the boy has been treated by a pediatrician at his home town since the age of eight months with desiccated thyroid, starting with 1 grain daily which was raised to 3 grains daily at the present time. The child is doing progressively better with length, weight, and bone age almost normal (Table 1 and Fig 4). The mental development

1168224

of the infant, however, is definitely retarded with a marked delay in developing language skills and inability to stand or to walk without assistance. The boy also still suffers from frequent upper respiratory tract infections associated with cough, probably due to mucosal thickening and chronic inflammation secondary to myxedema (Lowrey et al[19]; Najjar[20]).

Discussion

In view of the previously cited reports[1-4], it seems likely that our case represents the fifth reported instance of intrauterine radioiodine damage to the fetal thyroid gland. This occurred presumably during the tenth week of embryonal life and is earlier than in all other published instances of congenital hypothyroidism induced by ^{131}I.

The time at which the human fetal thyroid gland begins to function has been studied by several investigators (Table 2). The reported data indicate that in the first 11 or 12 weeks of fetal life no radioiodine is collected but that after the fourteenth week increasing amounts of ^{131}I are taken up by the fetal thyroid gland. Speert et al[26] reported that the fetal mouse first concentrates ^{131}I in the thyroid gland at the fourteenth and fifteenth day of gestation. Since this time is comparable to the ninth to eighth week in human development (Otis et al[25]), Jacobson et al[27] suspected that the human fetal thyroid gland concentrates iodine earlier than the twelfth week, probably as early as the seventh week.

The last assumption corresponds with Beierwaltes[28] observation of follicles in the thyroid of an eight-week-old human fetus. Benson[29] and French and Van Wyk[30] stated also that well-differentiated structures

1168225

in the fetal thyroid gland are present between the seventh and twelfth week of human gestation. Goldstein[31] demonstrated autoradiograms of an 18-week old human fetal thyroid gland where ^{131}I was present not only in colloid-containing follicles but also in follicles containing little or no colloid. Organically bound iodine was found as early as the fifty-third day in fetal calf thyroid (total gestation period in cattle is 285 days), a time before the appearance of histologically detectable intracellular colloid or follicle formation (Koneff et al[32]).

Even though the relative avidity of the fetal thyroid gland for iodine is already greater than that of the maternal thyroid gland (Gorman et al[33]; Evans[34]; French and Van Wyk[30]), it was found that fetal rats and rabbits show earlier an increased ^{131}I uptake in the thyroid gland when the mothers had partial thyroidectomy (Lampé et al[35, 36]). In addition Logothepoulos and Scott[37] and Nataf et al[38] demonstrated in guinea pigs and rats an active transport mechanism for iodide in the placenta resulting in a higher iodine concentration in the fetal blood.

All these observations suggest that the human fetal thyroid gland probably is capable of concentrating iodine earlier than at the twelfth week of embryonal life, especially in instances where the maternal thyroid function is defective, as in our patient.

In instances of ^{131}I therapy for hyperthyroidism with doses mostly less than 10 millicuries during unsuspected pregnancy after which normal babies were born[6-11], apparently enough tissue of the fetal thyroid gland remained undamaged so that it could continue to develop into a normally functioning organ (TID-11645[24]). In addition, most of the ^{131}I was

1168226

probably removed by the thyrotoxic maternal glands, while metastatic thyroid carcinoma is not able to remove much of the larger ^{131}I tumor doses from the circulation, resulting therefore in complete destruction of the fetal thyroid gland by the radiation (Delsol et al[39]). Goldstein[31] reported that an 18-week-old human fetal thyroid gland contained enough ^{131}I to ensure a radiation dosage of at least 80,000 rads after the mother had received 71.5 millicuries of ^{131}I six days earlier as therapy for metastatic thyroid cancer.

A causal relation of our observation of congenital athyroidism to the ^{131}I treatment of the mother as early as in the tenth week of her pregnancy seems a strong possibility to us. Since besides the ^{131}I concentration in the fetal thyroid gland the entire fetus is exposed to radiation from placental migration of ^{131}I as well as from the ^{131}I in the maternal and excretory systems, the possibility of genetic, carcinogenic, or life-shortening effects should also be kept in mind. Use of radioiodine in therapeutic amounts should in our opinion be avoided completely at any stage of pregnancy.

Comment

Regrettably, despite the greatest care and planning, inadvertent administration of ^{131}I to gravid patients will likely occur again in the future. From reviewing the pertinent literature and our own observation, the following seems to be important in the management of such complications:

1168227

1. When ^{131}I is administered during pregnancy and there is the possibility that the fetal thyroid gland is damaged, large doses of thyroid hormones should be given to the mother. This artificial hyperthyroidism will lead to significant transplacental passage of thyroid hormone to the fetus, especially when triiodothyronine is given. This will prevent possible intrauterine hypothyroidism and arrest in brain development (Grumbach and Werner[40]; Carr et al[15]; Beierwaltes[16]; French and Van Wyk[30]).

2. Because cretins rarely show obvious signs of hypothyroidism in the neonatal age (Fisher[41]), evidence of intrauterine thyroid deficiency or absence of functioning thyroid tissue should be diagnosed as early as possible in all patients suspected of having thyroid abnormalities. The following tests proved to be helpful:

   a) Determination of protein-bound iodine (PBI) and thyroxine iodine in the cord blood (Russell et al[1,2]; Lowrey et al[19]).

   b) Determination of bone age by roentgenograms of hands and wrists (Lusted and Pickering[42]).

   c) Radioiodine studies, if necessary in conjunction with a thyrotropin (TSH) stimulation test (Van Middlesworth[43]; Carr et al[15]; Lushbaugh[18]).

With early adequate treatment, normal physical and mental development can possibly be expected even in children with radiologically damaged thyroid glands.

1168228

Summary

An 18-year-old woman with thyroid cancer was treated with 99 millicuries of ^{131}I before she was known to be pregnant. The age of the fetus was estimated to be 72 days. The child appeared normal at birth but was found to be athyroidic eight months later. Rapid ^{131}I disappearance, as determined by whole-body counting, was compatible with complete absence of thyroid. This was apparently destroyed in utero by the ^{131}I given to the mother. Therefore, the human fetal thyroid gland must be capable of concentrating iodine earlier than at the twelfth week of embryonal life. This represents the fifth reported instance of intrauterine ^{131}I damage to the fetal thyroid gland. When ^{131}I is given inadvertently during pregnancy, the mother should be treated with high doses of thyroid hormones to prevent iatrogenic congenital hypothyroidism.

Acknowledgement

The first determination of the whole-body retention of ^{131}I was performed by A. C. Morris, Jr. and C. C. Lushbaugh, and the second (Fig 3) was done with the technical assistance of William D. Gibbs, members of the Medical Division staff.

1168229

References

1. Russell, K.P.; Rose, H.; and Starr, P.: Radioactive Iodine During Pregnancy; Effects on Maternal and Fetal Functions, Trans Pacific Obstet Gynecol Soc 24:62-70, 70-73 (discussion), 1956.

2. Russell, K.P.; Rose, H.; and Starr, P.: The Effects of Radioactive Iodine on Maternal and Fetal Thyroid Function During Pregnancy, Surg Gynec Obstet 104:560-564, 1957.

3. Hamill, G.C.; Jarman, J.A.; and Wynne, M.D.: Fetal Effects of Radioactive Iodine Therapy in a Pregnant Woman with Thyroid Cancer, Amer J Obstet Gynec 81:1018-1023, 1961.

4. Ray, E.W.; Sterling, K.; Gardner, L.I.: Congenital Cretinism Associated with ^{131}I Therapy of the Mother, AMA J Dis Child 98: 506-507, 1959.

5. Fisher, W.D.; Voorhess, M.L.; and Gardner, L.I.: Congenital Hypothyroidism in Infant Following Maternal I^{131} Therapy, J Pediat 62:132-146, 1963.

6. Chapman, E.M.; Corner, G.W., Jr.; Robinson, D.; and Evans, R.D.: The Collection of Radioactive Iodine by the Human Fetal Thyroid, J Clin Endocrinol 8:717-720, 1948.

7. Clever, J.E.: Radioactive Iodine for Hyperthyroidism Administered During Early Pregnancy, Amer J Obstet Gynec 61:217-219, 1951.

8. Hodges, R.E.; Evans, T.C.; Bradbury, J.T.; and Keettel, W.C.: The Accumulation of Radioactive Iodine by Human Fetal Thyroids, J Clin Endocr 15:661-667, 1955.

1168230

9. Avanzini, S.; and Marinoni, U.: Considerazioni su di un caso di ipertiroidismo trattato con iodio radioattivo (^{131}I) in gravidanza, Minerva Nucl 5:21-24, 1961.

10. Avanzini, S.; and Marinoni, U.: Considerazioni su di un caso di ipertiroidismo trattato con iodio radioattivo (I^{131}) in gravidanza, Minerva Pediat 12:152, 1960.

11. Silver, S.: Radioactive Isotopes in Medicine and Biology, Vol. 2 Medicine, 2nd ed., Philadelphia, Lea and Febiger, 1962, page 104-105.

12. Valensi, G.; and Nahum, A.: Action de l'iode radio-actif sur le foetus humain, Tunisie Med 36/2:69-73, 1958.

13. Falk, W.: Beitrag zur Frage der menschlichen Fruchtschädigung durch künstliche radioaktive Isotope, Medizinische 33/34:1480-1484, 1959.

14. Zerutti, A.; Turchetti, G.; and Bartalena, R.: Considerazioni sull' uso dello iodio radioattivo in gravidanza ed in puerperio, Minerva Ginec 11:619-622, 1959.

15. Carr, E.A., Jr.; Beierwaltes, W.H.; Braman, G.; Dodson, V.N.; Tanton, J.; Betts, J.S.; and Stambaugh, R.A.: The Effect of Maternal Thyroid Function on Fetal Thyroid Function and Development, J Clin Endocr 19:1-18, 1959.

16. Beierwaltes, W.H.: Personal communication, 1962.

17. Danowski, T.S.; Johnston, S.Y.; Price, W.C.; McKelvy, M.; Stevenson, S.S.; and McCluskey, E.R.: Protein-bound Iodine in Infants from Birth to One Year of Age, Pediatrics 7:210-214, 1951.

18. Lushbaugh, C.C.: A Universally Applicable Method for Assaying Thyroid Function in Vertebrates, Nature 198:862-864, 1963.

1168231

19. Lowrey, G.H.; Aster, R.H.; Carr, E.A.; Hamon, C.; Beierwaltes, W.H.; and Spafford, N.R.: Early Diagnostic Criteria of Congenital Hypothyroidism: A Comprehensive Study of Forty-nine Cretins, AMA Am J Dis Child 96:131-143, 1958.

20. Najjar, S.: Respiratory Manifestations in Infants with Hypothyroidism, Arch Dis Child 37:603-605, 1962.

21. Avanzini, S.; and Marinoni, U.: Sulla fissazione dello I^{131} da parte della trioide fetale umana, Annals di Ostetricia e Ginecologia 77: 893-896, 1955.

22. Marinoni, U.: Fissazione dello I^{131} nella tiroide fetale umana (descrizione di un caso), Folia Endocr (Pisa) 4:637-640, 1951.

23. Yamazaki, E.; Noguchi, A.; and Slingerland, D.W.: The Development of Hormonal Biosynthesis in Human Fetal Thyroids. J Clin Endocr 19:1437-1439, 1959.

24. Radioiodine Studies of Fetal and Other Thyroids, Technical Progress Report, January 1961, U.S. AEC Report TID-11645, 14 p.

25. Otis, E.M.; and Brent, R.: Equivalent Ages in Mouse and Human Embryos, Anat Rec 120:33-63, 1954.

26. Speert, H.; Quimby, E.H.; and Werner, S.C.: Radioiodine Uptake by the Fetal Mouse Thyroid and Resultant Effects in Later Life, Surg Gynec Obstet 93:230-242, 1951.

27. Jacobson, A.G.; and Brent, R.L.: Radioiodine Concentration by the Fetal Mouse Thyroid, Endocrinology 65:408-416, 1959.

28. Beierwaltes, W.: Personal communication, 1964.

1168232

29. Benson, R.C.: Discussion of Russell, K.P., Rose, H., and Starr, P.: Radioactive Iodine During Pregnancy; Effects on Maternal and Fetal Functions, Trans Pacif Coast Obstet Gynec Soc 24:170-172, 1956.

30. French, F.S.; and Van Wyk, J.J.: Fetal Hypothyroidism, J Pediat 64:589-600, 1964.

31. Goldstein, D.J.: Uptake of Iodine-131 by an 18-Week Human Foetus, S Afr Med J 32:239-241, 1958.

32. Honeff, A.A.; Nichols, C.W., Jr.; Wolff, J.; and Chaikoff, I.L.: The Fetal Bovine Thyroid: Morphogenesis as Related to Iodine Accumulation, Endocrinology 45:242-249, 1949.

33. Corthman, A.; Lissitzky, S.; Michel, O.; Michel, R.; and Roche, J.: Metabolism of Radioiodine by the Near-term Bovine Fetus, Endocrinology 51:546-561, 1952.

34. Evans, T.C.: Radioiodine Studies of Fetal and Other Thyroids, Technical Progress Report, January 1962, U.S. AEC Report TID-14828, 14 p.

35. Lampé, L.; Kertész, L.; Péter, F.; and Medveczky, L.: Intrauterine Iodine Metabolism, Acta Physiol Acad Sci Hung 20:11-22, 1961.

36. Lampé, L.; Medveczky, L.; and Kertész, L.: Storage of Iodine in the Foetal Thyroid, Acta Physiol Budapest 20:385-391, 1961.

37. Logothetopoulos, J.; and Scott, R.F.: Concentration of Iodine-131 Across the Placenta of the Guinea Pig and the Rabbit, Nature 175: 775-776, 1955.

1168233

38. Nataf, B.; Sfez, M.; Michel, R.; and Roche, J.: Metabolisme des iodures chez les Rattes gestantes et les foetus. Concentration de l'iode radioactif par le placenta, C R Soc Biol (Par) 150:324-327, 1956.

39. Delsol, M.; and Berger, M.: Action de l'iode radioactif sur la Souris gestante. Essai de destruction experimentale de la thyroide de la mere et du foetus, C R Soc Biol (Par) 157:470-472, 1963.

40. Grumbach, M.M.; and Werner, S.C.: Transfer of Thyroid Hormone Across the Human Placenta at Term, J Clin Endocr 16:1392-1395, 1956.

41. Fisher, D.A.: Management of Hypothyroidism During Infancy and Childhood, Modern Treatment 1:128-145, 1964.

42. Lusted, L.B.; and Pickering, D.E.: The Hypothyroid Infant and Child: The Role of Roentgen Evaluation in Therapy, Radiology 66: 708-717, 1956.

43. Van Middlesworth, L.: Radioactive Iodine Uptake of Normal Newborn Infants, AMA J Dis Child 88:439-442, 1954.

1168234

Legends

Fig. 1 Patient at 10 months. Note classic cretinoid facies with sparse hair, narrow forehead, depressed nose bridge, puffy eyes and cheeks, protruding tongue, and thick neck.

Fig. 2 Roentgenograms showing skeletal maturation.

Fig. 3 Whole-body retention of ^{131}I at 25 months.

Fig. 4 Patient at 25 months. Note overall clinical improvement in comparison with Fig 1; however, the face still appears broad, nose flat, tongue enlarged.

1168235

Table 1. Clinical data of observed patient.

	Birth	7½ Months	10 Months	16 Months	25 Months
Weight (percentile)	8 lb 5 oz (75)	18 lb (10)	—	30 lb (97)	31 lb 8 oz (90)
Length (percentile)	20½ in (75)	25 in (less than 3)	—	30 in (less than 3)	33 in (10)
Circumference of head (percentile)	35.5 cm (75)	38 cm (less than 3)	—	—	48.5 cm (10)
Circumference of chest (percentile)	33 cm (50)	—	—	49.5 cm (75)	53 cm (75)
Bone age (Todd Atlas)	—	between birth and 3 months	—	5-6 months	15-21 months
PBI (μg/100 ml)	—	3.8 (normal: 6.3 ± 1.0)	2.8 (normal: 4-8)	4.9 (normal: 4-8)	1.5 (normal: 4-8)
Thyroxine iodine (μg/100 ml)	—	—	—	3.4 (normal: 3.2-6.4)	1.0 (normal: 3.2-6.4)
Remarks	normal newborn	Cretinoid facies, hoarseness	rapid ^{131}I disappearance	1 grain dessicated thyroid daily	no thyroid hormones for 1 wk

116823b

Table 2. Observed fetal age, at which the human fetal thyroid gland begins to function, studied by radioiodine uptake.

	Week of Embryonal Life
Chapman et al[6]	12th
Avansini and Marinoni[21]	13th
Hodges et al[8]	11-12th
Marinoni[22]	16th
Yamazaki et al[23]	14th
NIH-11645[24]	11th

1168237



A B C

	CHRONOLOGICAL AGE	BONE AGE (Todd ATLAS)
A	8 months	between birth & 3 months
B	16 months	between 5 & 6 months
C	24 months	between 15 & 21 months

1168238

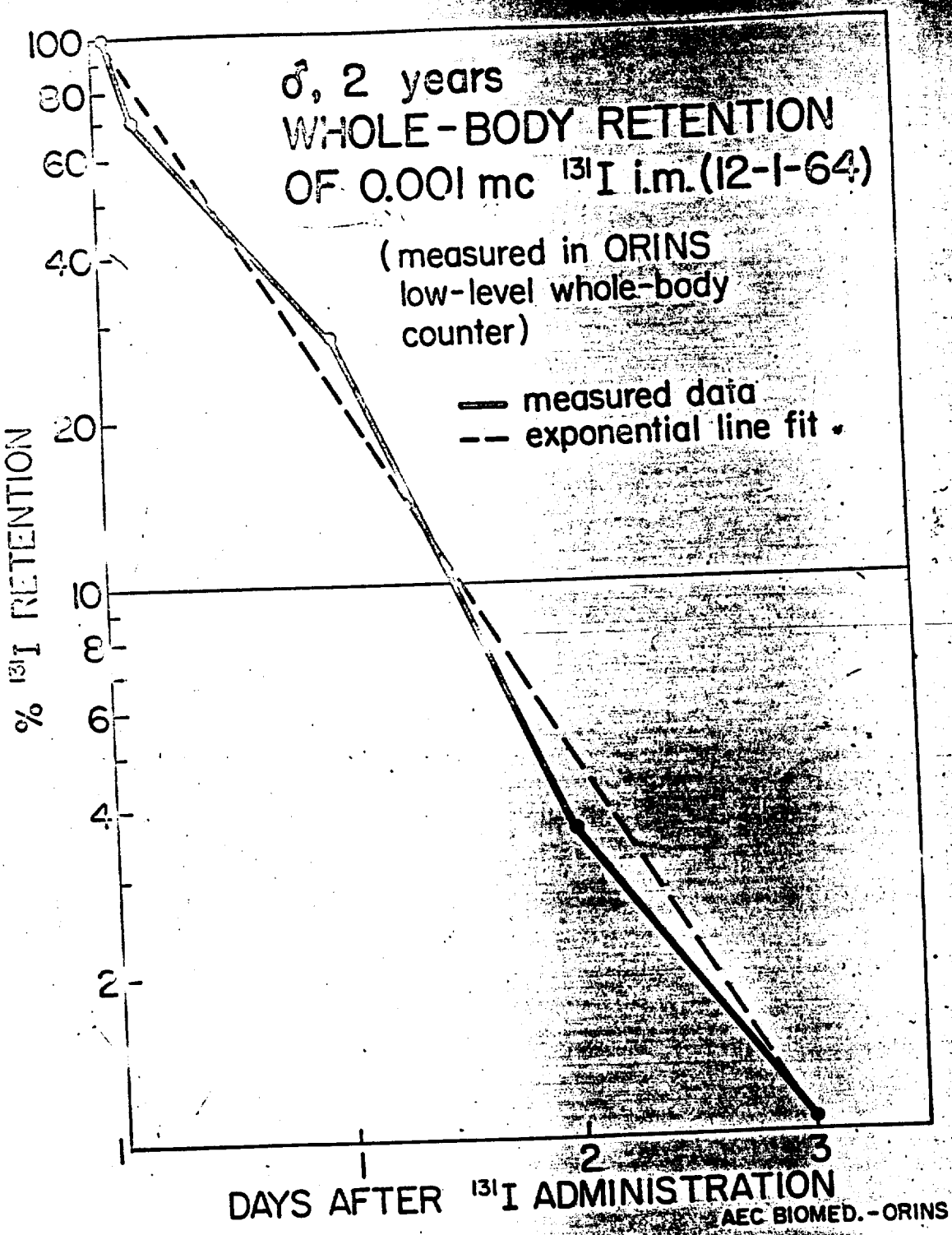
♂, 2 years
WHOLE-BODY RETENTION
OF 0.001 mc ^{131}I i.m. (12-1-64)
(measured in ORINS low-level whole-body counter)
measured data
exponential line fit
% ^{131}I RETENTION
100
80
60
40
20
10
8
6
4
2
1
2
3
DAYS AFTER ^{131}I ADMINISTRATION
AEC BIOMED.-ORINS

1168239