722082

BEST COPY AVAILABLE

Sodium Selenite Se 75

A More Specific Agent for Scanning Tumors

Ralph R. Cavalieri, MD, and Kenneth G. Scott, PhD

Brain scanning, with any of several radioactive pharmaceutical agents, permits the accurate localization of intracranial lesions. Bone scanning, with radioactive strontium, allows the detection of localized disease of the skeleton. However, none of the agents in current use is specific for tumors. In an attempt to improve the diagnostic accuracy of radioisotope scanning, the usefulness of a new agent, selenite Se 75, has been studied in patients with intracranial disease and in cases of localized lesions of bone. Compared with conventional brain-scanning agents, selenite was equally effective in detecting intracranial tumors and yielded fewer abnormal scans in cases of cerebrovascular disease. In the patients with bone lesions, localization of selenite occurred in tumors and uniformly normal scans were obtained in nonneoplastic disease. Because of its relative specificity for tumors, selenite is of value, particularly when used in combination with conventional scanning agents, in the diagnosis of tumors of brain and bone.

Radioisotope scanning has an established place in the diagnosis of focal disease of the brain and in the early detection of metastatic tumors of bone. Among the several radioactive pharmaceutical agents now employed in scanning, however, none is specific for tumors. Sodium pertechnetate Tc 99m, for example, yields a high frequency of abnormal brain scans in patients with cerebrovascular disease and other nonneoplastic lesions.[1] Similarly, abnormal concentration of strontium 85 in the skeleton occurs in a wide variety of localized bone lesions, including traumatic and inflammatory conditions.[2]

One is frequently confronted with the problem of determining whether a lesion demonstrated on a brain scan is a tumor or a cerebral artery infarct, or whether a lesion in the skeleton, detected by roentgenography or by strontium scanning, represents a bone tumor or a nonneoplastic lesion.

Using selenite Se 75 as a scanning agent, we have accurately localized intracranial tumors as well as thoracic and abdominal neoplasms.[3,4] Others have also shown localization of selenite Se 75 in human tumors.[5,6] The possibility that this agent might allow improved diagnostic accuracy in radioisotope scanning for tumors of brain and bone prompted us to compare the results using both selenite and conventional scanning agents in the same patients.

Methods

Fifty-two patients with intracranial disease were studied. There were 28 patients with brain tumors, including 14 with metastatic lesions. All but five cases were proved at operation or at autopsy. In these five patients, the diagnosis of metastatic tumor was established with virtual certainty from the clinical picture, electroencephalography, spinal fluid examination, and in two cases by cerebral arteriography as well.

There were 24 patients with recent cerebrovascular accidents, nearly all representing arterial occlusion. The diagnosis was established at autopsy in two cases, by cerebral arteriography in five others, and by the clinical features, routine laboratory findings, and subsequent course in the remaining 17 cases.

Twenty-five patients with focal bone lesions were studied, including 16 with primary or metastatic tumor and nine patients with nonneoplastic lesions. The basis for the diagnosis in these patients are listed in Table 1. In 11 cases, strontium 85 scans were also performed.

Selenious acid, H_2SeO_3, labeled with ^{75}Se was obtained from commercial suppliers. Specific activity ranged from 20 to 60 mc/mg of selenium. The physical half-life of ^{75}Se is 120 days. The radionuclide emits γ and x rays. There is no β emission. Before administration, the selenious acid was con-

From the Radioisotope Service, Veterans Administration Hospital, and the Radioactivity Research Center, University of California, San Francisco Medical Center.

Reprint requests to Veterans Administration Hospital, 42nd Ave and Clement St, San Francisco 94121 (Dr. Cavalieri).

AEC 7

verted to sodium selenite Se 75 as described previously.[4] The isotope remains in the selenite form for at least two months, provided the solution is kept at or below pH 6 and refrigerated during storage.

Scans were done routinely at intervals of one to six days following intravenous injection of selenite Se 75 in a dose of 4μc/kg of body weight. A commercial photo-scanner was used, with a 3-inch detector and a 19-hole focusing collimator.

The window of the pulse-height analyzer was set between 249 and 289 kev. The scanning speed was 45 or 60 cm/min depending upon the counting rate.

Preliminary brain scans were performed either with chlormerodrin Hg 197 (four hours following a dose of 10μc/kg of body weight) or with sodium pertechnetate Tc 99m (one hour following a dose of 100μc/kg). Routine bone scans were made at intervals from 48 to 96 hours following administration of 100μc strontium nitrate Sr 85. The bladder and bowels were emptied before the bone scans were performed.

Results

Brain Tumors.—Figure 1 compares the results obtained with ^{99m}Tc and ^{75}Se in a patient with a large meningioma. Although the lesion is visible in both scans, there is greater contrast between the tumor and the normal vascular structures of the head in the scan made after administration of selenite Se 75 than in that made after administration of technetium Tc 99m. This is at least partly due to the longer interval between the injection of the drug and the performance of the scan in the case of ^{75}Se. In general, the counting rate over tumors remains relatively unchanged while that over the background areas decreases with time following administration of selenite Se 75.

Table 2 summarizes the results in 28 patients with brain tumor. All but two patients in this group showed localization with both ^{75}Se and the conventional agents (^{99m}Tc or ^{197}Hg). Both falsely normal scans were obtained in patients with well-differentiated astrocytoma. In these two cases, neither ^{75}Se nor the conventional agent detected the lesion. In all 14 cases of metastatic disease, the lesions were localized by both agents.

Cerebrovascular Lesions.—Among 24 patients with recent cerebrovascular accidents, a scan made after selenite Se 75 was administered was abnormal in five patients, all of whom had abnormal scans with the conventional agent as well. Nineteen of these 24 patients, on the other hand, yielded abnormal scans after technetium Tc 99m or chlormerodrin Hg 197 was given (Table 2). Figure 2 shows the results in a patient with a recent occlusion of the right middle cerebral artery, eventually proven by arteriography. The scan made four hours after administration of chlormerodrin Hg 197 is unequivocally abnormal. The scan made four hours after selenite Se 75 was given is only weakly abnormal, and that made 24 hours after the latter



1. Meningioma. Left lateral views obtained after administration of technetium Tc 99m (*top*) and selenite Se 75 (*bottom*). Latter scan was done 24 hours after drug was given.

Table 1.—Results of Bone Scans Performed With Selenite Se 75 and Strontium Sr 85

Lesion	No. of Cases	No. Abnormal/No. Scanned: Selenite Se 75	No. Abnormal/No. Scanned: Strontium Sr 85	Basis of Diagnosis
Tumors				
Osteogenic sarcoma (spine)	[illegible]	[illegible]		Biopsy
Chondrosarcoma (pelvis)	1	0/1		Biopsy
Metastatic (spine)	5	5/5	2/2	Clinical & x-ray findings
(pelvis)	3	3/3	2/2	Clinical & x-ray findings
(scapula)	2	1/1		Autopsy
(rib)	2	1/1		Biopsy
(femur)	1	1/1	1/1	Biopsy
Total	14	13/15	5/5	
Nonneoplastic lesions				
Compression fracture (spine)	3	3/3	2/2	Clinical & x-ray findings (osteoporosis); biopsy in one case
Osteomyelitis	3	0/4	2/3	Biopsy proven in three cases
Gouty arthritis (knee)	1	0/1	1/1	Clinical & x-ray findings (lytic lesion)
Total	9	0/9	5/6	



2. Occlusion of right middle cerebral artery with onset of clinical symptoms 16 days prior to study. Scan made four hours after chlormerodrin Hg 197 was given (*top*), four hours after selenite Se 75 was given (*middle*), and 24 hours after selenite Se 75 was given (*bottom*). Note that scan made after administration of chlormerodrin Hg 197 is definitely abnormal, that made four hours after administration of selenite Se 75 is faintly abnormal, and that made 24 hours after selenite Se 75 was given is normal.

Table 2.—Results of Brain Scans With Both Selenite Se 75 and a Conventional Agent (^{197}Hg or ^{99m}Tc)

Diagnosis	No. of Patients Scanned by Two Agents	No. Abnormal/No. Scanned		
		Selenite Se 75	Chlormerodrin Hg 197	Sodium Pertechnetate Tc 99m
Primary tumors	14	12/14	8/9	4/5
Metastatic tumors	14	14/14	12/12	2/2
Total	28	26/28	20/21	6/7
Cerebravascular lesions	24	5/24	15/19	4/5

drug was given is normal. All of the scans in this patient were performed within a period of 48 hours.

In general, scans made after selenite Se 75 was given, which were "abnormal" in cases of vascular disease, showed less radioactivity over the lesion than over background areas of the face. Furthermore, they tended to become less abnormal when repeated 48 or 72 hours after administration of the drug. The optimal interval between the injection of selenite Se 75 and brain scanning was found to be 48 hours.

Bone Tumors.—Of 16 primary and secondary tumors within bone, all but one were visualized accurately with selenite Se 75 (Table 1). The falsely normal scan occurred in the case of a chondrosarcoma of the ischium. Biopsy of this tumor showed a large amount of cartilage and relatively few cells. All of the metastatic tumors were visualized with ^{75}Se; five of these were also studied with ^{85}Sr and all showed localization. Figure 3 shows scans made after administration of selenite Se 75 and strontium nitrate Sr 85 to a patient with a tumor of the sacrum, metastatic from the lung. In general, the best results in bone scanning were obtained at intervals from three to five days following administration of selenite Se 75.

Nonneoplastic Lesions of Bone.—As controls, nine patients with various types of nonmalignant lesions of bone were studied. None showed significant uptake of selenite Se 75. In contrast, five out of six of these patients yielded abnormal scans with strontium nitrate Sr 85 (Table 1). The results in a patient with an osteomyelitis of the distal part of the femur are shown in Fig 4.

Comment

The results demonstrate that selenite Se 75 better differentiates between brain tumors and vascular lesions than either sodium pertechnetate Tc 99m or chlormerodrin Hg 197. The latter agents and ^{75}Se were equally effective in localizing brain tumors. Among patients with cerebrovascular accidents, the conventional agents yielded abnormal scans in nearly 80% (19 of 24 cases), but scans made after administration of selenite Se 75 were abnormal in only 21% (five of 24 cases). Thus, while the tumor-specificity of selenite Se 75 is significant, it is not absolute.

Similarly, the differentiation of bone tumors from nonneoplastic lesions was more successful

3. Scan made 48 hours after administration of strontium nitrate Sr 85 (*left*) and five days after selenite Se 75 was given (*right*) to patient with carcinoma of sacrum, metastatic from lung. Tumor is visualized equally well with both agents. Note uptake of ^{75}Se in kidneys, a normal phenomenon.

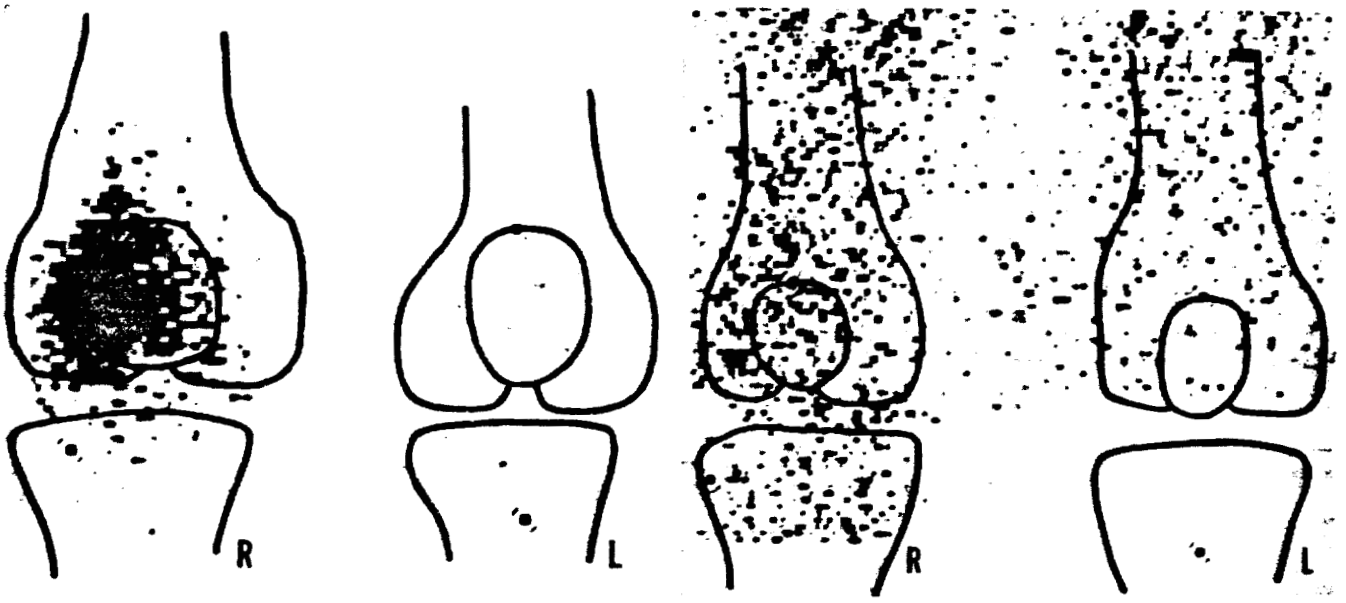

4. Scans made after strontium nitrate Sr 85 was given (*left*) and selenite Se 75 (*right*) in patient with osteomyelitis of femur. Latter scan was made first, three days after selenite Se 75 was given; then scan at left was performed four days after administration of strontium.

with selenite than with strontium. Among 16 cases of bone tumor, all but one yielded an abnormal scan with selenite. None of the nine patients with nonneoplastic lesions showed significant uptake of ^{75}Se. The occurrence of strontium uptake in various nonneoplastic lesions of bone, already pointed out by others,[2] was again demonstrated in this small series of cases.

Although a full explanation for the relatively high tumor-specificity of selenite is not yet possible, one important factor may involve the mechanism of uptake. Recent studies have shown that selenite is incorporated into human leukocytes in vitro by an active metabolic process.[7] It is likely that a similar mechanism operates in vivo in neoplastic cells. Thus, selenite would accumulate in a cellular lesion, such as a brain tumor, and tend not to accumulate in an acellular area, such as a cerebral artery infarct. Other agents, particularly sodium pertechnetate Tc 99m, which diffuse passively into diseased areas of brain, could not allow differentiation among various types of lesions.

Another possible factor may be the interval between injection of the agent and the performance of the scan. For an agent such as selenite which remains in a tumor for a prolonged period, during which radioactivity in the blood declines, the longer the interval, the greater the contrast in radio-

1160614

activity between tumor and normal vascular areas of the head. In this respect, ^{75}Se has an inherent advantage over short-lived radionuclides, such as ^{99m}Tc, by permitting serial scanning for several days following injection of a single dose.

The relative nonspecificity of strontium for various kinds of bone lesion has been attributed to the fact that strontium uptake in the skeleton is a function of the rate of new bone formation or mineral accretion in the area.[2] Thus, localization by strontium of a metastatic tumor depends on the reaction of the bone to the lesion. The concentration of selenite, in contrast, seems to depend upon the cellular composition of the lesion itself. It may be relevant to note that the only falsely normal scan made after administration of selenite Se 75 to our patients with bone tumors occurred in a relatively acellular chondrosarcoma. Other factors, such as blood supply to the lesion, may also be important.

The cumulative radiation dose to the patient from a single dose of selenite Se 75 (4μc/kg) has been estimated at 1.1 rads to the whole body, 4.8 rads to the liver, and 6.1 rads to the kidneys, into which organs selenite is normally concentrated.[4] Because of the long effective half-life (45 days) the average dose-rate is only 0.018 rads/day, whole body exposure. The dose to the skeleton is no greater than that to the whole body. We consider this radiation dose to be permissible especially in view of the diagnostic advantages offered by this agent. The chemical toxicity is negligible. A single dose of selenite Se 75 contains less than 0.02 mg selenium, which is less than the amount taken in each day by humans living in areas without selenium.[8]

Selenite Se 75 should not be confused with selenomethionine Se 75, an amino acid analogue used mainly for pancreas scanning. The two compounds differ both in biochemical properties and in tissue specificity.[9]

Our experience to date indicates that selenite Se 75 can provide improved diagnostic accuracy in the differentiation between brain tumors and cerebrovascular lesions and in the identification of bone tumors. Other advantages of this agent include the following: ready availability, low cost, radiochemical stability, long "shelf-life," and a convenient γ-energy spectrum for scanning with present-day instruments. Because of its relatively prolonged retention in the body, we do not recommend that selenite Se 75 be employed in brain scanning *in place* of short-lived radionuclides but, rather, that it be used as a secondary scanning agent to improve the diagnostic accuracy of the procedure. The idea that the combined use of two radionuclides with different tissue-specificities may increase the diagnostic value of scanning has also been proposed by Tow and Wagner.[10] These authors suggested the use of sodium pertechnetate Tc 99m and strontium 87m to differentiate lesions in the brain from localized disease of the skull.

Selenite appears to be especially promising in the differential diagnosis of bone lesions. The results of the present, limited study demonstrate its effectiveness in localizing metastatic tumors. Further experience is needed in order to define more precisely the capabilities and limitations of this agent.

Generic and Trade Names of Drugs

Technetium Tc 99m—*Neimotec, Pertgen-99m, Technekow-CS Generator, Technekow Generator, Technetope.*

Sodium pertechnetate Tc 99m—*Pertscan-99m, Neipertec 99m.*

Chlormerodrin Hg 197—*Neohydrin-197.*

Selenomethionine Se 75—*Sethotope.*

Strontium nitrate Sr 85—*Strotope.*

References

1. Witcofski, R.L.; Maynard, C.D.; and Roper, T.J.: A Comparative Analysis of the Accuracy of the Tc 99m Pertechnetate Brain Scan: Followup of 1,000 Patients. *J Nucl Med* 8:187-196 (March) 1967.

2. DeNardo, G.L., and Volpe, J.A.: Detection of Bone Lesions With the Strontium 85 Scintiscan, *J Nucl Med* 7:219-236 (March) 1966.

3. Cavalieri, R.R., and Scott, K.G.: Selenite Se 75 as a Brain Scanning Agent, *J Nucl Med* 6:351 (May) 1965.

4. Cavalieri, R.R.; Scott, K.G.; and Sairenji, E.: Selenite (^{75}Se) as a Tumor-Localizing Agent in Man, *J Nucl Med* 7:197-208 (March) 1966.

5. Esteban, J.; Lasa, D.; and Perez-Modrego, S.: Detection of Cartilaginous Tumors With Selenium 75, *Radiology* 85:149-150 (July) 1965.

6. Spencer, R.P., et al: Uptake of Selenomethionine by Mouse and Human Lymphomas, With Observations on Selenite and Selenate, *J Nucl Med* 8:197-208 (March) 1967.

7. Cavalieri, R.R., et al: Uptake of Selenite Labelled With Selenium 75 by Human Leucocytes in Vitro, *Nature* 215:1091-1092 (Sept 2) 1967.

8. Rosenfeld, I., and Beath, O.A.: *Selenium: Geobotany, Biochemistry, Toxicity, and Nutrition,* New York: Academic Press, Inc., 1964, pp 291-292.

9. Sternberg, J., and Imbach, A.: Metabolic Studies With Seleniated Compounds: II. Turnover Studies With ^{75}Se Methionine in Rats, *Int J Appl Radiat* 18:557-568 (Aug) 1967.

10. Tow, D.E., and Wagner, H.N., Jr.: Scanning for Tumors of Brain and Bone: Comparison of Sodium Pertechnetate Tc 99m and Ionic Strontium 87m, *JAMA* 199:610-614 (Feb 27) 1967.