REPOSITORY DOE-FORRESTAL
COLLECTION MARKEY FILES
BOX No. 3056
NON-RADIOACTIVE AIR
FOLDER POLLUTION



704765

# Chronic Toxicity of Nitrogen Dioxide

## II. Effect on Histopathology of Lung Tissue

*William H. Blair, BS; Mary C. Henry, PhD; and Richard Ehrlich, PhD, Chicago*

mice 0.5 ppm $NO_2$

**Mice were exposed to 0.5 ppm nitrogen dioxide ($NO_2$) for 6, 18, and 24 hours daily. The lung alveoli were expanded in all mice exposed to $NO_2$ from three to 12 months, with the highest degree of involvement at 12 months; thus the number of expanded alveoli appeared to increase with exposure time. The general impression was of early bronchiolar inflammation with reduction of distal airway size and a concomitant expansion of alveoli. The overall lesions appeared to be consistent with the development of early focal emphysema. Examination of the heart, liver, kidney, and spleen did not reveal any unique pathology. Mice exposed to $NO_2$ and challenged with *Klebsiella pneumoniae* exhibited a marked reduction in functional lung tissue.**

focal effects

1 year at 24 hrs/day @ 0.5 ppm
early mild focal emphysema
loss of resistance to pneumonia infection

Submitted for publication June 14, 1968; accepted Aug 26.

From the Life Sciences Research Division, IIT Research Institute, Technology Center, Chicago.
Reprint requests to IIT Research Institute, 10 W 35th St, Chicago 60616 (Dr. Ehrlich).

STUDIES reported in the previous paper[1] indicate that exposure to 0.5 ppm of nitrogen dioxide ($NO_2$) for three months or longer has a significant effect on the resistance of mice to bacterial pneumonia. The effect was demonstrated by enhanced mortality after the challenge with airborne *Klebsiella pneumoniae* and by reduced clearance rates of the infectious agent from the lungs. To further study the effects of chronic exposure to 0.5 ppm of $NO_2$, histopathological examinations of tissues obtained from the various experimental groups of mice were performed.

### Methods

Randomly selected mice were killed by cervical decapitation within two hours after termination of $NO_2$ exposure, which was 1, 3, 6, 9, and 12 months. Tissues were collected from up to four mice, representing the following $NO_2$ exposure conditions: (1) 24 hours, mice exposed to $NO_2$ 24 hours each day, seven days a week; (2) 18 hours, mice exposed to $NO_2$ 18 hours each day, seven days a week; (3) six hours, mice exposed to $NO_2$ six hours each day, seven days a week; (4) control mice maintained in ambient air, seven days a week.

Additional groups of mice included those only challenged with airborne *K pneumoniae* and those challenged with the infectious agent immediately after tremination of the $NO_2$ exposure. To obtain the tissues, surviving mice challenged with *K pneumoniae* were killed 14 days after the challenge.

For the histopathological examination, lung, heart, thymus, spleen, liver, and kidney tissues were used. The tissues were fixed in Bouin's



1006211



Fig 1.—Lungs of mice after three months exposure to 0.5 ppm of $NO_2$. **Top left,** control animal; **top right,** six hour a day exposure; **bottom left,** 18 hour a day exposure; **bottom right,** 24 hour a day exposure (× 100).

solution by direct immersion, embedded in paraffin, and cut on a rotary microtome at 8μ. The slides were deparaffinized in xylene and were stained with hematoxylin and eosin. Microscopic observations were made at low (× 100) and high (× 400) magnifications. Photomicrographs were taken with a Polaroid copy stand utilizing a microscope adapter, or with a 35-mm camera on a micro-attachment.

## Results

**Control Mice.**—Observation of the lung tissue of control mice after holding at ambient conditions for up to 12 months, revealed moderate pneumonitis characterized by peribronchial infiltration with lymphocytes. The bronchioles were generally lined with a single layer of ciliated cuboid epithelium. There was no indication of inflammation, and the terminal airways were patent. In general, the lung structure appeared to be normal with delicate alveolar septa and relatively uniform distribution of alveoli. Some minimal septal breakage was seen, but the alveoli did not appear to be expanded.

In general, the findings in control mice were consistent, as evidenced by the development of pneumonitis, with advancing age. There was no evidence of bronchiolar obstruction or emphysema, other than the moderate expansion of alveoli in areas of septal breakage.

**Mice Exposed to 0.5 ppm $NO_2$.**—*Three Months Exposure.*—Pneumonitis as evidenced by peribronchial and interstitial alveolar lymphocytic infiltration was observed in mice exposed to $NO_2$ for six hours each day. The bronchiolar epithelium was cuboid and appeared normal in the mice exposed six and 18 hours each day, while obstruction of some respiratory bronchioles with an acidophilic substance was evident in the group exposed 24 hours each day. In these areas, the epithelium of the bronchioles was of a

3 mo
@ 6
18
24 hrs/day



1006212

Fig 1.—Lungs of mice after six months exposure to 1.0 ppm of $NO_2$. Top left, control animal; top right, six hour a day exposure (× 100). Center left, 13 hour a day exposure; center right, 24 hour a day exposure (× 100). Bottom, bronchiole-alveolar junctions; note open airway in control animal (left), whereas in the 13 hour a day exposure (right) the junction is filled with cellular debris (× 400).

columnar shape and devoid of cilia. Distal to the obstructed areas the alveoli were markedly expanded with concomitant thinning of the walls.

Alveolar expansion without obstruction was also seen in mice exposed six and 13 hours each day, while alveolar septal breaks were seen in all three experimental groups. Of the three $NO_2$ exposures, it appeared that the group exposed 24 hours each day showed the highest degree of bronchiolar inflammation and alveolar expansion (Fig 1).

*Six Months Exposure.*—Pneumonitis, characterized by peribronchial and interstitial lymphocytic infiltration was evident in all mice exposed to $NO_2$ for six months. The



6mo

1006213



Fig 3.—Lungs of mice after 12 months exposure to 0.5 ppm of $NO_2$. Top left, control animal; top right, six hour a day exposure; bottom left, 18 hour a day exposure; bottom right, 24 hour a day exposure (× 100).

reaction was most severe in mice exposed to $NO_2$ for 24 hours each day.

The bronchial mucosa was markedly inflamed in all three experimental groups, with surface erosion and loss of cilia. In many areas the bronchiole-alveoli junction was either totally or partially blocked with cellular debris. In some areas of the lungs of the mice exposed 24 hours each day, the epithelium in the bronchioles was of a high columnar configuration, and the surface was coated with a mucoid-like material. In the other two experimental groups, the bronchiolar epithelium was cuboid.

Alveolar expansion and septal breakage was evident in all three groups exposed to $NO_2$ but did not appear to progress from the three-month exposure period. The alveolar expansion appeared to be more evident in the areas of bronchiolar obstruction. It appeared that after six months exposure to 0.5 ppm of $NO_2$, the bronchiolar inflammation was present in all three experimental groups, while after three months exposure it was evident only in the mice exposed 24 hours each day. The extent of airway obstruction increased, while the degree of dilation of the alveoli did not change significantly (Fig 2).

*Nine Months Exposure.*—Pneumonitis was still seen in all three groups of mice exposed to $NO_2$, but was decreased in the degree of reaction. The alveolar expansion seen after three and six months of exposure to $NO_2$ was not as apparent in the mice exposed for nine months. The alveolar septal walls appeared to be thicker than those in control mice, or in mice exposed to $NO_2$ for the shorter periods of time. It appeared that after nine months exposure, minimal inflammation and expansion of alveoli occurred in all three experimental groups.

*Twelve Months Exposure.*—Mice exposed to 0.5 ppm of $NO_2$ for six hours each day showed moderate pneumonitis. The groups exposed 18 and 24 hours each day showed a

9 mo

12 mo



1006214

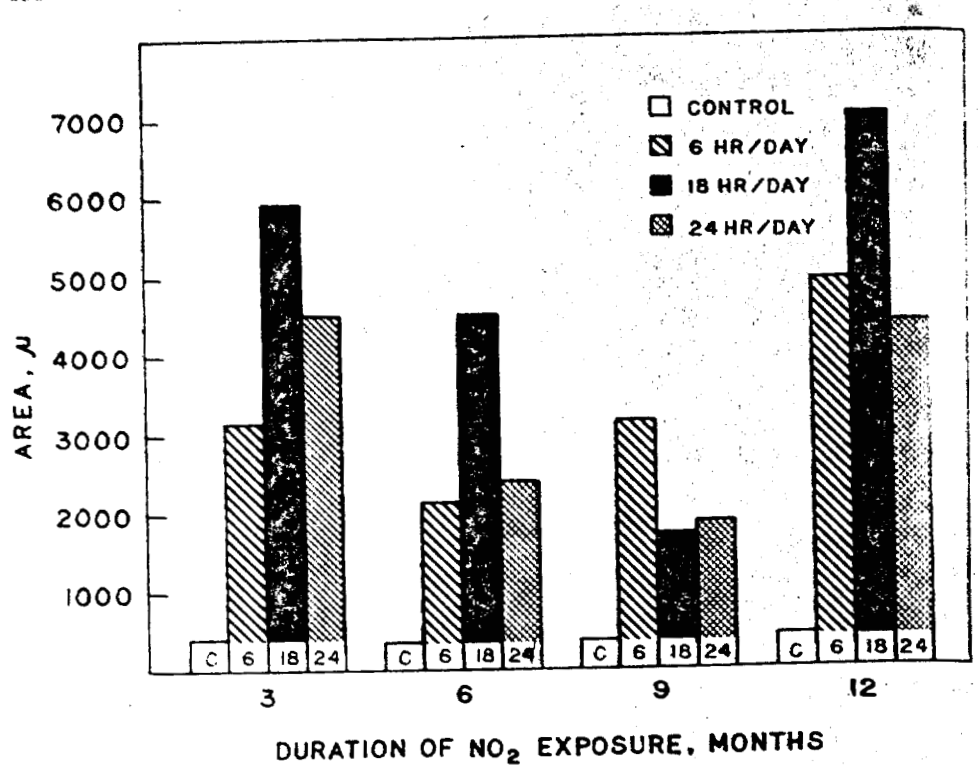


Fig 4.—Size of alveoli of lungs of mice exposed to 0.5 ppm of $NO_2$.

severe pneumonitis, characterized by widespread interstitial and peribronchial lymphocytic infiltration. Some lung lobes of the mice exposed 24 hours each day were in the stage of gray hepatization of pneumonia, with exudate in the alveoli and infiltration of polymorphonuclear leukocytes. There was evidence of bronchiolar epithelial erosion in all three experimental groups, but the terminal airways appeared to be unobstructed. Alveolar expansion and septal breakage appeared to progress with septal wall thinning. Lung alterations after 12 months of $NO_2$ exposure are illustrated in Fig 3.

**Size of Alveoli.**—In order to further illustrate the effect of $NO_2$ exposure, the size of alveoli was measured. To obtain this data, three different areas of lungs were observed in each animal, and in each area five alveoli were selected at random for measurement with an ocular micrometer. To obtain the area size, the longest diameter and its right angle dimension were measured and multiplied (length × width). The values for the 15 measurements were averaged and plotted (Fig 4). While it must be noted that the averages do not represent quantitatively the whole lung structure, they do relate to the qualitative and comparative average alveolar size. To quantitate this method more sophisticated planographic techniques, such as paper macrosection, will have to be used. It can be readily seen that a marked increase in alveolar area was present in mice exposed to 0.5 ppm of $NO_2$, as compared to control mice. The increase in size was largely related to alveolar expansion and not to the septal breakage.

**Mice Challenged With K Pneumoniae.**—The overall picture of mice challenged with *K pneumoniae*, but not exposed to $NO_2$, was of mild to severe pneumonitis associated with interstitial edema, cellular infiltration, and, in some cases, bronchitis. There was no clear indication of bronchiolar obstruction or abnormal expansion of alveoli.

In the group of mice exposed to 0.5 ppm of $NO_2$ and the *K pneumoniae*, it appeared that the following three distinct lesions were present: (1) pneumonitis characterized by



1006215

peribronchial infiltration with lymphocytes which was present in both the experimental and control groups; (2) varying degrees of pneumonia which appeared similar to the group exposed to *K pneumoniae;* and (3) alveolar expansion with bronchiolitis and airway blockage; the alveolar expansion appeared to be similar to that observed in mice exposed to $NO_2$ only.

The bronchiolar lesions were characterized by inflammation, proliferation, epithelial desquamation, and terminal airway blockage. With the exception of epithelial proliferation the lesions were similar to those observed in mice exposed to $NO_2$ only. In areas of lung involved with the pneumonic process the lesion appeared to be more severe in the mice exposed to $NO_2$. Also of interest is the observation that the pneumonic process did not appear to be involved in areas with markedly dilated alveoli.

Of the other tissues examined, no unique response to $NO_2$ was noted, and any abnormalities in cell infiltration associated with mice exposed to *K pneumoniae,* were consistent with the experimental conditions induced.

## Comment

A brief literature review has shown several studies on the effects of $NO_2$ on lung structure. Gray et al[2] studied the chronic toxicity of 9 to 14 ppm of $NO_2$ in rats, and reported that a six-week exposure resulted in an inflammatory condition of the respiratory tract consisting of rhinitis, tracheitis, and pneumonitis. After eight or more weeks of exposure, the inflammatory process subsided and localized areas of emphysema were observed. Additional studies[3] with guinea pigs exposed to 4 ppm of $NO_2$ for six months did not disclose any evidence of pathology attributable to the $NO_2$.

Harrold et al[4] reported that, based on a 6 hour a day, five days a week exposure, the threshold of harmful effects of nitrous oxide was above 70 ppm. Studies by Flurry and Zeisek[5] indicated that exposure to an average of 117 ppm of $NO_2$ for six to seven hours had no effects on cats, rabbits, or mice. Wagner et al[6] studied the effect of $NO_2$ on dogs, rabbits, guinea pigs, rats, hamsters, and mice. The animals were daily exposed to 5 ppm of pure $NO_2$ for up to 18 months. They did not observe any morphological effects related to the exposure.

Freeman and Haydon[7] exposed rats continuously to 25 and 100 ppm of $NO_2$. Within 24 hours, rats exposed to 100 ppm $NO_2$ began to die with acute pulmonary edema and focal hemorrhages in the lung. Exposures to 25 ppm $NO_2$, up to 180 days, resulted in death in 11 of 15 rats. Upon killing the rats, the lungs exhibited hypertrophy and hyperplasia of the bronchial and bronchiolar epithelium, and an increase in goblet cells. These authors[7] also noted variations in the size of the alveolar ducts and alveoli, with many of them appearing larger than control rats. In rats exposed to 25 ppm $NO_2$, pathologic alterations of the lung tissue were not seen earlier than five to six weeks, while death due to respiratory failure occurred after 20 to 22 weeks of exposure.

The basic lesion was narrowing of the air channels at the junction of the terminal bronchioles and alveolar ducts. This narrowing resulted from proteinaceous material and aggregates of macrophages in the bronchioles and lengthening of the bronchiolar epithelium from a cuboid to a columnar form. Also, the cilia were overlaid with mucous secreted by activated goblet cells. Pulmonary tissue was free of dead or dying cells, visible fluid, and leukocytic reaction suggestive of chronic infection.[8]

In a further study, Freeman and Furiosi[9] exposed rats to 4 ppm $NO_2$ for 16 weeks. They noted that the basic lesions were associated with narrowing of the air channel at the junction of the terminal bronchiole and the alveolar ducts. After 16 weeks exposure to 0.8 ppm $NO_2$, no obvious pathology was seen.

We have exposed mice to 0.5 ppm of $NO_2$ and have studied the sequential alterations of lung morphology after 3 to 12 months exposure. We have also studied the interactive effects of challenge with *K pneumoniae* by the respiratory route after the $NO_2$ exposures. A consistent finding in control untreated mice was pneumonitis characterized by peribronchial lymphocytic infiltration. Varying degrees of pneumonitis were also seen in all of the experimental groups of mice. This observation is consistent in mice and is routinely observed in most laboratories.



100b21b

In experimental mice exposed to $NO_2$, inflammation of the bronchioles, surface erosion of the epithelium, and blockage of the bronchiolar-alveolar junction was observed. The alveoli were expanded in all mice exposed to $NO_2$ from 3 to 12 months, with the highest degree of involvement at 12 months; thus the number of expanded alveoli appeared to increase with exposure time. In addition, the general impression was of early bronchiolar inflammation with reduction of distal airway size and a concomitant expansion of alveoli after which the terminal airways did not appear occluded, but the alveoli expansion still progressed. The overall lesions appeared to be consistent with the microscopic development of early focal emphysema.

Examination of heart, liver, kidney, and spleen tissues did not reveal any unique pathology.

In mice challenged with *K pneumoniae* only, pulmonary atelectasis, leukocytic infiltration, edema, and alveolar destruction was seen. In most cases, the mice were in the gray hepatization stage of pneumonia. In mice exposed to $NO_2$ and challenged with the infectious agent, superimposed on the pulmonary pneumonitis, were varying stages of pneumonia, bronchiolar inflammation, and alveolar distension.

The fact that the primary lesions of pneumonia do not appear in the markedly dilated alveoli suggest that reduction of functional tissue by $NO_2$ treatment could enhance the pathogenic effects of challenge with *K pneumoniae*. This is supported by the mortality data of mice exposed to $NO_2$ and challenged with *K pneumoniae*.

The induction of alveolar distension in mice exposed to 0.5 ppm $NO_2$ appears to be the lowest level at which effects were observed in experimental animals. The concurrent pneumonitis normally present in [illegible] of mice could serve as a priming fact[illegible] for the development of alveolar expansion and may account for the enlargement observed upon exposure to this low concentration of $NO_2$. Challenge with *K pneumoniae* appeared to act as an independent pathogenic situation and produced its own type of lesion, ie, atelectasis, leukocytic infiltration, edema, and ultimate scar formation, which further reduces functional lung tissue.

This study was supported by funds provided by the National Air Pollution Control Administration, Department of Health, Education, and Welfare, under contracts SAph 73297 and PH 86-67-30.

In conducting the research reported here, the investigators adhered to "Principles of Laboratory Animal Care" as established by the National Society for Medical Research.

Mrs. Betty Jo Larson assisted in the experimental studies.

## References

1. Ehrlich, R., and Henry, M.C.: Chronic Toxicity of Nitrogen Dioxide: I. Effect on Resistance to Bacterial Pneumonia, *Arch Environ Health* 17:860-865 (Dec) 1968.

2. Gray, E.L.; MacNamee, J.K.; and Goldberg, S.B.: Toxicity of $NO_2$ Vapors at Very Low Levels, *Arch Indust Hyg* 6:20-21 (July) 1952.

3. Gray, E.L.; Goldberg, S.B.; and Patton, F.M.: Toxicity of the Oxides of Nitrogen: III. Effect of Chronic Exposure to Low Concentrations of Vapors From Red Fuming Nitric Acid, *Arch Industr Hyg* 10:423-425, 1954.

4. Harrold, G.C.; Meek, S.F.; and McCord, C.P.: A Chemical and Physiological Investigation of Electric Arc Welding, *J Industr Hyg* 22:347-378 (Oct) 1940.

5. Flurry, F., and Zernik, K.F.: *Schaedliche Gase*, Berlin: Springer Verlag, 1931.

6. Wagner, W.D., et al: Experimental Study of Threshold Limit of $NO_2$, *Arch Environ Health* 10:455-466, 1965.

7. Freeman, G., and Haydon, G.B.: Emphysema After Low-Level Exposure to $NO_2$, *Arch Environ Health* 8:125-128 (Jan) 1964.

8. Haydon, G.B.; Freeman, G.; and Furiosi, N.J.: Covert Pathogenesis of $NO_2$-Induced Emphysema in Rat, *Arch Environ Health* 11:776-783, 1965.

9. Freeman, G., and Furiosi, N.J.: Effects of Continuous Exposure of 0.8 PPM $NO_2$ on Respiration of Rats, *Arch Environ Health* 13:454-456 (Oct) 1966.

Higher the cumulative dose both as to time / day + time longitude

Arch Environ Health—Vol 18, Feb 1969

1006217