Copyright, 1958, by the Society for Experimental Biology and Medicine.
Reprinted from PROCEEDINGS OF THE SOCIETY FOR EXPERIMENTAL BIOLOGY AND MEDICINE, 1958, v98, 553-557

703819

Postnatal Histogenesis and Endocrine Function of Abnormal Testes in the AxC Rat. (24105)

OSCAR VILAR AND ROY HERTZ
Endocrinology Branch, National Institutes of Health, Bethesda, Md.

Deringer and Heston have described the relatively frequent occurrence of multiple abnormalities in the genitourinary tract of the AxC rat(1). In the male the anomalous pattern includes a total absence of kidney and ureter on one side frequently associated with presence on the same side of an atrophic testis which lacks a vas deferens or epididymis. In addition the seminal vesicle, but not the coagulating gland, is absent on the involved side. In this strain of rats varying patterns of this anomalous picture are observed in approximately 20% of all male animals studied(1). Similar patterns of genitourinary abnormality have been described in man by Whitehorn (3) and Longo and Thompson(4).

We wish to report our observations on postnatal development of the abnormal testis in the AxC rat. These studies have indicated that during prepuberal period the testis which is destined to be atrophic in adult life is morphologically and histochemically indistinguishable from the normal testis of comparable age. With onset of puberty the abnormal testis presents its initial deviation from normal developmental pattern, namely complete failure of tubular maturation and spermatogenesis.

Materials and methods. The rats were derived from a highly inbred strain previously described by Heston and Deringer(1). They were kept in metal cages in constant-temperature animal quarters maintained between 76 and 80°F. They were fed Purina stock diet *ad libitum* and provided constant supply of tapwater. Pregnant animals were isolated for delivery and date of birth of all litters recorded daily. All animals were sacrificed by ether at indicated age. Testes which could be expected to be atrophic were identified by occurrence on the same side as the observed absence of vas deferens, kidney, ureter and seminal vesicle. This was most commonly on the right side. The contralateral testis was used as normal control tissue since no instance of bilateral testicular failure has occurred in this colony. All tissues were promptly weighed and fixed for histochemical analysis. The following fixatives and staining methods were employed: I. Bouin's solution; for morphological study, glycogen and mucopolysaccharide. II. Cold alcohol, 80%; for alkaline phosphatase; III. Barnett and Bourne's solution(5); for ascorbic acid; IV. Baker's Formaldehyde(6); for total lipids, cholesterol and silver impregnation; V. Mallory's trichrome stain as modified by Crossman(7); VI. Lillie's allochrome stain(8); VII. Del Hortega's(9) or Gridley's(10) silver impregnation; VIII. Weigert's resorcin-fuchsin(11); IX. McMannus' P.A.S. for glycogen(12) with takadiastase digestion at 37°C for control; also with hyaluronidase digestion to eliminate reaction with some muco-polysaccharide; X. Gomori's method as modified by Kabath and Fursth(13) for alkaline phosphatase; XI. Metachromatic reaction with Azur B and Toluidine Blue O (0.055%, pH 6 and pH 4) and P.A.S. for acid mucopolysaccharides; XII. Sudan (III, IV and Black) for lipids; XIII. Schultz's(14) and Brunswick's methods(15) for cholesterol and cholesterol esters; XIV. Dean and Morse's method(16) for ascorbic acid. Thirty-five abnormal specimens were selected to cover the prepuberal as well as postpuberal and adult period (Table I). In addition, tissues from 65 normal animals at different ages were studied for com-

1001688

REPOSITORY DOE-FORRESTAL
COLLECTION Markey FILES
BOX No. 2 of 6
FOLDER univ. of washington II
(45-1) 1781 ALVIN C. PAULSEN

TABLE I. Weight and Position of Normal and Abnormal Testes in 35 AxC Rats at Various Ages.

Age, days	Abnormal testis		Normal testis	
	Wt, mg	Position	Wt, mg	Position
3	3	abdominal	3	abdominal
5	6.5	"	6.7	"
8	13	"	13	"
9	18	"	16	"
10	19	"	19	"
19	63	"	62	"
24	94	low abd'nal	96	low abd'nal
"	100	" "	100	" "
30	184	abdominal	194	scrotal
38	182	"	330	"
44	440	scrotal	550	"
180	230	abdominal	1250	"
"	500	scrotal	1600	"
"	450	"	1440	"
"	98.2	"	1450	"
"	170.5	"	1250	"
"	217.5	"	1560	"
"	192	abdominal	1410	"
"	375	scrotal	1390	"
"	490	"		*
"	255	"		*
"	†	abdominal		*
"	320	scrotal		*
"	380	"		*
"	†	abdominal	1350	*
"	470	scrotal	1235	*
"	570	"	1320	*
"	660	"	1280	*
"	540	"	1415	*
"	500	"	1310	*
"	†	abdominal	1290	*
"	520	scrotal	1345	*
"	540	"	1545	*
"	430	"		*
"	370	"		*

* Scrotal testis extirpated 6 to 11 mo before.
† Hydrotestis.

parison. In 16 abnormal adult animals, the normal testis had been surgically removed 6 months before autopsy to determine whether the remaining atrophic testis could maintain the prostate and seminal vesicle of the host. To ascertain whether or not absence of vas deferens plays a critical role in abnormal development of the anomalous testis, one vas deferens was surgically removed from each of 10 normal animals when they were 22 to 25 days old (Table II). This operation was performed under magnification so that no traumatic interference with testicular blood supply would result. These animals were then sacrificed at 61 to 64 days of age and the testes of operated side and of unoperated side were then compared by technics listed above.

Results. Histological and histochemical review of the chronologically distributed specimens permits one to reconstruct the histogenetic process ultimately leading to the pathological state found in the adult. Thus, close comparison of specimens of normal and abnormal side from rats up to 30 days of age reveals essentially the same picture in both sides. Up to this stage, there is a normal progression in either testis and it is noteworthy that no significant discrepancy in testicular weight is noted. In earlier specimens up to 10 days of age (Fig. 11) the tubular structures lack a lumen and are represented by solid cords consisting of two types of cells: (a) small cells with a sharply defined nuclear membrane, coarse chromatin granules and a distinct nucleolus; they are located in the periphery of the cord and exhibit weakly positive nuclear reaction for alkaline phosphatase and negative cytoplasmic reaction for alkaline phosphatase, ascorbic acid and lipids, and (b) larger cells, oval or round, with nuclei containing 2 or 3 nucleoli and presenting a negative reaction for lipids and ascorbic acid but positive alkaline phosphatase response in both nucleus and cytoplasm. The latter cells become less abundant as development proceeds and are nearly absent by 9th day. The cellular cords lack a definite limiting membrane but are closely surrounded by interstitial connective tissue. The latter is made up of a network of thin reticular fibres, many mesenchymal cells and immature fibroblasts which are dispersed in a highly eosinophilic amor-

TABLE II. Effect of Extirpation of Vas Deferens on Testis Weight of 12 Rats.

No.	Age at extirpation of vas deferens (days)	Age at autopsy (days)	Testicular wt (mg)	
			Left	Right
1	22	64	1007	1005
2			710	730
3			1120	1112
4			550	520
5			1130	1115
6	25	61	1100	1150
7			1000	1000
8			1050	1000
9			1100	1050
10			1030	1020
11	Not operated	64	1350	1008
12			1000	990

1001687

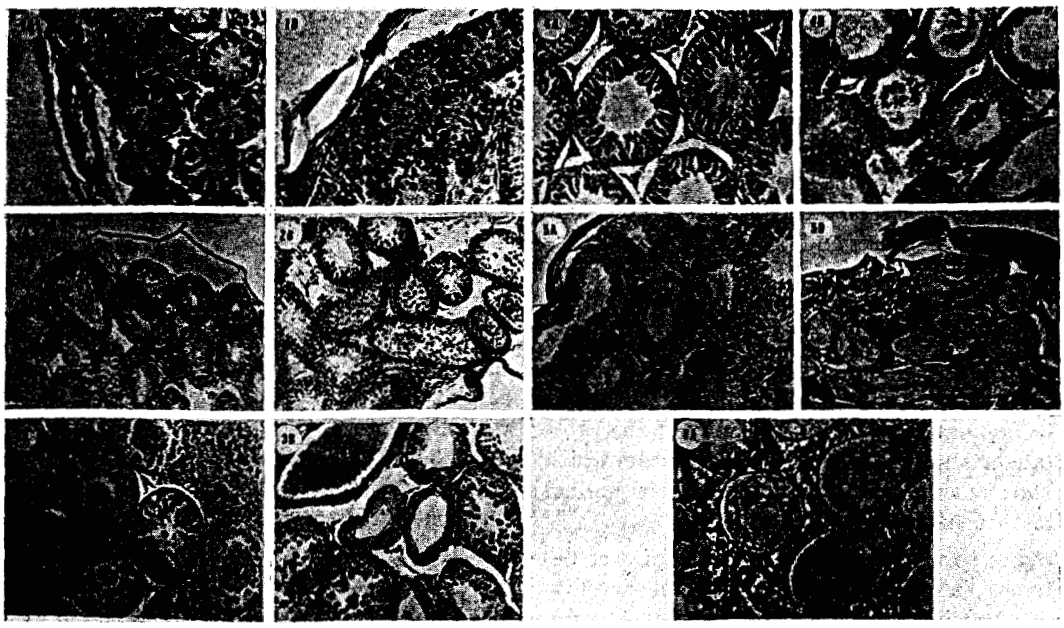

FIG. 1. Testes from 8-day-old AxC rat (× 250). a. Normal testis. b. Testis from abnormal side.
FIG. 2. Testes from 19-day-old AxC rat (× 125). a. Normal testis. b. Testis from abnormal side.
FIG. 3. Testes from 30-day-old rat (× 125). a. Normal testis. b. Testis from abnormal side.
FIG. 4. Testes from 38-day-old AxC rat (× 125). a. Normal testis. b. Testis from abnormal side.
FIG. 5. Testes of adult AxC rat. a. Normal testis. b. Abnormal testis (× 70).
FIG. 6. Abnormal testis of adult AxC rat (× 125).

phous ground substance which stains a deep blue with Azur B and is strongly positive to P.A.S. In the interstices there are also found small groups of oval cells which resemble adult Leydig cells, and possess acidophilic cytoplasm which stains positively for alkaline phosphatase, lipids and cholesterol.

Between 19 and 24 days the respective testis weights from each side continue to be equal. The tubular diameter increases and there are clear lumina formed (Fig. 2). The tubular wall is well formed and the basal membrane responds positively to P.A.S. and to stain for alkaline phosphatase. The surrounding reticular fibres have now become highly condensed. The tunica propria consisting of a reticular net and numerous fibroblasts are noted. Within the tubules, the more embryonic cells are now replaced by distinct Sertoli cells, spermatogonia, and spermatocytes. These elements in both testes present an entirely normal appearance and stain positively for lipids, ascorbic acid and alkaline phosphatase. The interstitial spaces are now larger and present numerous fibroblasts in varying stages of maturation. Immature and mature Leydig cells appear entirely normal in both testes and are now enmeshed in a less dense reticular network.

In the 30- to 38-day period distinct weight differences are noted between testis of abnormal and normal side and the pathological features of the smaller gonad clearly emerge (Fig. 3 and 4). The essential deficiency is a progressive failure of normally evolving tubular maturation and spermatogenic function, whereas the interstitial cell development proceeds normally. After 44 days of age and on into advanced adult life the deficient gonad presents all features of the definitive syndrome (Fig. 5, 6). There is total failure of spermatogenic function and the atrophic tubules present a distinctly thickened wall of reticular, elastic, and collagen fibres. The abun-

1001688

dant homogeneous intertubular amorphous substance which stains red with eosin, light blue with azure, and pink with P.A.S. also resists hyaluronidase and diastase digestion. Hence it appears to be comparable to the interstitial fluid found normally in immature and puberal testes. Leydig cells are present in normal numbers and present all normal histochemical reactions for cells of this type. However, both vascular sclerosis and proliferation of normal fibroblasts are seen.

The hormonal functional capacity of Leydig cells of the atrophic testis is also shown to be normal by lack of atrophy of the prostate or seminal vesicles in 16 adult rats which had undergone extirpation of their normal testis 6 months before autopsy.

Moreover, there was no effect of vas deferens extirpation upon subsequent development of the normal testis of rats of this strain. This indicates that absence of the vas deferens in the case of anomalous testis is probably not a critical factor in development of the abnormal state.

Specificity of the various technics used, has been extensively discussed(8,17,18,19,20). It is especially noteworthy that by all these histochemical criteria the uninvolved testis in the AxC rat may be considered entirely normal. Moreover, the abnormal testis shows no appreciable deviation from the normal pattern of development until the pubertal stage is reached. It would appear then that this anomaly represents a delayed somatic expression of a genetically determined defect.

The anatomical position of each of the testes of each animal was recorded at autopsy. Since the inguinal canal in the rat remains open throughout life these data are of dubious significance except as an indication that scrotal or abdominal position of the testes was totally unrelated to the histological picture in any given case.

Association of a testicular defect with such other defects as absence of kidney, ureter, vas deferens, and seminal vesicle, reflects multiple manifestations of anomalous embryonogenesis arising from defective tissue along the entire mesonephric ridge as well as a consequent failure of normal induction of development of the kidney from the metanephric anlagen. Further analysis of the embryological course of events in the AxC rat should aid in elucidation of normal developmental interrelationship in this region.

Summary. The male AxC rat exhibits a genetically-determined anomalous development of the genitourinary apparatus including absence of one kidney, ureter, vas deferens, and seminal vesicle associated with testicular hypoplasia on the same side. Detailed histochemical and histological analysis of the postnatal development of the defective testis reveals that this testis can not be differentiated from the normal testis until puberty, at which time it exhibits a total failure of tubular maturation and spermatogenic function. Interstitial cells, however, continue to develop normally and exhibit normal endocrine function and removal of the normal testis does not lead to atrophy of the prostate or seminal vesicle. Surgical extirpation of the vas deferens during the prepuberal period does not lead to any alteration in subsequent development of the normal testis. It may be concluded that this instance of testicular hypoplasia represents a genetically determined defect with delayed somatic manifestation.

1. Deringer, M. K., Heston, W. E., PROC. SOC. EXP. BIOL. AND MED., 1956, v91, 312.

3. Whitehorn, C. A., *J. Urol.*, 1956, v72, 685.

4. Longo, V. J., Thompson, G. J., *ibid.*, 1952, v68, 63.

5. Barnett, S. A., Bourne, G., *J. Anat.*, 1940, v75, 251.

6. Baker, J. R., *Quart. J. Microscopical Sci.*, 1945, v85, 1.

7. Crossmon, G., *Anat. Rec.*, 1937, v69, 33.

8. Lillie, R. D., *Histopathologic Technic and Practical Histochemistry*, Blakiston Co., N. Y., 1954.

9. del Rio Hortega, P., *Bol. Soc. Esp. Hist. Nat.*, 1921, v21, 364.

10. Gridley, M. F., *Am. J. Clin. Path.*, 1951, v21, 897.

11. Weigert, C., *Centralbl. Allg. Path.*, 1898, v9, 289, in McClung's Handbook of Microscopical Technique, Paul Huber, Inc., N. Y., 1950.

12. McManus, J. F. A., *Nature*, 1946, v158, 202.

13. Kabath, E. A., Fursth, J., *Am. J. Path.*, 1941, v17, 313.

14. Schultz, A., *Zentralbl. All. Path. Anat.*, 1924, v35, 314, in Glick's Techniques of Histo and Cyto-

1001689

chemistry, Interscience Publishers, N. Y., 1949.
15. Brunswick, O., *Z. Wiss. Mikr.*, 1922, v39, 316.
16. Deane, H. W., Morse, A., *Anat. Rec.*, 1948, v100, 127.
17. Lison, L., *Histochimie et Cytochimie Animals*, Gauthier-Villars, Paris, 1953.
18. Gomori, G., *Microscopic Histochemistry*, Univ. of Chicago Press, 1952.
19. Pearse, A. G. E., *Histochemistry: Theoretical and Applied*, Little, Brown and Co., Boston, 1954.
20. ———, *Ciba Foundation Colloquia on Endocrinology*, 1952, v4, 1.

Received April 9, 1958. P.S.E.B.M., 1958, v98.

1001690