REPOSITORY REECo
COLLECTION Tulane University Journals
BOX No. N/A
FOLDER N/A

702738

Effects of Radiation on the Human Heart

An Electron Microscopic Study

George E. Burch, MD; Rajindar S. Sohal, PhD; Shih-Chien Sun, MD; Gordon C. Miller, MD; and Harry L. Colcolough, MD, New Orleans

The electron microscopic changes of radiation effects on the human heart have been described for the first time. Disorganization of the nucleus, myofilaments, mitochondria, and sarcolemma was noticed after irradiation. Intracellular edema in the perinuclear region of the myofibers was noted. It has been pointed out that myocardial lesions resulting from irradiation seem to differ significantly from those of ischemia and infarction. Radiotherapy, it seems, should be administered carefully in the paracardiac region to avoid the possible production of a radiocardiomyopathy.

The myocardium has been often regarded as one of the most radioresistant tissues of the body.[1] Nevertheless, myocardial damage following radiotherapy has been noted following incidental exposure of the heart during therapeutic irradiation of paracardiac areas.[2]

Although there are numerous histopathologic reports on radiation induced myocardial damage,[3] the subcellular effects of irradiation have not been previously investigated in man. A correlative understanding of the biochemical, physiologic, and morphologic effects of irradiation on the myocardium is essential in order to prevent the hazardous effects of radiation. The fine structural alterations should eventually aid in better understanding the biochemical and physiologic processes of the cell. Therefore, an ultrastructural study of the heart of a patient who died of myocardial disease with congestive heart failure due to x-radiation following radiological treatment for carcinoma of the thyroid was made.

Patient Summary

A 37-year-old male physician had a histologically proved thyroid follicular carcinoma of the left lobe of the thyroid with invasion of the trachea and metastasis to cervical and mediastinal lymph nodes. A total thyroidectomy was performed and postoperative irradiation was given with a total dose of 4,800 rads to the thyroid bed and an additional dose of 5,200 rads to the mediastinum through the chest wall via six ports (Fig 1). The patient was subsequently treated with desiccated thyroid, 390 mg/day for hormonal replacement.

One year after operation and irradiation, there was no evidence of recurrence of the thyroid cancer. A postirradiation effect on the skin of the neck and port areas of the chest manifested by induration, telangiectasias, and fixation of the skin to the deeper subcutaneous tissues was apparent. Because of the radiation damage, a tracheostomy orifice would not heal in spite of numerous surgical attempts to close it. A follow-up examination three years after the operation revealed no recurrence of the tumor. Protein-bound iodine (PBI) was 8.8μg/100 cc while the patient was still maintained on 390 mg of desiccated thyroid. The dose was increased to 520 mg during the following year.

During the fifth year after operation, the patient progressively developed nocturnal dyspnea and lethargy. An erect posterolateral x-ray film of the chest showed diffuse cardiac enlargement and pulmonary congestion. The patient was treated for congestive heart failure, and he responded fairly well with subsidence of symptoms. His condition remained satisfactory for about one year and eight months until dyspnea recurred and his temperature rose to 102 F (38.9 C). He was treated for pneumonia. Cardiomegaly persisted. His electrocardiogram showed sinus tachycardia of 100/min, QRS of 0.12 seconds, low T waves, occasional premature ventricular contractions, a right bundle-branch block pattern, and signs of diffuse myocardial disease. He was given digoxin and diuretics which had

Received for publication Aug 24, 1967; accepted Nov 28.
From the Department of Medicine of the Tulane University School of Medicine and the Charity Hospital of Louisiana, New Orleans.
Reprint requests to 1430 Tulane Ave, New Orleans 70112 (Dr. Burch).

0024187

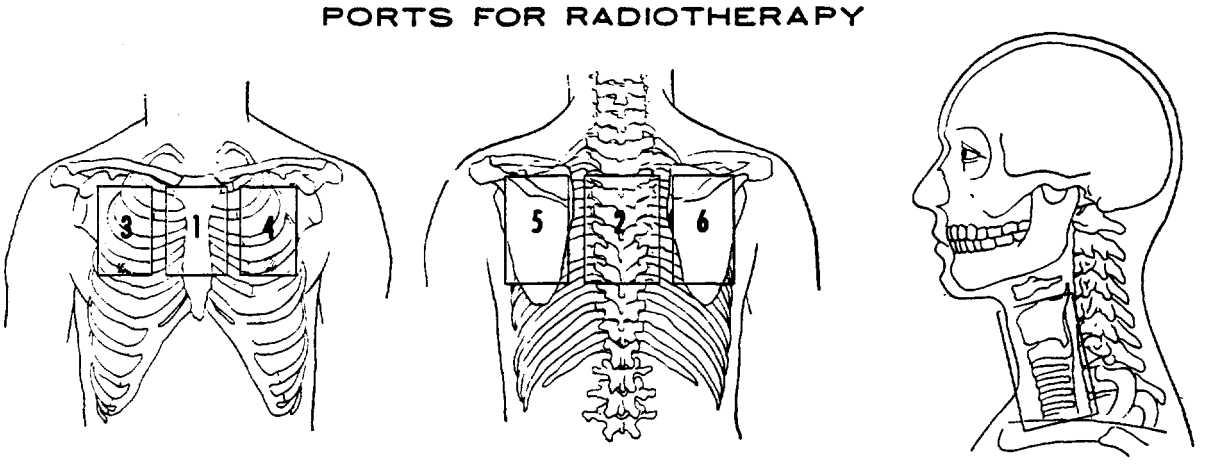

Fig 1.—A diagrammatic sketch of the ports of radiation. A minimum tumor total dose of 5,200 rads was administered through ports 1, 2, 3, 4, 5, and 6 and a dose of 4,200 rads was given for thyroid therapy through a port (right).

no significant effect. His cardiac state deteriorated during the following year. There was persistent nocturnal dyspnea, pulmonary congestion, increasing cardiomegaly, and hepatomegaly. The patient died of congestive heart failure seven years after total thyroidectomy and x-ray treatment.

Materials and Methods

The heart tissue was obtained for study in 10% buffered neutral formaldehyde.[4] For histology some of the tissue was processed by conventional methods for hematoxylin and eosin staining. For electron microscopy small tissue blocks were washed in phosphate buffer and refixed in 1% osmium tetroxide for 90 minutes. Tissues were dehydrated in a graded series of ethanol and embedded in epoxy resin (Maraglas). Sections were cut with an ultramicrotome (LKB Ultrotome) and stained with uranyl acetate and lead citrate. An electron microscope (Siemens Elmiskop I) was used for observations.

Observations

The light microscopic study indicated myocardial damage characteristic for postirradiation effect.[5] The myocardial fibers showed vacuolation or hyalinization with loss of striation. The nuclei were shrunken and absent in some areas. Hemorrhage was marked and extravasated erythrocytes were seen within the interstitial connective tissue of the myocardium, indicating irradiation damage to the capillary walls. The most extensive areas of damage were noted within the atria and the outer layers of the ventricular myocardium (Fig 2). Calcification in atheromatous lesions of coronary blood vessels was noted; however, their lumina were patent.

On electron microscopy the general subcellular preservation was found to be quite satisfactory as compared to the glutaraldehyde fixation.[6] The myofibers exhibited marked cellular edema especially of the perinuclear regions (Fig 3). The myofibrils were widely separated with intervening spaces occupied by the components of sarcoplasmic reticulum and the mitochondria. In some regions of the myofibers, cell organelles had completely disappeared leaving wide empty spaces. The cellular ground substance lacked its usual electron density, suggesting a leaching or dilution of the sarcoplasm.

The outer basement membrane-like layer of the sarcolemma was puffy and frayed in some regions. The plasma membrane or the inner sarcolemmal membrane was fragmented and gaps were present along the cell boundary (Fig 4). Complete disintegration of sarcolemma was noted in some regions (Fig 5). Dense granular material was sometimes seen subjacent to the inner sarcolemmal membrane (Fig 6). This material seems to represent precipitates of the macromolecules leached from the sarcoplasm. Mitochondria were variably swollen and the number of their cristae was considerably reduced. The cristae were disorganized as manifest by their clumping and loss of their usual parallel orderly arrangement. Mitochondria showed the presence of osmiophilic

0024188

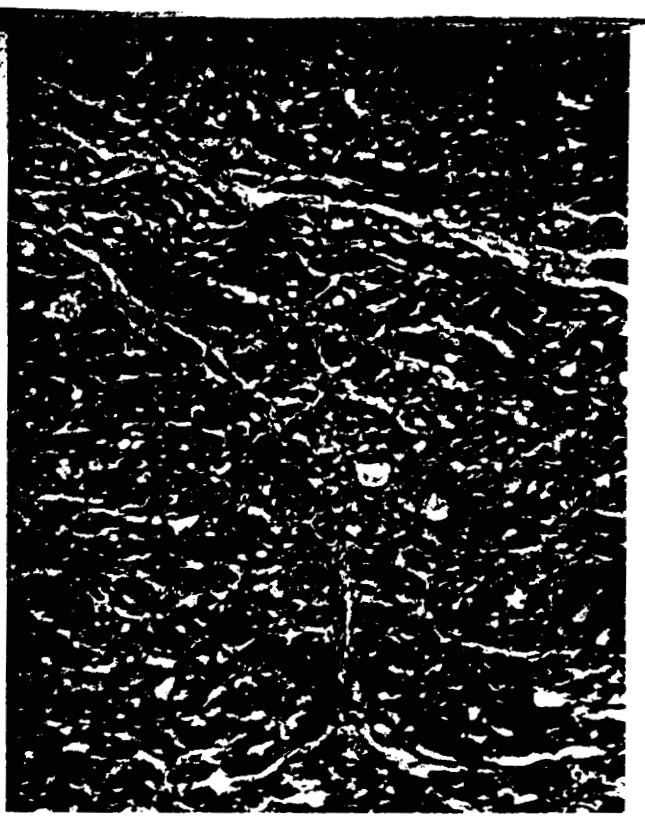

Fig 2.—A section of the myocardium from the anterior portion of the left ventricular wall showing widespread areas of myofiber degeneration with vacuolation, hyalinization, and disappearance of nuclei. Note relatively less damaged myofibers at inner side of the wall (right) in comparison with severe degeneration at outer side of the wall (left) (hematoxylin and eosin, × 120).

Fig 3.—Electron micrograph of the radiation-damaged heart. The nucleus (N) is irregular in configuration. Dense chromatin material is mainly present subjacent to the nuclear membrane. Note the absence of cell organelles immediately around the nucleus. Mitochondria have a pale matrix with disrupted cristae (× 12,750).

Fig 4.—Electron micrograph of the peripheral region of a myofibril showing disruption of plasma membrane of the sarcolemma (arrow). The myofibrils are fragmented and the mitochondrial cristae are reduced in number and disorganized (× 30,000).

Fig 5.—Longitudinal section of a myofiber showing absence of the sarcolemma (S) in certain areas (arrows) (× 18,000).

0024189

Fig 6.—Transverse section through myofibers showing dense precipitate material subjacent to the sarcolemma (arrows) (× 13,500).

Fig 7.—An electron micrograph showing the fusion of the outer and inner limiting membranes of the mitochondria (M) (arrows). Aggregations of osmophilic material is seen within the mitochondrial matrix (× 60,000).

Fig 8.—Longitudinal section through a myofiber showing the disruption of myofibrils at the A-band region of the sarcomere. Dense Z-band material is absent at certain foci (arrows). However, the components of transverse tubule system are essentially intact (× 25,500).

material within their matrix (Fig 7). The outer limiting double membranes of the mitochondria were fused along a part of the mitochondrial circumference, forming a single thick layer (Fig 7). The total number of mitochondria did not seem to have decreased. The sarcoplasmic reticulum did not show any widespread abnormality.

Myofibrillar disintegration and atrophy was one of the most striking features of the morphologic alteration. The bulk of the myofibrils were discontinuous, patchy, and reduced in size. Sarcomere breaks appeared to have occurred in the A-band region. The Z-bands were very dense and expanded in some areas but were completely absent in other areas (Fig 8). Transverse tubules remained unaltered in regions where Z-band material had disappeared.

The nucleus was usually irregular in configuration (Fig 3). The central nuclear region was mostly devoid of chromatin but had a thin dense layer

00241 90

of chromatin present along the nuclear membrane.

Comment

Previous studies suggest both indirect cell injury secondary to obliterative radiation-induced vascular disease[2,7-13] and direct cell injury from the immediate effects of radiation.[14] This communication describes the lesions of the heart's myocytes and their subcellular components. The present study indicates that after irradiation significant changes occur at the subcellular level in the myocardium of man. Irradiation of the heart seems to produce extensive disorganization of mitochondria, myofibrils, nucleus, and sarcolemma. The nature of the lesions produced in the heart as a result of x-radiation have been considered by some authors to be nonspecific and similar to those resulting from infarction.[15-17] However, what appears as simple myocardial necrosis under the light microscope can take a more specific meaning when studied ultrastructurally.

There are several reports on the ultrastructural variations of the myocardium following acute infarction.[18-20] There are, however, some changes in anoxic myocardial cells which seem to differ from those of the irradiated myocardium. Unlike infarcted myocardial cells, the irradiated cells do not show increased lipid droplets. The sarcoplasmic reticulum in irradiated cells does not show any overt swelling and there is no hyalinization of the myofilaments. Alteration and disruption of membranes of both the sarcolemma and mitochondria with accumulation of small, dense, osmophilic particles beneath the sarcolemma and leakage of cellular components into the extracellular space does not seem to be a significant finding in the irradiated myocytes. These are unlike any of the changes seen in anoxia or chronic ischemia.

On the basis of the present study, it is not possible to define a specific subcellular lesion which is characteristic of irradiation. Nevertheless, it seems likely that the changes seen in the various membrane systems may well be causally related to the irradiation itself or some, as yet, poorly understood long term result of its initial effects. Whether the changes seen are due primarily to myofiber damage or to irradiation vasculitis is likewise unknown at this time. The pertinent point, however, seems to be that large doses of irradiation to the mediastinum can cause damage to the myocardium that may manifest itself only months or years after the initial exposure. Cause and effect relationships still remain to be worked out.

This study was supported by Public Health Service grants 5-P01-HE-06769 and 5-T01-HE-05278.

References

1. Ellinger, F.: *Medical Radiation Biology*, Springfield, Ill: Charles C Thomas, Publisher, 1957.
2. Cohn, K.E., et al: Heart Disease Following Radiation, *Medicine* 46:281-298, 1967.
3. Jones, A., and Wedgwood, J.: Effects of Radiation on the Heart, *Brit J Radiol* 33:138-158, 1960.
4. Pease, D.C.: *Histological Techniques for Electron Microscopy*, New York: Academic Press, Inc., 1964.
5. Hartman, F.W., et al: Heart Lesions Produced by Deep X-Rays: Experimental and Clinical Study, *Bull Hopkins Hosp* 41:36-61, 1927.
6. Sabatini, D.D.; Bench, K.; and Barnett, R.J.: Cytochemistry and Electron Microscopy: Preservation of Cellular Ultrastructure and Enzymatic Activity by Aldehyde Fixation, *J Cell Biol* 17: 19-58, 1963.
7. Tullis, J.L.: The Response of Tissue to Total Body Irradiation, *Amer J Path* 25:829-851, 1949.
8. Tricot, R.; Baillet, J.; and Helmcke, G.: La péricardite constrictive post-radiothérapique (á propos d' uncas personnel), *Arch Mal Coeur* 47: 922-940, 1954.
9. Cronkite, E.P., and Bond, V.P.: *Radiation Injury in Man*, Springfield, Ill: Charles C Thomas, Publisher, 1960, p 73.
10. Bishop, V.S., et al: Effects of External Irradiation of the Heart on Cardiac Output, Venous Pressure and Arterial Pressure, *J Nucl Med* 6: 645-650, 1965.
11. Prentice, R.T.W.: Myocardial Infarction Following Radiation, *Lancet* 2:388, 1965.
12. Heidenberg, W.J.; Lupovitch, A.; and Tarr, N.: "Pulseless Disease" Complicating Hodgkin's Disease: A Case Apparently Caused by Radiotherapy, *JAMA* 195:488-491, 1966.
13. Reed, G.B., and Cox, A.J.: The Human Liver After Radiation Injury: A Form of Veno-Occlusive Disease, *Amer J Path* 48:597-611, 1966.
14. Cottier, H., and Barandun, S.: "Effects of Ionizing Radiation on Cellular Components: Electron Microscopic Observations," in Harris, R.J.C. (ed.): *Cellular Basis and Aetiology of Late Somatic Effects of Ionizing Radiation*, New York: Academic Press, Inc., 1963, p 113-118.
15. Warren, S.: Effects of Radiation on Normal Tissue: VI. Effects of Radiation on the Cardiovascular System, *Arch Path* 34:1070-1079, 1942.
16. Moss, A.J., et al: *Radiation Induced Acute Myocardial Infarction in the Dog*, Rochester, NY: University of Rochester Atomic Energy Project UR-625, 1963.
17. Phillips, S.J.; Reid, J.A.; and Rugh, R.: Electrocardiographic and Pathologic Changes After Cardiac X-Irradiation in Dogs, *Amer Heart J* 68: 524-533, 1964.
18. Bryant, R.E.; Thomas, W.A.; and O'Neal, R.M.: An Electron Microscopic Study of Myocardial Ischemia in the Rat, *Circ Res* 6:699-709, 1958.
19. Hoelscher, B.; Just, O.H.; and Merker, H.J.: Studies by Electron Microscope on Various Forms of Induced Cardiac Arrest in Dog and Rabbit, *Surgery* 49:492-499, 1961.
20. Burdette, W.J., and Ashford, T.P.: Response of Myocardial Fine Structure to Cardiac Arrest and Hypothermia, *Ann Surg* 158:513-525, 1963.

0024191