REPOSITORY ARGONNE / CHR
COLLECTION A. BRUES
BOX No. 13
FOLDER M-MI (JOURNAL ARTICLES AUTHORED BY M-MI)

702355

[Reprinted from RADIOLOGY, Vol. 68, No. 6, Pages 797–811, June, 1957.]
Copyrighted 1957 by the Radiological Society of North America, Incorporated

Proton Irradiation of the Pituitary and Its Metabolic Effects

Memorial Fund Lecture[1]

ROLLIN K. McCOMBS, M.D.

It is a great pleasure to come to Chicago to discuss our investigations of the use of the proton beam in irradiation of the human pituitary gland, and I am indebted to the Radiological Society for this opportunity.

The work to be described here has been a cooperative effort, involving the time and talents of many people: The physicists, ably led by Professor C. A. Tobias; the cyclotron crew; the animal house staff, headed by Dr. Charles Riggs, and the Institute for Experimental Biology, who jointly performed the preliminary animal investigations; the medical section, directed by Dr. John H. Lawrence, assisted by Dr. James Born, Dr. James Roberts, and the late Dr. B. V. A. Low-Beer; the radiologists of Cowell Memorial Hospital who examined all the serial roentgenograms on our patients; the pathologists; the biochemists and technicians; and last, but by no means least, the physicians who referred us patients and gave us splendid cooperation in following them, notable among this number being Dr. Charles Huggins, whose encouragement and enthusiasm in the early phases of the work were invaluable.

Irradiation of the human pituitary gland by x-rays was reported by Gramegna in 1909, for the treatment of acromegaly (1). Sensitivity of the skin and danger of injury to the brain and cranial nerves have limited the amount of radiation administered (2, 3). Nevertheless, roentgen irradiation has been a valuable therapeutic agent in pituitary tumors (4–7), malignant exophthalmos (8), and Cushing's syndrome (9). In recent years the pituitary has been irradiated also for prostatic (10) and mammary cancer (11).

Although experimental evidence suggests that overactive elements of the pituitary may be radiosensitive, statements in the literature seem to indicate that it is difficult, if not impossible, to influence the function of the normal pituitary by x-rays. Indeed, Crooke has stated that he has not observed histologic changes (12). In 3 reported cases of breast cancer, even 10,000 r to the region of the hypophysis was not sufficient to cause noticeable depression of hormone production, histologic damage, or remission of the disease (11).

Another means of delivering radiation to the hypophysis has been by a technic of radon-seed implantation; by this method pituitary function has been affected in Cushing's disease and acromegaly (13). More recently Rasmussen and associates have implanted in the pituitary yttrium

[1] From the Donner Laboratory of Biophysics and Medical Physics, Donner Pavilion, and the Radiation Laboratory, University of California, Berkeley, Calif. Delivered at the Forty-second Annual Meeting of the Radiological Society of North America, Dec. 3, 1956. Various phases of this work were supported by the U. S. Atomic Energy Commission, the Donner Foundation, and the California State Cancer Fund.

0018027

PARTIAL DOCUMENT

Fig. 1. Autoradiograph of the 340-MEV proton beam as it passes through a block of lucite.

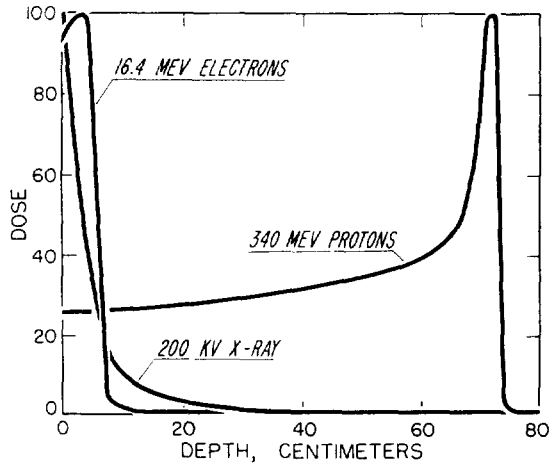

Fig. 2. Comparison of surface and depth doses for 200-kv x-rays, 16.4 MEV electrons, and 340 MEV protons in an absorber very similar to tissue.

seeds, giving sizeable doses of beta irradiation, to stop hypophyseal function and cause regression of breast cancer (14). This study is still in progress at the University of Chicago and at McGill University. Rothenberg and his colleagues instill colloidal chromic radiophosphate into the pituitary to effect its destruction (15).

Recent advances in surgical technic and postoperative management have made hypophysectomy feasible. Luft and Olivecrona, in Sweden, have reported their experience in some 37 cases of metastatic carcinoma of the breast (16) and in some 20 cases of severe diabetes mellitus (17). Kennedy and his associates at the University of Minnesota have reported 12 cases of breast cancer thus treated (18). Currently Pearson *et al.* (19) and other groups are vigorously attacking the problems of hypophysectomy in cancer and other diseases.

The development of the cyclotron, betatron, linear accelerator, and other machines has made possible the production of beams of particles which may be directed to any

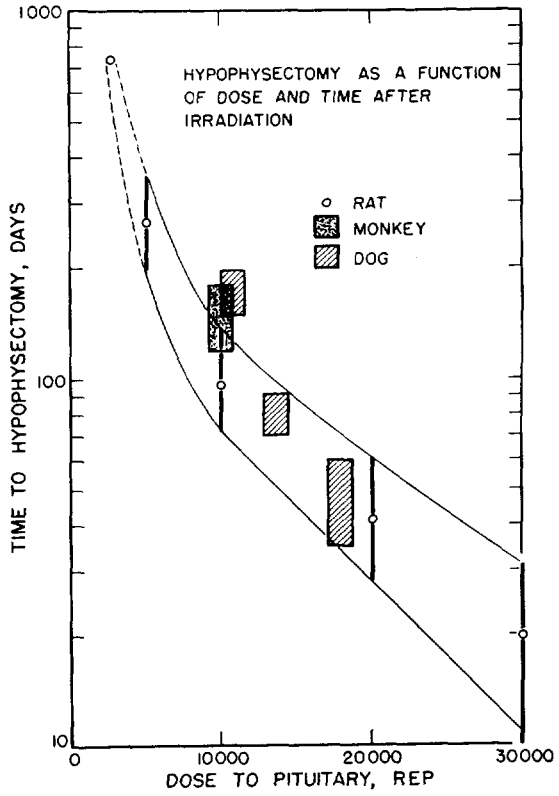

Fig. 3. Relationship between dose and time of onset of changes resembling hypophysectomy.

portion of the body. Our work has been with the 184-inch synchrocyclotron at the University of California in Berkeley; 190 MEV deuterons and 340 MEV protons were used in the preliminary animal studies, but only the 340 MEV protons have been used in work with human beings.

Deuteron and proton beams have several distinct properties not possessed by x-rays or gamma rays. First, they can be collimated very finely, and in small animals cylindrical lesions 1.0 mm. in diameter are easily produced (20). Secondly, as the particles penetrate, their scattering is so small (compared to electrons) that for practical purposes no

0018028

radiation falls outside the main beam to irradiate neighboring tissues. The lesions have microscopically sharp margins, much as might be made by scalpel. Figure 1 shows an autoradiograph of the 340 MEV proton beam as it travels along a piece of film sandwiched between two slabs of Lucite (21). The beam enters from the left. Part of the loss of definition on the right comes from the slightly divergent nature of the beam and part from multiple elastic scattering. A third unusual feature of these beams is the relatively great depth dose which they deliver, compared with surface dose. The comparative doses at the surface and depth for 200-kv x-rays, 16 MEV electrons, and 340 MEV protons are shown in Figure 2, after Tobias *et al.* (22). The dose delivered by the x-rays falls off markedly with increasing depth, as does that delivered by electrons from the betatron or synchrotron; but the proton irradiation rises to a peak, so that the maximum depth dose is approximately three times the dose at the surface. Up to the present time advantage has not been taken of this Bragg effect, and the relatively great depth doses are obtained by rotational technic. Work is proceeding, however, in this direction.

Starting in 1952, efforts were made to study the effects of the high-speed particles on the rat hypophysis. Initial results were encouraging, and pituitary irradiation of monkeys, normal dogs, and dogs with breast cancer was undertaken. The biological effectiveness of the high-energy deuteron and proton beams was found to be close to that of 200-kv x-rays.

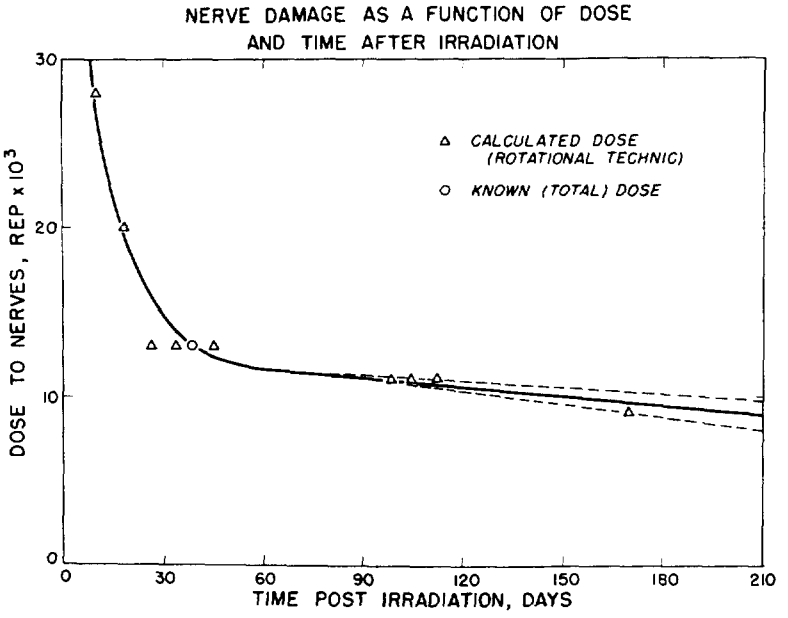

Fig. 4. Damage in dog cranial nerve as a function of dose and time after irradiation.

When large single doses of more than 5,000 rad of deuterons or protons are given to the pituitary glands of animals, the final result appears to be the same regardless of the size of the dose. Progressive atrophy of the entire gland results, accompanied by reduction in physiological function. The higher the dose, the sooner the physiological effects become apparent. Single doses of 30,000 rad are necessary to approximate the immediate effects of surgical extirpation of the pituitary. Figure 3 shows the relationship between dose and the time of onset of profound physiological changes resembling complete hypophysectomy (21). Criteria for evaluation are chiefly rate of

0018029

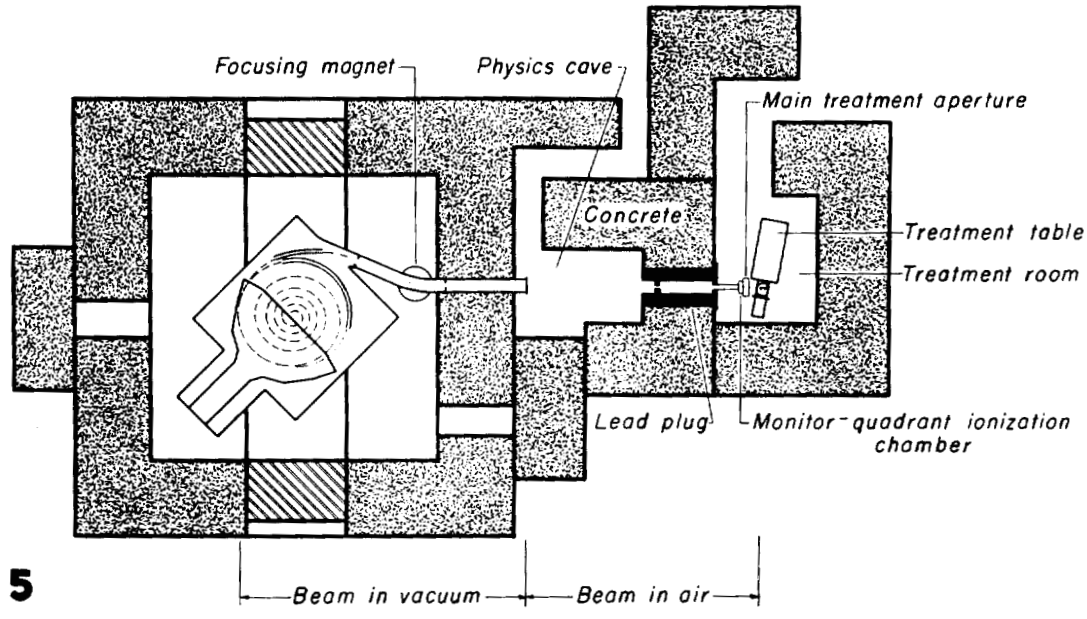

5

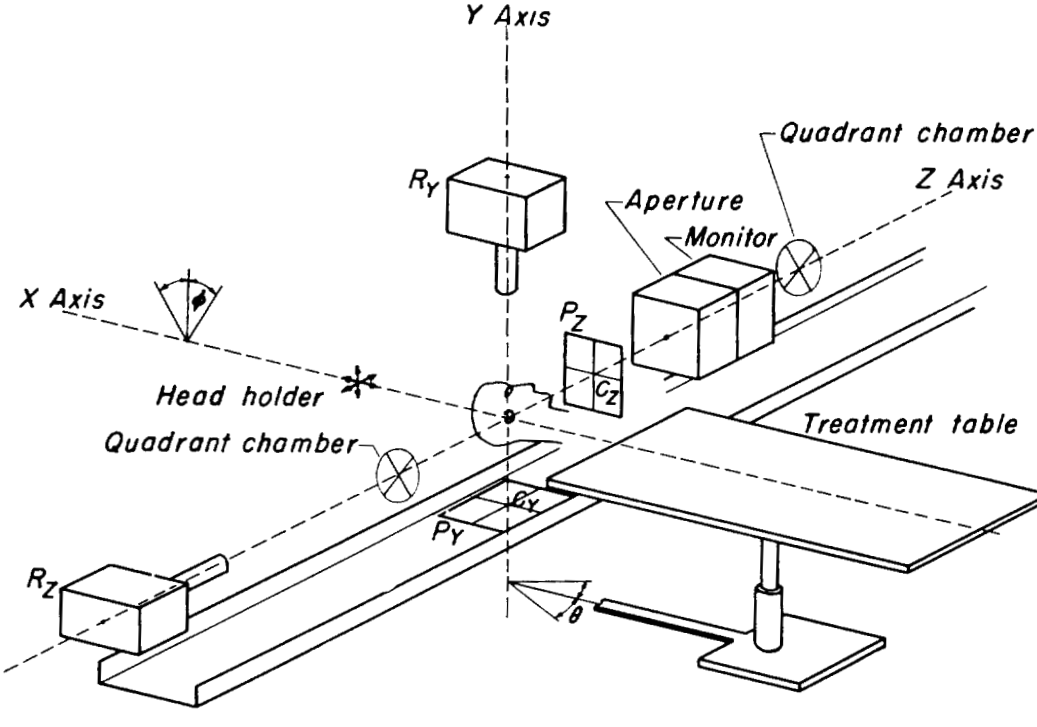

6

Fig. 5. Diagram of the synchrocyclotron, shielding, and treatment room.
Fig. 6. Schematic diagram of the apparatus for proton pituitary irradiation.

growth, thyroid function, and size of target organs. Data for rat, dog, and monkey follow the same general pattern.

Since May 1954, 51 dogs have received pituitary irradiation with protons or deuterons in various doses and by various

0018030

technics. Included were 36 normal beagles and 15 dogs with spontaneous mammary carcinoma.

Lethal effects of pituitary irradiation in large single doses in the normal dogs were ascribed to nerve and brain lesions, particularly to necrosis and hemorrhage. The lethal effects were usually preceded by damage to the 3rd, 4th, and 5th nerves, which, in the dog, lie very close to the pituitary. The lesions led to inability of the animals to move their eyelids, permanent dilatation of the pupils, and loss of corneal sensitivity. A series of experiments was performed to determine the dose-time relationship in the cranial nerves of the dog. The characteristic dose-time injury curve is shown in Figure 4, resembling the data for the pituitary (21).

A temporary type of nerve damage was also observed in some of the dogs; here the dose to the cranial nerves themselves was low, but the neighboring pituitary and cavernous venous plexus received heavy irradiation, in excess of 10,000 rad (21). Eye signs developed and increased in severity two to three weeks after irradiation, then partially or completely regressed six to eight weeks later. These signs were ascribed to pressure from edema of the nearby irradiated structures.

In the dogs with carcinoma, the results were favorable in animals initially in fair condition, *i.e.*, not terminal cases with necrosis. Persistence of some radioiodine uptake and continuation of estrous cycles showed that in these animals pituitary destruction was not complete. There were indications that the tumors may become static or regress, starting to grow again after a period of six to twenty-four months (23).

The stage was now set for proton irradiation of the human pituitary. Figure 5 shows the general layout of the apparatus (21). With the generous help of the staff of the Berkeley 184-inch cyclotron, a treatment room was constructed, as shown. The cyclotron is in the large shielded room at the left. The collimated proton beam is brought out through an aperture, passing through a physics cave into the treatment room, carefully shielded to avoid stray radiation.

Fig. 7. Upper portion: Lateral roentgenogram of the sella turcica in correct alignment for proton irradiation. Lower portion: Same, except that the proton beam was turned on momentarily to make an autoradiograph.

During irradiation the patient is supine, the head held rigidly by a mask, which in turn is fastened to a head-rotating device. The set-up is shown schematically in Figure 6 (21). The proton beam passes along the Z axis from right to left. Quadrant chambers show any change in the position of the beam, and an ionization chamber in the path of the beam monitors the dosage. The beam is automatically shut off at any predetermined dose or if the head rotator fails or if the patient wishes to interrupt the seance for any reason. R_Z is a diagnostic x-ray tube whose beam coincides with the proton beam. By its use lateral views of the sella turcica are made, the film being in the holder P_Z. By means of adjusting screws on the head holder, the patient's head can be moved inferosuperiorly (along

0018031

Fig. 8. Anteroposterior roentgenogram of the sella turcica in correct alignment for proton pituitary irradiation.

patient by momentarily turning on the proton beam, after making the x-ray exposure, prior to developing the film. The black spot shows the shape of the beam, which is adjusted to fit each individual patient. The beam spot is actual size, whereas the roentgen shadow of the sella is enlarged by 20 per cent because of divergence of the x-ray beam from the target spot.

R_Y is another diagnostic x-ray tube used to make anteroposterior views of the sella turcica. An adjusting screw on the head holder permits lateral movement of the patient's head (along the Z-axis) until the center of the sella turcica lies in the axis of rotation of the head (the X-axis). Figure 8 is a roentgenogram of

Fig. 9. Patient in position for proton pituitary irradiation.

the X-axis) and anteroposteriorly (along the Y-axis) until the centers of the x-ray beam and proton beam pass through the center of the sella turcica. This is illustrated in the upper portion of Figure 7, which shows a head in position for treatment (21). A radioautograph of the proton beam, shown in the lower portion of the figure, was prepared for the same a head in position for treatment (21). The medial margins of the orbits, the anterior clinoid processes, and the mid-point of the roof of the sphenoid sinus are useful in defining the mid-point of the sella turcica.

During the first irradiation seance, six to eight sets of diagnostic films were usually needed to bring the patient's

0018032

head into alignment. At subsequent seances the adjusting screws on the head holder were pre-set to positions which had previously given proper alignment, and usually one or two sets of positioning roentgenograms sufficed.

Figure 9 shows a patient in position ready for pituitary irradiation (21). The proton beam will enter through the steel tube in the upper part of the picture.



Fig. 10. Autoradiograph of the proton beam on a film placed at the site of the pituitary in a Lucite phantom cranium which was subjected to a complete schedule of rotations and position angles.

The fiberglass-and-plastic mask holds the head rigidly in the head rotator. The diagnostic x-ray sets used in alignment are shown on the left above and below.

Let us now return again to Figure 6 for further consideration of the irradiation technic. During the course of irradiation the patient's head was rotated slowly from side to side about the vertebral axis (X-axis); in most cases, unless disease in the cervical vertebrae prevented it, the rotation was 35° to either side (ϕ = 70°). The irradiation was, for the most part, administered in increments of 1,000 rad, each increment being delivered from a different direction by rotating the patient and treatment table (changing θ). By this means the beam was delivered in cones, all with apices in the sella turcica, ranging from 35° below to 35° above the coronal plane passing through the sella. In other words, the angle θ was varied through a total angle of 70° in eleven steps 7 1/2° apart.

In summary, the apparatus is contrived so that no matter how the patient's head

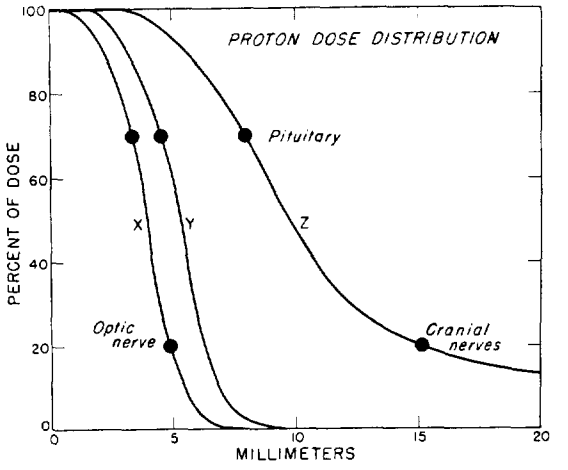

Fig. 11. Dose distribution, in terms of per cent of dose at the center of the pituitary, along the three major axes.

is turned the proton beam always passes through the sella turcica. The pituitary thus receives the greatest amount of radiation, while the dose delivered to structures removed from the pituitary varies inversely as the square of the distance.

Figure 10 is a radioautograph of the proton beam on a film placed in the Lucite head phantom and exposed to a full set of rotations and position angles corresponding to the entire irradiation schedule for the human being (21). The blackened area is the region of high dose and corresponds closely in size and shape to the human hypophysis.

Figure 11 shows the dose distribution along the three major axes of the head, X (longitudinal), Y (posteroanterior), and Z (lateral) (21). The data were obtained densitometrically from films placed in the Lucite phantom head at various distances from the pituitary in regions traversed by the proton beam At the cranial nerves and temporal brain lobes the dose level is 10 to 20 per cent of the peak dose at the center of the hypophysis. Parts of the optic nerves receive 20 to 30 per cent of the peak dose, while most of the optic chiasm and hypothalamus are virtually free from irradiation.

The relationship between isodose curves and anatomical structures around the

0018033

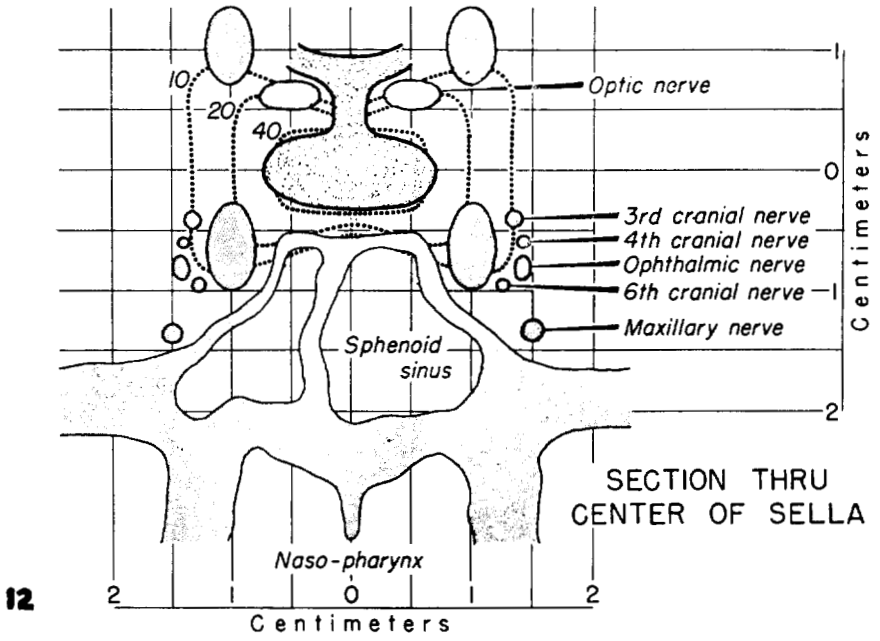

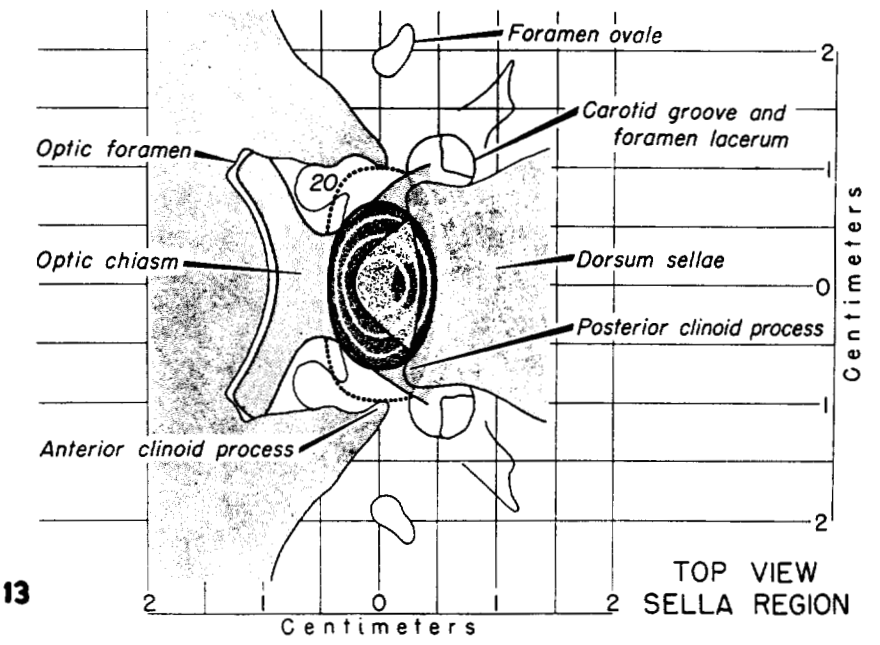

Fig. 12. Isodose curves plotted on a schematic diagram of a transverse section through the center of the sella turcica.

Fig. 13. Isodose curves plotted on a schematic diagram of a top view of the sella turcica. In both Fig. 12 and Fig. 13 the dose at the center of the sella turcica is taken as 100 per cent.

hypophysis is shown in Figure 12, which is a schematic drawing of a transverse section through the center of the sella. Figure 13 is a schematic drawing of the sella as seen from above, with superimposed isodose curves (21).

Between September 1954 and September 1955, 26 patients with metastatic

0018034

breast cancer received pituitary irradiation. Patients were selected for irradiation on the basis of several criteria: (1) There must have been objective evidence of progressing metastases. (2) The patient should have received all indicated conventional surgical and radiological treatment. (3) Wherever practicable, the patient should have received a trial of hormone therapy, adrenalectomy, and removal or roentgen irradiation of the ovaries. No patients were rejected because of the advanced state of their disease; many of the earlier cases were nearly terminal when first seen.

PITUITARY IRRADIATION SCHEDULE

	Cumulative Total Rads	Irradiation Interval, Days	Rads per Session, Maximum	Rads per Plane, Maximum
EARLY PATIENTS	14 000	63	650	150
LATE PATIENTS	30 000	14	5000	1000

Fig. 15. Irradiation schedule.

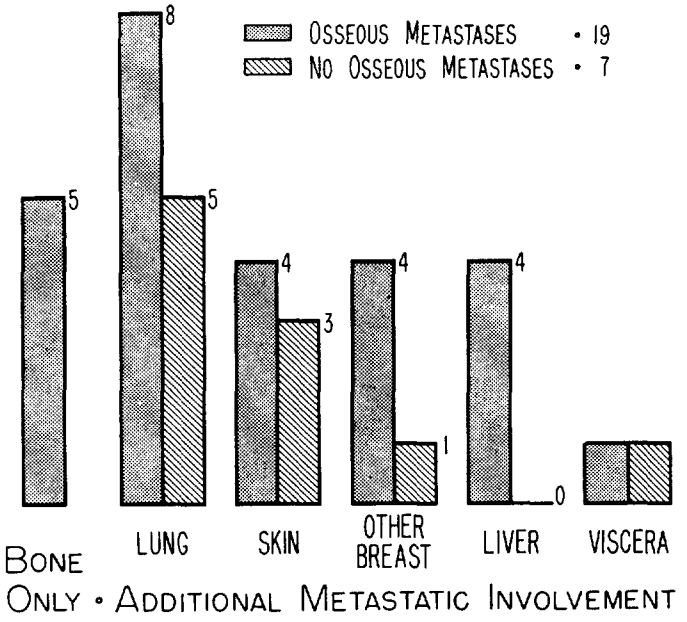

Fig. 14. Metastatic involvement of the patients when first seen.

Sixteen patients, including the first 13 irradiated, had previously undergone bilateral adrenalectomy and oophorectomy, with remissions lasting from several months to several years. Of the other 10 patients, 3 had had only bilateral oophorectomy, and 7 had had neither adrenalectomy nor oophorectomy.

Nineteen of the patients had bone metastases; at least 8 of these had additional metastases in the lung and 4 had known metastases in the liver. The 7 patients without osseous involvement had metastases in the skin, lungs, or viscera. Figure 14 summarizes the metastatic involvement for the series when the patients were first seen.

Proton irradiation of the pituitary was given in fractionated doses, three times weekly. The patients seen in the earlier period of the study received small doses per seance, and the course of irradiation covered a protracted period. As the work progressed and the safety factor could be evaluated, the amount of irradiation administered to the hypophysis and the cumulative total were increased, while the time required for the entire course of irradiation was shortened. Thus, the first patient received 14,000 rad during a sixty-three-day interval, while some of the later patients received as much as 30,000 rad in six seances within a two-

0018035

week period. Figure 15 summarizes the irradiation schedule.

Several patients complained of head pain following irradiation seances. This could be ascribed to manipulation of the neck during rotation or to pressure from the head mask. Neither during nor after irradiation were any auditory, visual, or olfactory auras experienced. No indications of increased intracranial pressure, as manifested by papilledema, hyperthermia, vomiting, or vasomotor changes, were noted. No electrolyte disturbances were detected following irradiation sessions.

A few weeks following completion of irradiation, 5 patients, those receiving the heaviest irradiation, experienced severe head pains, lasting for a few days. They were usually described as throbbing, sharp, deep within the skull, and were relieved by aspirin. In all cases they soon disappeared completely. They resembled the headaches associated with acromegaly and other pituitary disorders.

The most valuable criteria for assessing changes in pituitary function following pituitary irradiation have been radioiodine uptake by the thyroid and twenty-four-hour urinary pituitary gonadotropin excretion. Figure 16 shows the changes in radioiodine uptake following pituitary irradiation. Of 18 patients for whom data are available, there was marked depression of iodine uptake in 11, in many instances reaching values as low as 5 per cent. In 6 patients there was no significant change in radioiodine uptake, although in 4 of the 6 it was initially low. In one patient there was a slight rise. In 8 of 16 patients for whom complete data are available there was a marked drop in urinary excretion of pituitary gonadotropins. In 7 patients there was no change after irradiation, but in these the excretion was originally at the lowest concentration detectable, 5 mouse units. Only 1 patient showed a permanent rise. Figure 17 shows the changes in urinary gonadotropin excretion following irradiation.

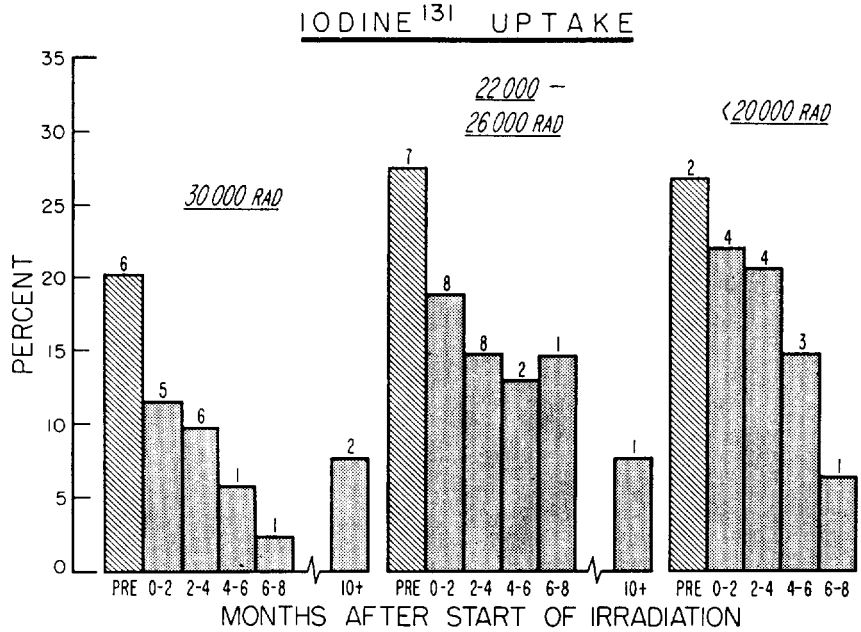

Fig. 16. Changes in twenty-four-hour thyroid radioiodine uptake following pituitary irradiation. The numeral above each column denotes the number of patients averaged in that group.

In an effort to assess the state of activity of the disease, several laboratory tests were performed routinely—protein-bound iodine, alkaline and acid phosphatase,

001803b

urinary calcium excretion, coagulability of serum proteins, and urinary corticosteroid excretion. Details of these determinations will not be presented in this paper, which will be confined to clinical evaluation and the objective results of roentgen examination.

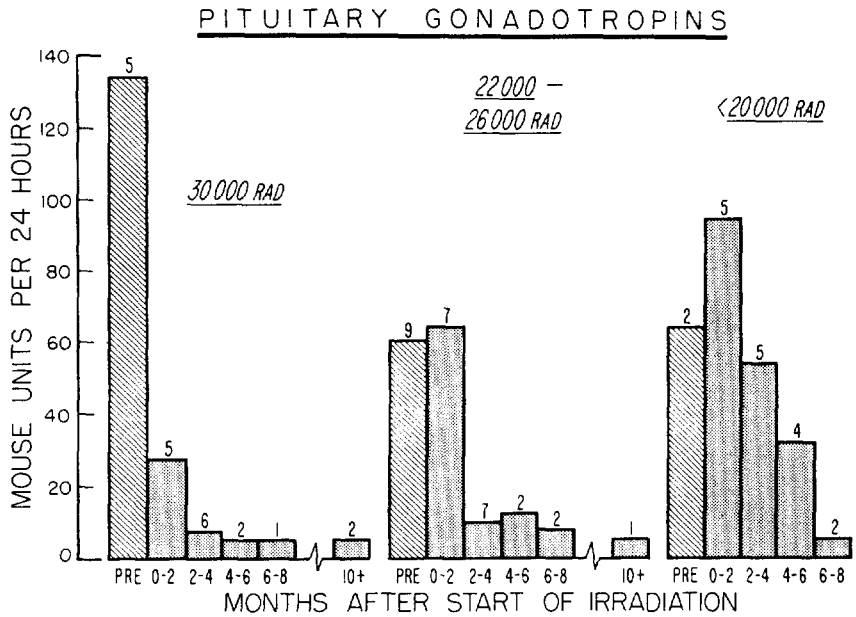

Fig. 17. Changes in twenty-four-hour urinary pituitary gonadotropin excretion following pituitary irradiation. The numeral above each column denotes the number of patients averaged in that group.

Serial skeletal and chest surveys were made regularly in all patients. Besides 5 patients who showed some healing of osseous lesions, there were 2 patients in whom the bony metastases remained stationary for several months. In one patient recurrent pleural effusion, with demonstrable tumor cells, resolved after irradiation and has not recurred in sixteen months. In 3 others, pulmonary metastases remained stationary for as long as a year after irradiation.

Clinical changes following pituitary irradiation included development in 3 patients of diabetes insipidus, which was managed satisfactorily by vasopressin tannate in oil, then by posterior pituitary principle nasal insufflation. The patients have not shown complete loss of pubic or axillary hair, absence of normal skin pigmentation, thinning of the eyebrows, absence of sweating, or loss of normal greasiness of the axilla, changes found by Sheehan and Summers in women with proved post-partum necrosis of the pituitary (24). The initial breast lesion in one patient changed markedly over a period of several months in consistency and size, no longer being palpable. The affected portion of the breast became freely movable upon the underlying tissue. Biopsies, however, still disclosed the presence of tumor cells.

One patient with abdominal carcinomatosis had required, prior to irradiation, frequent paracenteses. During a surgical attempt at adrenalectomy and oophorectomy the intraabdominal metastases precluded this procedure, and she was selected for pituitary irradiation. At the time of starting irradiation, colloidal chromic radiophosphate was instilled into the peritoneal cavity, and the patient did not require paracentesis for over a year.

Upon the clinical appearance of the need for replacement therapy, the patients were given thyroid extract, 1 to

0018037

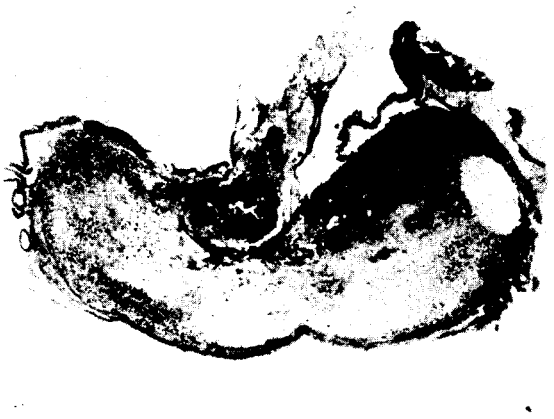

Fig. 18. Sagittal section of the pituitary gland from a patient who received 26,000 rad in twelve days and survived seven months.

Fig. 19. Microscopic appearance of the thyroid gland in the patient of Fig. 18. This patient received no thyroid extract.

Fig. 20. The sella turcica of a patient who received 30,000 rad in twenty-one days and survived fourteen months. (Photograph by Barry Evans, Berkeley, Calif.)

2 grains daily, and prednisolone, 10 to 15 milligrams daily, with satisfactory response. The adrenalectomized patients were, of course, continued uninterruptedly on a maintenance cortisone schedule. Several patients prior to irradiation had been placed on testosterone by their own physicians, and this was continued, primarily for its protein anabolic effect, since it had been unsuccessful in retarding metastatic extension.

Two patients now survive, both sixteen months post-irradiation. One is still in remission; the other had a remission for nearly a year and is now failing.

Twenty-two of the 24 deceased patients have come to necropsy. The effects of proton irradiation upon the pituitary and target organs will be discussed briefly.

There was a marked difference in the pituitaries of patients who had received low (13,000 through 19,000 rad), medium (20,000 through 26,000 rad), and high (more than 27,000 rad) levels of irradiation. Damage was discernible grossly in those patients who received medium and high levels of irradiation and survived for, say, five months. Histologic evidence of damage was apparent in all patients who received over 20,000 rad, regardless of the interval between irradiation and death. Among those receiving less than 20,000 rad, microscopic examination showed necrosis infrequently; and the moderate fibrosis, increased vascularity, and shrinkage of cells from the basement membrane were not considered confirmatory of irradiation damage.

No gross evidence of injury has been detected in the brains or cranial nerves. Microscopic examination of the specimens is kindly being done by Dr. Nathan Malamud, Associate Clinical Professor of Neuropathology, Department of Pathology, University of California School of Medicine, San Francisco, but this is a

0018038



Fig. 21. The pituitary remnant dissected from the sella turcica of Fig. 20 and sectioned in the mid-sagittal plane (Photograph by Barry Evans, Berkeley, Calif.)

laborious task, and results of serial sections on all specimens are not yet available. Among the completed studies, including those on patients who had the highest levels of irradiation, there has been no evidence of irradiation damage to the brain or nerves.

Microscopic examination of the adrenal glands could lead to no definite conclusions because supportive corticosteroid therapy was given. Similarly, microscopic examination of the ovaries was not informative because of x-ray castration or the use of testosterone in the few patients with intact ovaries.

Microscopic examination of the thyroids showed involution at all levels of irradiation for all survival times. Several patients died without receiving thyroid extract.

To see just how well the proton beam can destroy the pituitary, reference may be made to Figure 18, which shows a sagittal section from a patient who received 26,000 rad in twelve days. Much of the center of the gland has been destroyed. Figure 19 shows the thyroid from this patient. Note that the acini are full of colloid, that there is no vacuolization in the periphery of the colloid, and that the epithelium is flat. This patient did not receive thyroid extract.

The outstanding example of what has thus far been achieved with pituitary irradiation is illustrated by Figure 20, which shows the sella turcica of a patient who received 30,000 rad and survived fourteen months. There appears to be nothing whatever in the sella. Dissection produced only a 1.0-mm. thick sellar lining. This pituitary remnant, together with its investing membranes, is shown in Figure 21. The microscopic section is shown in Figure 22.

In conclusion, may I say that I have not come here as a proponent of destruction or extirpation of the pituitary gland in metastatic cancer. I believe that we have achieved our purpose. . .the destruction of a deep-seated organ without damage to the intervening tissues. I believe that some of our patients have been benefited and that we have demonstrated that we can depress pituitary function and destroy the pituitary without subjecting the patient to a craniotomy, with its mortality and morbidity. Whether or not hypophysectomy earns a lasting place

0018039

in the palliation of metastatic cancer—indeed, whether it is effective beyond adrenalectomy and oophorectomy—must await the combined test of the many workers now investigating the problem. I believe that our technic will be of value in the treatment of pituitary tumors, malignant exophthalmos, and, perhaps, Cushing's disease.

Rather, I come to you as a physicist turned doctor, to suggest that the technic and accelerating machines which have ushered in the nuclear era may, in a less cumbersome and less expensive form, become a part of the radiologist's therapeutic armamentarium, providing him with an agent of precision and penetrating power far exceeding any he now has.

Fig. 22. Microscopic section, sagittal plane just off the mid-line, of the pituitary remnant shown in Fig. 21.

REFERENCES

1. GRAMEGNA, A.: Un cas d'acromégalie traité par la radiothérapie. Rev. neurol. **17**: 15–17, 1909.
2. MALAMUD, N., BOLDREY, E. B., WELCH, W. K., AND FADELL, E. J.: Necrosis of Brain and Spinal Cord Following X-Ray Therapy. J. Neurosurg. **11**: 353–362, July 1954.
3. DUGGER, G. S., STRATFORD, J. G., AND BOUCHARD, J.: Necrosis of the Brain Following Roentgen Irradiation. Am. J. Roentgenol. **72**: 953–960, December 1954.
4. HORRAX, G., SMEDAL, M. I., TRUMP, J. G., GRANKE, R. C., AND WRIGHT, K. A.: Present-Day Treatment of Pituitary Adenomas. Surgery versus X-Ray Therapy. New England J. Med. **252**: 524–526, March 31, 1955.
5. LEDDY, E. T., AND MARSHALL, T. M.: Roentgen Therapy of Pituitary Adamantinomas (Craniopharyngiomas). Radiology **56**: 384–393, March 1951.
6. KAHN, E. A.: In Symposium on Indications for and Effects of Irradiation of the Pituitary Gland. Brit. J. Radiol. **17**: 133–135, May 1944.
7. KAPLAN, I. I.: Irradiation of Brain Tumors at Bellevue Hospital, 1924–1939. Radiology **36**: 588–595, May 1941.
8. BEIERWALTES, W. H.: X-Ray Treatment of Malignant Exophthalmos: A Report on 28 Patients. J. Clin. Endocrinol. **13**: 1090–1100, September 1953.
9. JOHNSEN, S. G.: Roentgen Irradiation of the Pituitary in Cushing's Syndrome. Acta med. scandinav. **144**: 165–188, 1952.
10. MURPHY, W. T., AND SCHWIPPERT, H.: Pituitary Irradiation in Prostatic Carcinoma. Radiology **56**: 376–383, March 1951.
11. KELLY, K. H., FELDSTED, E. T., BROWN, R. F., ORTEGA, P., BIERMAN, H. R., LOW-BEER, B. V. A., AND SHIMKIN, M. B.: Irradiation of the Normal Human Hypophysis in Malignancy: Report of Three Cases Receiving 8,100–10,000 r. Tissue Dose to the Pituitary Gland. J. Nat. Cancer Inst. **11**: 967–983, April 1951.
12. CROOKE, A. C.: In Symposium on Indications for and Effects of Irradiation of the Pituitary Gland. Brit. J. Radiol. **17**: 135–137, May 1944.
13. NORTHFIELD, D. W. C.: Radon Implantation for Acromegaly and Cushing's Syndrome. Proc. Roy. Soc. Med. **42**: 845–853, October 1949.
14. RASMUSSEN, T., HARPER, P. V., JR., AND KENNEDY, T.: The Use of a Beta-Ray Source for Destruction of the Hypophysis. S. Forum **4**: 681–686, 1953.
15. ROTHENBERG, S. F., JAFFE, H. L., PUTNAM, T. J., AND SIMKIN, B.: Hypophysicteny with Radioactive Chromic Phosphate in Treatment of Cancer. Arch. Neurol. & Psychiat. **73**: 193–199, February 1955.
16. LUFT, R., AND OLIVECRONA, H.: Hypophysectomy in Man: Experiences in Metastatic Cancer of the Breast. Cancer **8**: 261–270, March-April, 1955.
17. LUFT, R., OLIVECRONA, H., AND SJOGREN, B.: Hypophysectomy in Man: Experiences in Severe Diabetes Mellitus. J. Clin. Endocrinol. **15**: 391–408, April 1955.
18. KENNEDY, B. J., PEYTON, W. T., AND FRENCH, L. A.: Total Hypophysectomy in Advanced Breast Cancer. Bull. Univ. Minn. Hosp. **26**: 528–551, April 1955.
19. PEARSON, O. H., RAY, B. S., HARROLD, C. C., WEST, C. D., LI, M. C., AND MACLEAN, J. P.: Hypophysectomy in the Treatment of Advanced Cancer. Tr. A. Am. Physicians **68**: 101–111, 1955.
20. TOBIAS, C. A., VAN DYKE, D. C., SIMPSON M. E., ANGER, H. O., HUFF, R. L., AND KONEFF, A. A.: Irradiation of the Pituitary of the Rat with High Energy Deuterons. Am. J. Roentgenol. **72**: 1–21, July 1954.
21. TOBIAS, C. A., ROBERTS, J. E., LAWRENCE, J. H., LOW-BEER, B. V. A., ANGER, H. O., BORN, J. L., MCCOMBS, R., AND HUGGINS, C.: Radiation Hypophysectomy with High-Energy Proton Beams. Univ. Calif. Rad. Lab. Report No. UCRL-3035, July 1955.
22. TOBIAS, C. A., ANGER, H. O., AND LAWRENCE, J. H.: Radiological Use of High Energy Deuterons and Alpha Particles. Am. J. Roentgenol. **67**: 1–27, January 1952.
23. RIGGS, CHARLES: Unpublished data.
24. SHEEHAN, H. L., AND SUMMERS, V. K.: The Syndrome of Hypopituitarism. Quart. J. Med. **18**: 319–378, October 1949.

Donner Laboratory
University of California
Berkeley 4, Calif.

0018040

SUMMARIO IN INTERLINGUA

Irradiation a Protones del Glandula Pituitari e Su Effectos Metabolic

Post experimentos in rattos e canes, irradiation a protones del glandula pituitari esseva executate in humanos. Inter septembre 1954 e 1955, 26 patientes con cancere avantiate del pectore recipeva irradiation pituitari a protones. Omne le patientes monstrava metastases progressive, e omnes habeva previemente essite tractate per medios conventional. Le irradiation esseva applicate in doses fractional con totales de 14.000 a 30.000 rad.

Duo patientes viveva post 16 menses: le un in remission e le altere con recurrentia de symptomas post un anno.

Evidentia histologic de un lesion del glandula pituitari esseva constatate al autopsia in omne le patientes qui habeva recipite plus que 20.000 rad. Nulle macroscopic lesiones del cerebro o del nervos cranial esseva detegite. Le thyroides monstrava involution a omne nivellos de dosage.

Durante que destruction o extirpation del glandula pituitari non es recommendate super le base de iste studio como tractamento de cancere metastatic, il ha essite demonstrate que un organo de sito profunde pote esser destruite per irradiation a protones sin insulto a tessuto intermediari. Il pare que certes del patientes ha beneficiate del manovra, e le function pituitari esseva deprimite sin le necessitate de craniotomia con su associate morbiditate e mortalitate.

0018041