702351

REPOSITORY ARGONNE/CHR
COLLECTION A. BRUES
BOX No. 18
FOLDER 41

Reprinted for private circulation from
CANCER RESEARCH
Vol. 18, No. 2, pp. 121-34, February 1958
Copyright 1958 by Cancer Research, Inc.
PRINTED IN U.S.A.

Pituitary Irradiation with High-Energy Proton Beams
A Preliminary Report*

C. A. Tobias, J. H. Lawrence, J. L. Born, R. K. McCombs, J. E. Roberts, H. O. Anger, B. V. A. Low-Beer,† and C. B. Huggins‡

(Donner Laboratory of Biophysics and Medical Physics, Donner Pavilion, and the Radiation Laboratory, University of California, Berkeley, Calif.)

Hypophyseal Proton Irradiation

An account is given below of the initial use of high-speed protons in human therapeutic investigations. The rationale for pituitary irradiation, the technic employed, and the initial physiological changes after proton irradiation of the pituitary gland are given in detail.

Roentgen irradiation of the human pituitary was performed by Gramegna in 1909 (43). Although experimental evidence suggests that overactive elements of the pituitary may be radiosensitive, statements in the literature seem to indicate that it is difficult, if not impossible, to influence the function of the normal pituitary by x-ray (27). Indeed, Crooke has stated that he has not observed histological changes in the human pituitary, even with fair amounts of irradiation (6). Because of the limitations imposed by the sensitivity of the skin and by the danger of injury to the brain, the doses of conventional roentgen irradiation have had to be small. Irradiation has been a frequently used therapeutic approach in pituitary tumors (37), Cushing's syndrome (16, 39), and acromegaly (15, 39). Attempts have also been made to irradiate the pituitary in various other conditions—for example, hypertension (14) and exophthalmos (4, 7). Roentgen irradiation has also been attempted for cancer in the human being, particularly by Murphy and Schwippert for prostatic carcinoma (38) and by Kelly *et al.* for mammary carcinoma (17). However, in three patients with mammary carcinoma, even 10,000 r to the region of the hypophysis was not sufficient to cause notable depression in hormone production, histopathological damage, or remission of the disease (17). The technic of roentgen irradiation is still being extended and improved, as exemplified by the recent work of Santos (45).

The pioneer work of Lacassagne and his associates (23), the implantation of radioactive seeds into the pituitary, seemed to offer an alternative method for delivering large amounts of irradiation; indeed, radon seed implantation did affect the pituitary in acromegaly and Cushing's syndrome (39). During the last few years Kisieliski and his associates have developed new methods for processing radioactive yttrium into seeds (21). This has led to the therapeutic clinical investigations of Kennedy *et al.*, who implanted several yttrium seeds into the pituitary to give considerable doses of beta-particle irradiation in an attempt to stop hypophyseal function and to cause regression of carcinomas. This study is still in progress at the University of Chicago and at McGill University (19). Colloidal radioactive chromic phosphate was deposited in the human sella turcica by Rothenberg *et al.* (44). Forrest and Brown used pituitary radon implants (11).

Recent advances in surgical technics and postoperative management have made hypophysectomy feasible. Luft and Olivecrona in Sweden have

* Various phases of this work were supported by the U.S. Atomic Energy Commission, the Donner Foundation, the U.S. Public Health Service, and the California State Cancer Fund.

The present communication is based on AEC Report UCRL 3035, July, 1955.

† Deceased, September, 1955.

‡ Director, Ben May Laboratory for Cancer Research, University of Chicago.

Received for publication May 20, 1957.

0017988

PARTIAL DOCUMENT

reported hypophysectomy on some 37 cases of metastatic carcinoma of the breast (30, 31) and on some twenty cases of severe diabetes mellitus (32, 33). Kennedy and associates at the University of Minnesota have reported twelve cases of breast cancer (18). Currently, Pearson *et al.* (40) and others (1, 8, 12, 20, 22, 29, 41, 42, 47) are vigorously attacking the problems of hypophysectomy in cancer and other diseases. Hypophysectomy, even in the hands of an expert neurosurgeon, is not always achieved completely and is a difficult procedure.

The development of the cyclotron, betatron, linear accelerator, and other machines has made possible the production of beams of particles with possible applications in teletherapy (2, 35). The interesting nature and characteristics of high-energy protons and deuterons were pointed out by Robert Wilson in 1946 (53), and at that time careful consideration was given to their possible value in teletherapy. Up until that time, the only heavy nucleons that had been used in experimental cancer therapeutical investigations were neutrons (24–26, 48, 49). However, these particles did not prove superior to x-rays or gamma rays. As soon as the first high-energy synchrocyclotron was completed by E. O. Lawrence and his associates and the internal beam successfully deflected, animal studies were initiated by us (50) with a view to eventual application to cancer and have continued to the present time.

The demonstration that hypophysectomy might be of benefit in the palliative treatment of various diseases such as advanced breast cancer, fulminating juvenile diabetes with retinopathy, malignant exophthalmos, and malignant hypertension prompted the inquiry into the possible use of the proton beam to destroy or inhibit the function of the pituitary gland. The technic was perfected by extensive animal investigation, in which both 190 Mev deuterons and 340 Mev protons were employed, but only the 340 Mev proton beam was used in attempts to destroy the human pituitary, first in patients with advanced metastatic breast cancer.

Proton Irradiation Technic

General properties of heavy particle beams.—High-energy protons, deuterons, and alpha particles have great advantages over other radiations in producing localized radiation damage in a deep region in tissue, as suggested by Wilson (53). The particles, when focused, travel in a straight beam with little divergence and may be directed to any portion of the body. A suitable aperture, made of brass or other metal, is used to define the shape and size of the beam. As the particles penetrate tissue, their scattering is very small compared with electrons, and for practical purposes negligibly small amounts of radiation fall outside the main beam. The background ionization may be kept to less than 0.1 per cent of the beam.

Furthermore, heavy monoenergetic particles penetrate to a uniform and well defined range, producing their maximum ionization just before stopping. The 340-Mev protons used in the present study have ample range to traverse the entire human cranium. An autoradiograph of this beam is shown in Figure 1 as it crosses a 6-inch thick, solid piece of lucite. The straight path of travel and the relative lack of scatter can be seen. These properties were early demonstrated in biological and medical experiments by Tobias, Anger, and Lawrence (50).

Biological experimentation.—Experience in the use of proton, deuteron, and alpha particle beams was gained by investigating their biological effectiveness and their mechanism of lethal action through localized irradiation of animal tissues. The relative biological effectiveness per unit of ionization of the high-energy portions of the deuteron and proton beams was found to be close to that of 200-kv. x-rays. This could be predicted from physical data on the specific ionization and linear energy transfer of the particles. Experiments of this kind were done on mice (50), yeast cells (55), and Tradescantia microspores (13).

The use of high-energy, heavy particles makes possible the production in the animal body of lesions with microscopically sharp demarcation lines (50). In small animals, cylindrical lesions 1 mm. in diameter are easily produced. Since 1952, a sustained effort has been made, in collaboration with the staff of the Institute of Experimental Biology of the University of California, to study effects of these high-speed particles on the rat hypophysis (51). Initial results were encouraging; and pituitary irradiation of young monkeys[1] and of normal, mature dogs[2] and dogs with mammary cancer[2] has been undertaken, by a technic similar to that for human beings (described below).

When large, single doses of more than 5,000 rad[3] of deuterons or protons are given to the pituitary glands of animals, progressive atrophy of the entire gland results, accompanied by reduction in physiological function. The end results appear within limits to be similar, regardless of the size

[1] In cooperation with Dr. G. Van Wagenen, of Yale University.

[2] To be published (in preparation).

[3] 1 rad = 100 ergs absorbed/gm, or 1.07 rep absorbed in tissue.

0017989

of the radiation dose. The higher the dose, the sooner the physiological effects become manifest. Single doses of the order of 30,000 rad are necessary to approximate the immediate effects of hypophysectomy. To illustrate, Chart 1 shows the apparent time of onset of physiological changes resembling complete hypophysectomy. Data on rats, dogs, and monkeys show the same general relationship. The chief criteria for evaluation of the extent of pituitary destruction are rate of growth, thyroid function, and sizes of target organs. The entire gland must be irradiated to achieve any lasting physiological changes in the target organs.

Thus, when single doses are applied, pituitary damage can be achieved with relatively moderate doses, although it may not be observed until fairly long after the radiation exposure. The delayed onset of the effects is a factor of great importance in deciding upon the amount of irradiation to be administered to human beings.

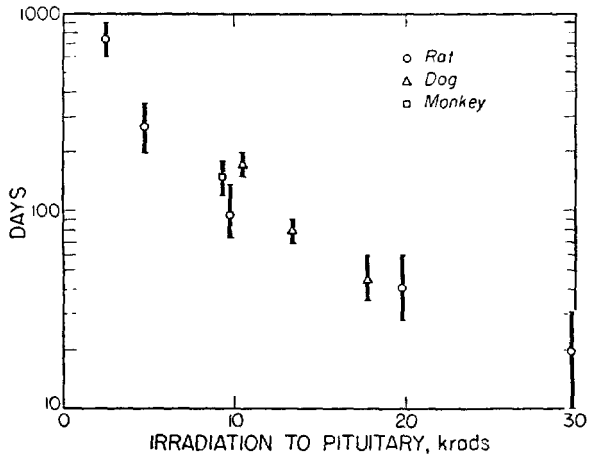

CHART 1.—Apparent time of onset of physiological changes resembling complete hypophysectomy following pituitary irradiation in the rat, dog, and monkey. Criteria used were measurements of growth rate and various target organ functions.

The effects of pituitary irradiation on target organs do not progress simultaneously, but there is a definite pattern involved. In rats the first gland to show measurable functional changes is the thyroid. The I^{131} uptake may decrease within a few weeks after even a moderate dose. Effects upon growth and adrenal function follow, while regression of the sex glands, regulated by the pituitary gonadotropins, is usually last. The histopathology of the irradiated pituitary exhibits changes that indicate a characteristic pattern (in the rat), although differential effects are difficult to evaluate quantitatively. The acidophiles seem to be the first to regress, followed by basophiles and then chromophobes.

Long-term studies with doses up to 10,000 rad given to young Long-Evans rats indicate that the frequency of spontaneous pituitary tumors is reduced and the time of onset is prolonged if the animals are irradiated in the 1st month of life. The life span of animals that received large doses did not differ significantly from the life span of hypophysectomized animals.

Nerve and brain tissue is more sensitive to radiation damage than pituitary tissue. Lethal effects from pituitary irradiation, when the cause could be definitely ascertained, could be ascribed

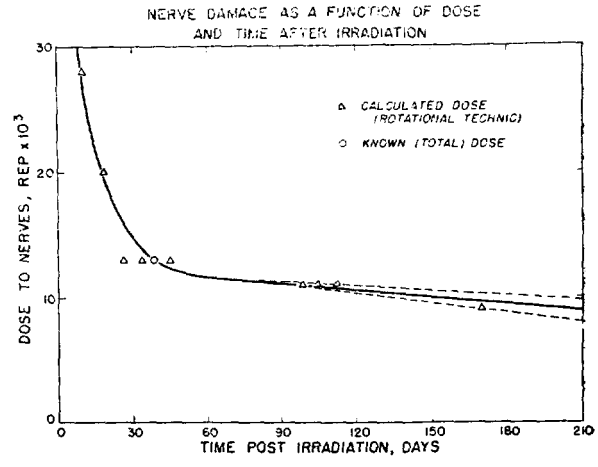

CHART 2.—Cranial nerve damage in the dog following proton irradiation of the pituitary.

to associated radiation-induced nerve and brain lesions, particularly to necrosis and hemorrhage. Lethal effects of this kind were usually preceded by damage to the third, fourth, and fifth cranial nerves, which lie very close to the pituitary in the dog. The lesions led to inability of the animals to move their eyelids, to permanently dilated pupils, and to loss of corneal sensitivity. A series of experiments was carried out to test the dose-time relationship in dog cranial nerve. There resulted a characteristic dose-time injury curve, which resembled the data obtained with the pituitary. The lower the dose, the longer the time required for the symptoms to appear and the less severe they usually were. Since the data on dogs are available for a period of only 30 months, additional information is needed, particularly for long postirradiation times. Chart 2 gives the data now available.

The available data indicate that brain damage is a function not only of dose and time but also of the volume of tissue irradiated. It is difficult to compare the literature on radiation damage to the

0017990

brain with the results reported here, since most data in the literature involve irradiation to extensive volumes of brain tissue, whereas in the present work relatively small volumes receive large quantities of irradiation (9, 34). Perhaps most pertinent are the recent observations by Arnold *et al.*, who observed delayed demyelinzation and radionecrosis in the dose ranges of 1,500–5,000 r of high-energy x-rays and, in addition, acute inflammation, hemorrhage, edema, and necrosis in the range of 3,000 to 14,000 r, with increasing severity at higher doses (3).

We and our associates had occasion to use the proton beam to irradiate the pituitary glands of several dogs with spontaneous metastatic mammary adenocarcinoma.[4] In five of fifteen such animals, definite regression or arrest of growth of the tumors was noted several weeks after irradiation. The disease process has apparently been arrested recently in one animal for over 30 months. Several of the dogs irradiated without benefit had open, infected, ulcerating tumors when placed under our care and died soon thereafter.

Treatment Schedule, Control of Proton Beam, and Dose Distribution in Human Patients

In the course of the present preliminary investigations the irradiation was given by a multiple-plane, rotational technic to minimize the dose to radiosensitive tissues within the cranium. The most sensitive structures are directly above the pituitary—particularly the optic tract and the hypothalamus. These should be avoided by the radiation as much as possible. Laterally, the carotid artery and the cavernous venous plexus are located near the hypophysis. These structures are known to tolerate a higher dose than nerve tissue. Of the cranial nerves, the third, fourth, fifth, and sixth are closest. Beyond the cranial nerves extend the temporal lobes of the brain, and close to the hypophysis are the regions subserving the sense of smell.

Proton irradiation of the human pituitary was combined with the well known rotational irradiation technic. The position of the proton beam was kept fixed in space and directed to cross the pituitary as well as the entire head with uniform ionization. During irradiation the patient's head was rotated to the right and left with the axis at the center of the pituitary body. The axis of the rotation was also varied over a wide range of angles, as shown in Chart 3. In this manner, the cumulative dose to the pituitary gland was considerable, while surrounding blood vessels, cranial nerves, lobes of the brain, bone, and skin received progressively less irradiation in the order of enumeration.

The alignment of the beam and rotation of the head were accomplished by the following technic:

The beam passed along an optical bench in a line 8 inches above the center of, and parallel to, the track of the bench. A dose-monitoring ionization chamber, a beam-collimating aperture, and the focal spot of a diagnostic x-ray machine were all mounted on the track so that the proton beam passed through their respective centers. The patient's head was held rigid in an adjustable head rotator, which was also mounted on the optical bench. Adjustment screws were provided to move the head in three directions—X (along the axis of the patient's body), Y (in the postero-anterior direction), and Z (laterally)—with an index on each adjustment so that on subsequent irradiation sessions the patient's position could be reset. The alignment of the patient's head was checked by means of roentgenograms before each session, and adjustments were made when necessary (see Charts 3 and 4).

The success of the technic depended on providing a firm mask to hold the patient's head during alignment and irradiation on repeated occasions. Very satisfactory, two-piece individual plastic masks were developed for this purpose, utilizing fiber-glass cloth and polyester resin. The mask was tightened on the head with thumbscrews until it fitted tightly enough so that the patient could not move her or his sella turcica more than about 0.5 mm. in any direction. The masks were comfortable enough to wear up to 2 hours at a time.

Figure 2*a* shows a diagnostic roentgenogram of the sella turcica of one of the patients in alignment with the cross-hairs, while Figure 2*b* shows the radiograph of the shaped beam and its alignment with the sella. This latter view was taken by first exposing the plate to the x-rays, then momentarily turning on the proton beam. One should bear in mind that on the original radiograph the sella appeared enlarged because of divergence of the x-rays from the focal spot of the x-ray machine, while the beam spot was actual size.

A vertical diagnostic x-ray film was taken along the Y axis. Here the center of rotation in the sella was ascertained by obtaining symmetry, on both sides of the X cross-hair, of the faint line representing the base of the sella and the walls of the sphenoid sinuses. The anterior clinoid processes and medial margins of the orbits were also checked for symmetry (Fig. 3).

Alignment of both views of the sella with the cross-hair was usually within ± 0.5 mm. Occasionally check x-rays were made, with the patient

[4] To be reported in detail (in preparation).

0017991

forcibly trying to move the head out of alignment. These were always correct to within 1.0 mm.

The limits of rotation of the head about the body axis (X) were chosen as $\pm 30°$ or $\pm 35°$ from the vertical line of symmetry (Y). These values were selected because of the need for avoiding the eyes completely, so that the cornea, retina, and lens would not be irradiated. There were eleven planes of irradiation, which were about 7.5° apart. The choice of the treatment planes was such that the brain stem and the pars optica, mammillary bodies, tuber cinereum, and infundibulum received negligible radiation, since the beam did not cross these at any time.

The elliptical beam apertures, multiple planes, and rotation make the determination of isodose curves a complex procedure. Two methods were utilized: measurement by photographic densitometry and calculation from the known beam ionization profile.

In the first procedure a lucite phantom was used in place of the head, and photographic film inside this phantom was exposed to the beam, using the same rotations as for patients. One set of exposures with rotation corresponding to an entire irradiation schedule is given in Figure 4 (reproduced without retouching). The blackened area corresponds to the size of the pituitary gland.

Dose distributions along the major axes X, Y, and Z, obtained by film dosimetry, are given in Chart 4. The dose falls relatively slowly in the lateral, or Z, direction, where the hypophysis ex-

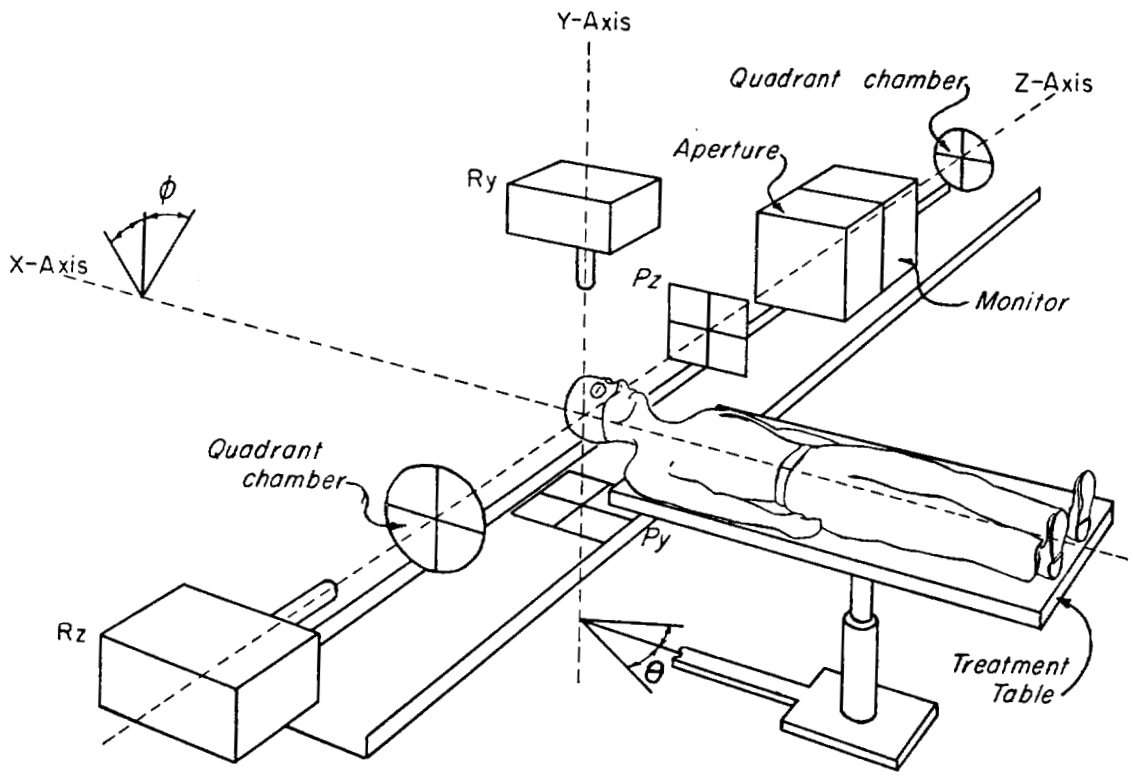

CHART 3.—A schematic drawing of the apparatus for proton irradiation of the human hypophysis

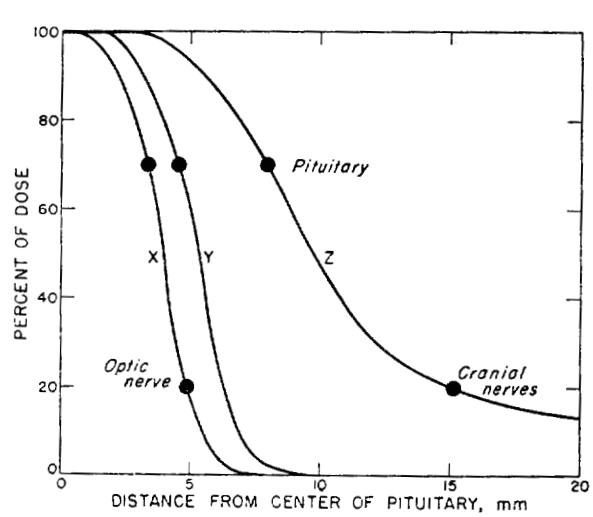

CHART 4.—Proton dose distribution along the three axes of the cranium, in terms of the peak dose at the center of the hypophysis.

0017992

tends farther. Toward the top of the head (X axis) and to the front and back (Y axis), the fall is very abrupt, insuring a considerable degree of protection for the optic chiasm and hypothalamus.

It is useful to evaluate the average hypophyseal dose by integrating over the isodose surfaces. The average dose in the pituitary of the patients irradiated thus far has been between 55 per cent and 75 per cent of the peak dose at the center of the gland. The size and shape of the sella turcica vary considerably among patients, and several different apertures and rotations have been used.

TABLE 1

PREVIOUS MEDICAL AND SURGICAL TREATMENT OF PATIENTS

Mastectomy	23
Oophorectomy	19
Adrenalectomy	16
Estrogen, androgen	13
Roentgen therapy	22

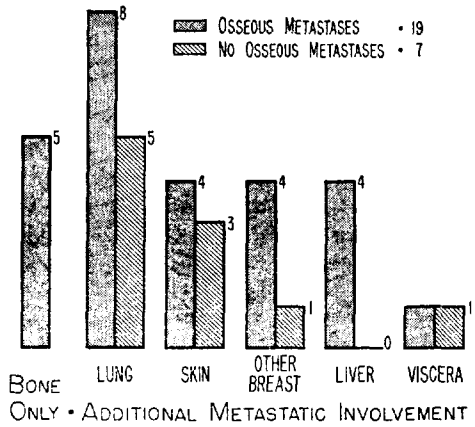

CHART 5.—Metastatic involvement at the time of entry

To minimize permanent damage to capillaries and blood vessels in human beings, the well known radiological procedure of delivering fractionated doses was followed. Partial justification for this procedure was obtained by comparing dogs receiving single doses with dogs given fractionated exposures. In the latter group hemorrhage occurred, but only at much higher doses.

Most patients received average dose rates of 200–300 rad/min. The beam was delivered in the form of microsecond pulses about 68 times/second. The instanteous rate therefore was very high.

In a full course of irradiation the patient received less than 20 rad total-body dose, most of which was radiation near minimum specific ionization. Beyond a radius of 1.5 inches from the beam, the whole body of the patient received everywhere less than 0.1 per cent of the peak dose.

SELECTION OF PATIENTS

Twenty-six patients with metastatic breast carcinoma received pituitary proton irradiation.[5] These patients were carefully selected according to the following criteria: (*a*) The generally accepted forms of surgical and radiological treatment had to have been tried or determined to be of no benefit to the patient. (*b*) There had to be objective evidence for the presence of progressive metastatic lesions. (*c*) The response of the patient to palliative procedures such as oophorectomy, adrenalectomy, or endocrine therapy had to have been evaluated and, when deemed of more immediate benefit in extending the life or comfort of the patient, accomplished prior to acceptance of the patient for pituitary irradiation.

The patients ranged in age from 27 to 70 years, the average age being 46.6 years. The duration of their illness from the time of histological diagnosis to pituitary irradiation varied between the extremes of 0.1 year and 13.5 years, with an average of 4.7 years.

A summary of the medical and surgical treatment undergone by the 26 patients in this series prior to receiving pituitary irradiation is represented in Table 1. Thirteen of the earlier patients irradiated had previously had bilateral adrenalectomy and oophorectomy, many with remissions lasting from several months to several years. Two-thirds of all the patients were rapidly failing at the onset of pituitary irradiation and could be classed as terminal.

All the patients had metastatic lesions at the time of entry, as shown in Chart 5. Nineteen patients had metastases to bone, and at least twelve of these had additional metastases to other organs. The seven patients without osseous metastases had metastatic involvement of the lung, liver, skin, other breast, or viscera.

During irradiation the patients were hospitalized in the Donner Pavilion. They returned at intervals of from 3 to 4 months for follow-up studies whenever possible. The patients came from all parts of the United States; and this created definite problems in obtaining follow-up studies, particularly since it was desired that all follow-up laboratory and other studies be done at Donner Laboratory to insure uniformity and continuity.

[5] Pituitary proton irradiation was also administered to four patients with the following diseases: (*a*) acute lymphatic leukemia, (*b*) embryonal dysgerminoma of the testis, (*c*) chronic lymphatic leukemia and diabetes mellitus, and (*d*) malignant exophthalmos. Data from these patients are not included in the present report. In the patient with malignant exophthalmos the loss of sight was so imminent that surgical removal of the upper orbit was necessary shortly after proton irradiation, and the effect of proton irradiation could not be observed.

0017993

SCHEDULE OF PITUITARY IRRADIATION

Proton irradiation to the pituitary was given in fractionated doses 3 times a week. The earlier patients in the series were started on small doses of irradiation, and the course of irradiation covered a protracted period. The total amount of irradiation given was also small compared with that received by the later cases. As this study proceeded and the effects were observed, the amount of irradiation administered to the hypophysis at a single time and the cumulative total were increased, while the time required for the entire course of irradiation was shortened. This is shown in Chart 6. Thus, the first patient received 14,000 rad over a 63-day interval, while some of the later patients received as much as 30,000 rad in six sessions within a 2-week period.

Several patients complained of immediate post-irradiation head pain. This could be ascribed to manipulation of the neck during rotation or to

PITUITARY IRRADIATION SCHEDULE

	Cumulative Total Rads	Irradiation Interval, Days	Rads per Session, Maximum	Rads per Plane, Maximum
EARLY PATIENTS	14 000	63	650	150
LATE PATIENTS	30 000	14	5000	1000

CHART 6.—Schedule of proton irradiation of the human hypophysis.

pressure from the head mask. Neither during nor after irradiation did patients experience auditory or visual auras. One patient has recently developed syncopy preceded by an olfactory aura. No indications of increased intracranial pressure, as manifested by papilledema, hyperthermia, vomiting, or vasomotor changes, were noted. No electrolyte disturbances were detected following irradiation sessions.

A few weeks following completion of irradiation, five patients, those receiving the heaviest levels of irradiation, developed severe head pains lasting for a few days. The pains were usually said to be throbbing, sharp, deep within the skull, and relieved by aspirin. In all cases they soon disappeared completely. There was a striking resemblance to the headaches described in acromegaly and other pituitary disorders.

CHANGES IN PITUITARY FUNCTION

The most valuable criteria for assessing the changes in pituitary function following pituitary irradiation have been uptake of radio-iodine by the thyroid gland and 24-hour urinary pituitary gonadotropin excretion.

Radio-iodine uptake.—Chart 7 shows the changes in radio-iodine uptake following pituitary irradiation. Of eighteen patients for whom sufficient data are available there was marked depression of iodine uptake in eleven, in some instances reaching values as low as 5 per cent, which is in the range observed following hypophysectomy (28).

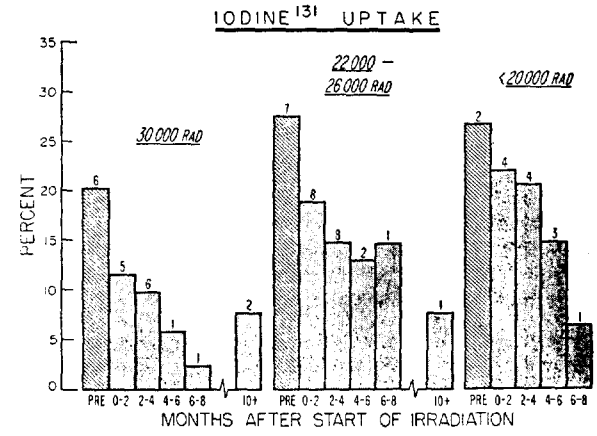

CHART 7.—The 24-hour thyroid radioiodine uptake following pituitary irradiation at various dosage levels. The figure above each column designates the number of patients in that group.

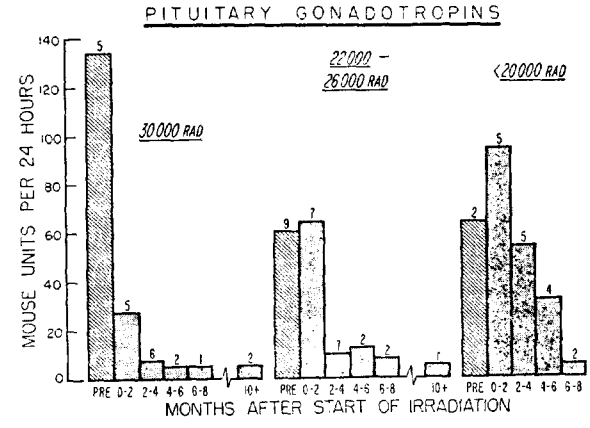

CHART 8.—The 24-hour urinary pituitary gonadotropin excretion following pituitary irradiation at various dosage levels. The figure above each column designates the number of patients in that group.

In six patients there was no significant change, although in four of these six it was initially low. In one patient there was a slight rise.

Gonadotropin excretion.—Chart 8 shows the changes in 24-hour urinary gonadotropin excretion following pituitary irradiation with reference to dose and time. In eight of sixteen patients for

0017994

whom complete data are available, there was a marked drop in gonadotropin excretion. This was usually apparent by the time the course of irradiation was completed, falling to zero or near zero in from 8 to 12 weeks following irradiation. In six patients there was no change in gonadotropin excretion, but in these the excretion was initially at the lowest concentration detectable (5 mouse units). Only one patient showed a rise in excretion.

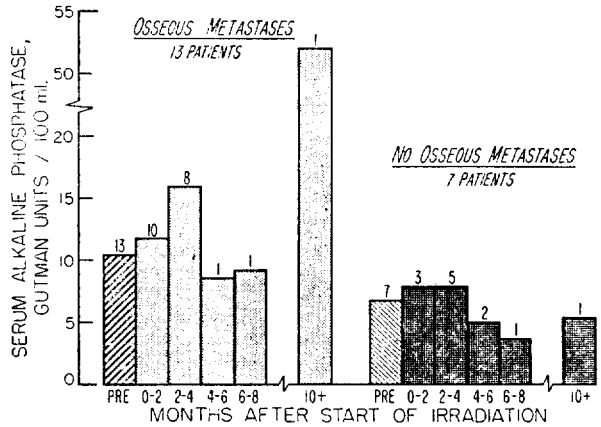

CHART 9.—Changes in serum alkaline phosphatase following pituitary irradiation.

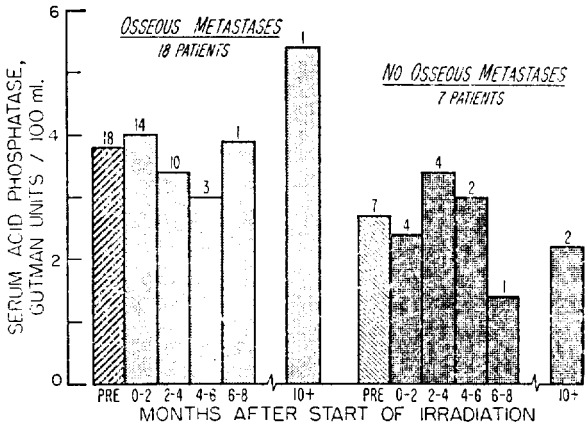

CHART 10.—Changes in serum acid phosphatase following pituitary irradiation.

In three patients gonadotropin excretion rose during the course of irradiation, later dropping to a level below normal. The elevation was not greater than could be accounted for by the inexactness of the bioassay.

Comparison of Charts 7 and 8 shows that the fall in gonadotropin excretion occurs somewhat sooner than the fall in I^{131} uptake. This is, of course, not surprising, since a decrease in gonadotropin production is a direct effect of pituitary damage, whereas depression of I^{131} uptake is a secondary effect.

BIOCHEMICAL CHANGES AFTER IRRADIATION

Protein-bound iodine.—The protein-bound iodine showed no consistent change following irradiation. In a few instances it rose to very high values, despite a drop in the I^{131} uptake. This unusual finding is under study.

Serum alkaline-acid phosphatases.—In the absence of osseous metastases and primary liver disease the elevation of serum alkaline phosphatase strongly suggests metastatic liver involvement (36). Conversely, in the absence of primary liver disease and metastatic liver involvement, elevation of serum alkaline phosphatase suggests an increase in regenerative activity in the bones at the sites of metastatic deposits (54).

Chart 9 shows the changes in serum alkaline phosphatase in patients with osseous metastases

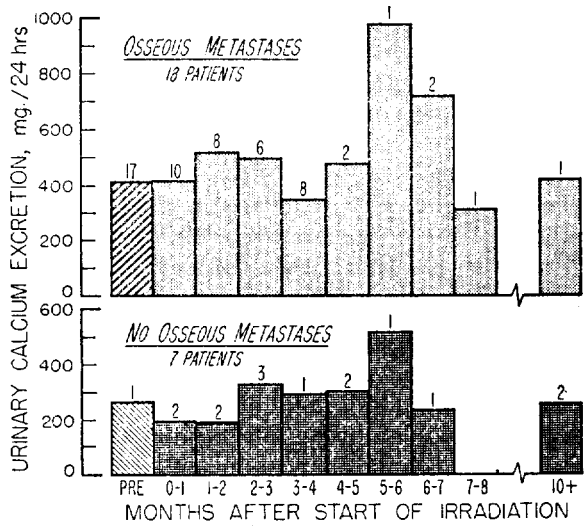

CHART 11.—Changes in 24-hour urinary calcium excretion following pituitary irradiation.

but without clinical or laboratory evidence of liver involvement. Data for patients without osseous metastases are included for comparison. Chart 10 shows the changes in serum acid phosphatase in the same patients. There appeared to be no good correlation between changes in the phosphatases and roentgenological evidences of healing of bony lesions.

Urinary calcium excretion.—On unregulated diets there was a significant decrease in urinary calcium excretion in two patients out of twenty. Both had osseous metastases. Those who did not have metastases to bone had normal levels of urinary calcium excretion both before and after irradiation. Values for urinary calcium excretion are summarized in Chart 11.

0017995

Serum calcium.—The serum calcium was elevated in only three patients, all of whom sustained pathological fractures; and here simultaneous hypercalciuria was observed.

Urinary corticosteroid excretion.—Charts 12 and 13 show the changes in 24-hour urinary 17-hydroxy- and 17-ketosteroid excretion. Sixteen patients in these groups were without adrenals and required replacement therapy, generally constant in amount. As noted below, all the other patients were given adrenal corticoid replacement therapy as needed following irradiation. In the patients with intact adrenals (some with intact ovaries)

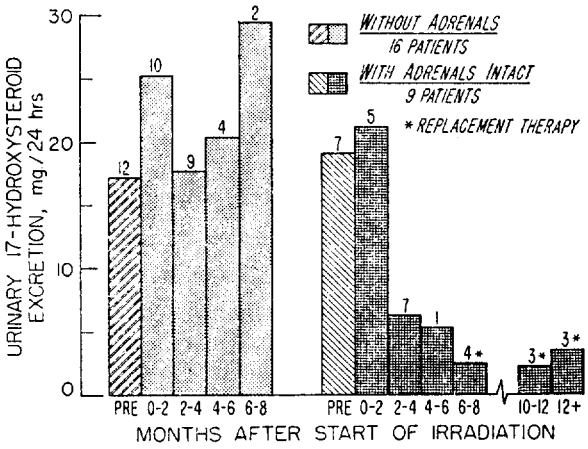

CHART 12.—Changes in 24-hour urinary 17-hydroxysteroid excretion following pituitary irradiation. The figure above each column designates the number of patients in that group.

there seems to be a significant fall in the urinary 17-hydroxysteroids and a probable fall in the 17-ketosteroids.

Urinary estrogen excretion.—Data on urinary estrogen excretion are meager, but in two patients with intact adrenals and ovaries, both of whom received the highest level of irradiation, and for whom data are available before and after irradiation, there was a definite drop.

Total body sodium.—These studies were performed with Na^{24} and K^{42}, whenever permitted by the availability of the radioisotopes and absence of gamma-ray interference with other isotopic studies. In two patients the body sodium rose following irradiation, whereas in a third patient it dropped; no conclusion can, therefore, be drawn. However, since many of these patients had had previous adrenalectomies and most were in a serious condition, no steady state was usually present, and, therefore, the data are not presented at this time.

Total body water.—Body-water determinations using tritium-labeled water have shown a drop in the fraction of total-body weight contributed by water. Chart 14 shows the changes.

Hematological changes.—Nine months after irradiation two patients without demonstrable osseous metastases or occult blood loss showed moderately diminished red-cell counts, hemoglobins, and total red-cell volumes, but normal plasma volumes. Whether this is related to a pituitary eryth-

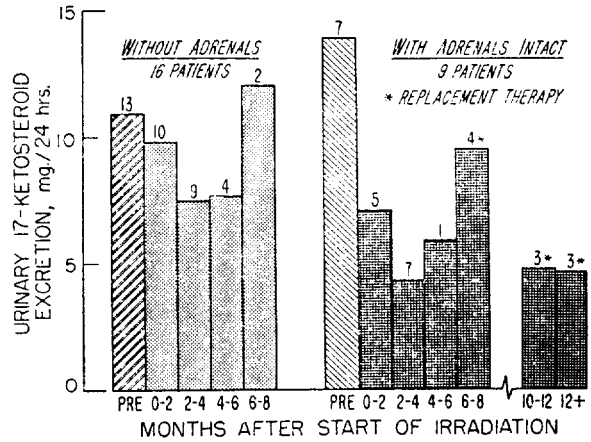

CHART 13.—Changes in 24-hour urinary 17-ketosteroid excretion following pituitary irradiation. The figure above each column designates the number of patients in that group.

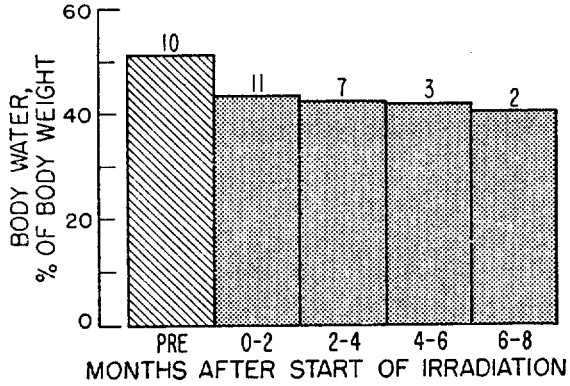

CHART 14.—Changes in total-body water following pituitary irradiation. The figure above each column designates the number of patients in that group.

ropoietic factor deficit is now under investigation (52). Studies on the rate of red-cell production and duration of red-cell life were carried out on several patients with the use of Fe^{59} and glycine-C^{14}, but the findings seem to be related to the presence of neoplasm and not to pituitary irradiation (5, 10).

ROENTGENOLOGICAL CHANGES

Serial skeletal and chest surveys have been made regularly in all patients. In five, three of whom were adrenalectomized and oophorecto-

0017996

mized, and one oophorectomized only, there was unmistakable evidence that some of the osseous metastases were calcifying; and in two others the osseous metastases remained stationary for several months. In one patient, with intact ovaries and adrenals, recurrent pleural effusion, with demonstrable tumor cells, resolved after irradiation and has not recurred at this writing (19 months after proton irradiation). In three others, pulmonary metastases remained stationary for as long as 1 year after irradiation; one of these had intact ovaries and adrenals.

Clinical Changes

Three patients developed diabetes insipidus, which was managed satisfactorily by vasopressin tannate in oil, then by posterior pituitary principle nasal insufflation. With respect to the criteria for panhypopituitarism, as laid down by Sheehan and Summers (46), our patients have not shown complete loss of pubic or axillary hair, absence of normal skin pigmentation, thinning of the eyebrows, absence of sweating, or loss of normal oiliness of the axillae. Several patients became lethargic and weak, despite what was considered to be adequate replacement therapy; and it was not known whether this was ascribable to the progression of their disease or to pituitary suppression. The initial breast lesion in one patient over a period of several months changed markedly in consistency and size so as to be no longer palpable. The affected portion of the breast became freely movable from the underlying tissue. Biopsy, however, still disclosed the presence of tumor cells.

One patient with abdominal carcinomatosis had required, prior to irradiation, frequent paracenteses; during a surgical attempt at adrenalectomy and oophorectomy, the intra-abdominal metastases were found to be so extensive as to preclude this procedure, and she was therefore selected as a candidate for pituitary irradiation. At the time of beginning pituitary irradiation paracentesis of 3,500 cc. of fluid was done, and 7 mc. of colloidal chromic radiophosphate was instilled into the peritoneal cavity. The patient did not require paracentesis in the year which elapsed after irradiation until her death. Until the final 2 months of her life her general physical improvement was marked, with weight increase and disappearance of nausea, vomiting, and anorexia. There was no apparent progression of her disease before these last 2 months.

With radiation levels of 26,000 rad and higher, third, fourth, and sixth cranial nerve palsies have been observed. These have remained stationary or improved and have not been a serious problem to the patients. One patient receiving 30,000 rad has developed uncinate fits, which have been controlled satisfactorily by anticonvulsant therapy. Patients who received 22,000 rad or more developed linear epilated areas over both temporal regions, usually within a month after exposure. The hair regrew in the ensuing months; and no erythema, ulceration, or bronzing of the skin has been noted.

Subjective Changes

Fourteen of the nineteen patients with osseous metastases had skeletal pain. Following pituitary irradiation, seven of these patients had some diminution of their pain as indicated by increased mobility and decrease or discontinuance of narcotics. One patient was for a time able to walk without a cane. Another, who had been bedridden for some 6 months, was able for a time to move about in a walker. Five patients showed no response. The alleviation of pain from bony metastases could not be correlated with objective evidence of improvement.

Replacement Therapy

An uninterrupted maintenance schedule of deoxycorticosterone acetate and cortisone was continued, of course, for adrenalectomized patients, although a few were changed from cortisone to prednisone after the introduction of the latter. Upon the clinical appearance of the need for adrenal replacement among the patients with intact adrenals prednisone, or, later, prednisolone, 10 mg. daily, was started, with satisfactory response. Four patients appeared to be mildly myxedematous, and they, together with several others, were given thyroid extract, 1–2 grains daily. Several patients who, prior to pituitary irradiation, had been started on testosterone by their physicians, continued receiving it. In these patients testosterone had been unsuccessful in preventing the progression of metastases, and it was continued only for its possible benefit in promoting protein anabolism. Pitressin was given to three patients as previously mentioned.

Surviving Patients

There are two patients surviving from the series of 26 at the time of writing. Both are 20 months postirradiation, and one is still in an excellent state of remission.

Survival statistics on all patients in the series are shown in Table 2. The table also indicates the arrests and remissions obtained following pituitary irradiation and their duration. In assessing the results of pituitary irradiation we have used the assumption of Woodard *et al.* that cancer of the

0017997

TABLE 2

SURVIVAL STATISTICS

Age of patient	Metastases	Status at entry	Previous therapy*	Total dose (rads)	Irradiation time interval (days)	Post-irradiation survival (months)	Estimated duration of arrest or remission (months)
47	Bone Lung?	Advanced	M,X,H A,O	14,000	63	6	0
48	Bone Lung?	Advanced	M,X,H A,O	13,000	40	4	3
50	Bone Viscera Breast	Advanced	M,X,H A,O	16,500	50	4	0
55	Skin	Advanced	M,X,H A,O	18,000	52	5	0
27	Bone Liver	Early metastatic	M,X A,O	20,000	45	2	0
43	Lung Skin	Moderately advanced	M,X A,O	17,000	25	21	10
44	Bone Lung	Moderately advanced	M,X,H A,O	13,000	18	6	0
43	Bone Lung	Advanced	M,X A,O	9,000	12	0	0
43	Bone	Moderately advanced	M,X,H A,O	22,000	33	10	0
46	Bone	Advanced	M,X,H A,O	22,000	32	2	0
43	Bone Lung	Advanced	M,X A,O	26,000	31	8	3
44	Bone Lung?	Nearly terminal	M,X,H A,O	30,000	24	3	0
70	Bone Lung Skin	Advanced	X,H A,O	26,000	21	8	6
55	Bone Lung Breast	Advanced	M,X,H A,O	30,000	17	5	3
Note: This patient also had a uterine carcinoma							
34	Bone Skin Breast	Early metastatic	M,H,O	30,000	14	6	3
37	Lung? Bone Liver	Nearly terminal	M,X A,O	32,000	14	1/4	0
51	Lung	Early metastatic	M,H	30,000	21	(L)† 17	17
41	Bone	Advanced	M,H x-ray castration	26,000	12	7	0
55	Lung	Early metastatic	M	26,000	12	6	0
31	Bone	Moderately advanced	X,H	22,000	10	(L)† 17	4
41	Bone, Lung Liver, Skin	Advanced	M,X,H A,O	21,000	9	2	0
49	Omentum Bone, Lung?	Advanced	M	30,000	21	14	12
41	Liver, Skin Breast	Advanced	M,X,H A,O	26,000	12	7	3
54	Lung Skin Breast	Advanced	X,O	30,000	14	3	0
28	Bone Lung	Early metastatic	M,X	22,000	11	1	0
52	Lung Skin	Nearly terminal	M	28,000	12	1/2	0

* M = mastectomy; A = adrenalectomy; O = oophorectomy; X = x-ray therapy; H = estrogen and/or testosterone.
† (L) = Living.

0017998

breast, if untreated, will show measurable progression in 4–5 months (54). Subjective improvement is not considered sufficient as a criterion of benefit.

Twenty-two of the 24 deceased patients have come to necropsy. General autopsy findings will not be discussed here. Of primary interest are the necropsy findings of the effects of pituitary irradiation upon the pituitary gland and the target organs.

There was a marked difference in the pituitaries of those patients who received low, medium, and high levels of irradiation. Low levels of irradiation were considered as ranging from 13,000 through 19,000 rad; medium, from 20,000 through 26,000 rad; and high, above 26,000 rad. Pituitary damage resulting from proton irradiation was discernible on cut section in those patients receiving the medium and high levels of irradiation who survived for sufficient time for necrosis to be grossly apparent. Generally, this time was approximately 5 months. Microscopic evidence of histological damage was apparent in all patients who received over 20,000 rad, regardless of the time interval between irradiation and death. Among those receiving less than 20,000 rad, necrosis in the histological sections was encountered infrequently; and the moderate degree of fibrosis, shrinkage of cells from the basement membrane, and increased vascularity were not considered confirmatory of irradiation damage. Figures 5 and 6 are photomicrographs of histological sections of pituitaries from patients receiving higher levels of pituitary irradiation.

An example of the destructive effect of proton irradiation upon the pituitary gland is shown in Figure 7, which illustrates the sella turcica and pituitary of a patient who received 30,000 rad in a period of 14 days and survived 14 months.[6] There appeared to be nothing whatever in the sella. Dissection produced only a lining 1-ml. thick in the sella. This pituitary remnant, together with its investing membranes, is shown in Figure 8.[6] The microscopic section is shown in Figure 9. Figure 10 shows the brain, shiny and glistening, demonstrating no evidence of the terrific bombardment which destroyed the pituitary.[6]

Thyroid.—Histologically, the thyroid glands in all patients showed involution at all levels of irradiation irrespective of the interval between irradiation and death, with the exception of two cases, one in which the patient died before irradiation could be completed and the other in which the patient survived only 12 days. Microscopic examination of the thyroid further showed that the acini were distended with old colloid material and that the epithelium was low-cuboidal in type.

[6] Photographs by Mr. Barry Evans, Berkeley, Calif.

Photomicrographs of thyroid sections from the patients whose pituitaries appear in Figures 5 and 6 are shown in Figures 11 and 12. Neither of these patients received thyroid extract.

Adrenals.—Microscopic examination of the adrenal glands could lead to no definite conclusions, because supportive steroid therapy was given. Evidence of adrenal atrophy in four of the seven patients coming to necropsy with intact adrenals could be ascribed to large doses of cortisone given in the terminal stages. Three of the seven showed tumor infiltration.

Ovaries.—Only five of the cases coming to autopsy had intact ovaries. The atrophy noted in four of these could not be considered as exclusively of pituitary origin, since one of the patients had had x-ray castration and three had had testosterone terminally. The ovaries of the fourth and fifth patients were heavily invaded with tumor.

Brain and cranial nerves.—No gross evidence of injury has been detected in the brain or cranial nerves. Preparation of these specimens is kindly being done by Dr. Nathan Malamud.[7] The results will be reported later. Of the first fourteen cases studied, there has been no evidence of irradiation damage to the brain, and no optic nerve or hypothalamic damage has been seen.

SUMMARY

There has been described a multiple-plane, rotational technic for irradiation of the human pituitary gland with the 340-Mev proton beam from the 184-inch synchrocyclotron. Peak doses of 14,000–30,000 rad at the center of the pituitary have been administered to 26 patients with metastatic breast cancer, and decreased pituitary function and gross and microscopic damage of the pituitary gland have been demonstrated. The most common laboratory findings were depression of I^{131} uptake by the thyroid and decrease of 24-hour urinary gonadotropins. There was clinical evidence of improvement in a few of the patients treated. Four patients with acute lymphatic leukemia, embryonal dysgerminoma of the testis, chronic lymphatic leukemia and diabetes mellitus, and malignant exophthalmos have also been irradiated, but they are not reported in detail at this time.

ACKNOWLEDGMENTS

The authors are indebted to Victor Burns, Graeme Welch, Betty Ward, R. W. Pratt, Jack Allen, and Ann Henderson for assistance at the cyclotron; to Shirley Belknap and Barbara Boysen for laboratory assistance; to Joseph Garcia, Charles Riggs, Julian Henry, and O. K. Anderson for preliminary

[7] Associate Clinical Professor of Neuropathology, Department of Pathology, University of California School of Medicine, San Francisco.

0017999

studies of irradiation involving animals; to Philip Bean for engineering design work on the equipment; and to Aram Thomasian for his contribution to the mathematical calculations. The use of the cyclotron was made possible by the kind cooperation of Professors Robert Thornton, Marvin Martin, Elmer Kelly, James Vale, the cyclotron crew, the accelerator technicians, and the electronics group. Finally, the study would have been impossible without the tireless efforts of the physicians who referred patients for irradiation and gave splendid cooperation in following the patients and securing pathological examinations.

REFERENCES

1. ALBEAUX-FRENET, N.; GUILOT, J.; BRAUN, S.; and ROMANI, J. D. Results of Surgical Hypophysectomy in a Case of Malignant Edematous Exophthalmos. J. Clin. Endocrinol., **15**:1239–46, 1955.
2. ARNOLD, A.; BAILEY, P.; HARVEY, R. A.; HAAS, L. L.; and LAUGHLIN, J. S. Changes in the Central Nervous System Following Irradiation with 23-Mev X-rays from the Betatron. Radiology, **62**:37–44, 1954.
3. ARNOLD, A.; BAILEY, P.; and LAUGHLIN, J. S. Effects of Betatron Radiations on the Brains of Primates. Neurology, **4**:165–78, 1954.
4. BEIERWALTES, W. H. X-ray Treatment of Malignant Exophthalmos: A Report on 28 Patients. J. Clin. Endocrinol., **13**:1090–1100, 1953.
5. BERLIN, N. I.; LAWRENCE, J. H.; and ELMLINGER, P. J. Recent Advances in the Knowledge of Total Red Cell Volume, Production, and Destruction. Blood, **12**:147–64, 1957.
6. CROOKE, A. C. In Symposium on Indications for and Effects of Irradiation of the Pituitary Gland. Brit. J. Radiol., **197**:135–37, 1944.
7. DAILEY, M. E.; GORDAN, G. S.; HOGAN, J. M.; LOW-BEER, B. V. A.; and NAFFZIGER, H. C. Pituitary Irradiation for Bilateral Progressive Exophthalmos. J. Clin. Endocrinol., **14**:673–75, 1954.
8. DECOURT, J.; MICHARD, J.-P.; WEIL, B.; and BAULIEU, E. Étude clinique et biologique d'une hypophysectomie total pratiquée au cours d'une récidive d'épithélioma mammaire avec métastases. Bull. et mém. Soc. méd. hôp. Paris, **70**: 699–706, 1954.
9. DUGGER, G. S.; STRATFORD, J. G.; and BOUCHARD, J. Necrosis of the Brain Following Roentgen Irradiation. Am. J. Roentgenol., **72**:953–60, 1954.
10. ELMLINGER, P. J.; HUFF, R. L.; TOBIAS, C. A.; and LAWRENCE, J. H. Iron Turnover Abnormalities in Patients Having Anemia: Serial Blood and *in vivo* Tissue Studies with Fe^{59}. Acta haemat., **9**:73–96, 1953.
11. FORREST, A. P. M., and BROWN, D. A. Pituitary Radon Implant for Breast Cancer. Lancet, **268**:1054–55, 1955.
12. FRESHWATER, D. B.; CRUE, B. L.; SHELDEN, C. H., and PUDENZ, R. H. A Technique for Hypophysectomy. California Med., **84**:229–33, 1956.
13. GILES, N. H., and TOBIAS, C. A. Effect of Linear Energy Transfer on Radiation-Induced Chromosome Aberrations in Tradescantia Microspores. Science, **120**:993–94, 1954.
14. HUTTON, J. H.; CASE, J. T.; FURLY, W. W.; FAHLSTROM, S.; CULPEPPER, W. L.; and MADDEN, E. E. Endocrine Factors in Hypertension: Treatment by Roentgen Irradiation of the Pituitary. Radiology, **52**:818–28, 1949.
15. JOHNSEN, S. G. Large Roentgen Doses in Acromegaly. Acta med. Scandinav., **144**:40–61, 1952–53.
16. ———. Roentgen Irradiation of the Pituitary in Cushing's Syndrome. Ibid., pp. 165–88.
17. KELLY, K. H.; FELDSTED, E.; BROWN, R. E.; ORTEGA, P.; BIERMAN, H. R.; LOW-BEER, B. V. A.; and SHIMKIN, M. B. Irradiation of the Normal Human Hypophysis in Malignancy. J. Nat. Cancer Inst., **11**:967–83, 1951.
18. KENNEDY, B. J.; PEYTON, W. T.; and FRENCH, L. A. Total Hypophysectomy in Advanced Breast Cancer. Bull. Univ. Minn. Hosp., **26**:528–51, 1955.
19. KENNEDY, T.; RASMUSSEN, T.; and HARPER, P. V. The Use of a Beta-Ray Source for Destruction of the Hypophysis. Surg. Forum, **4**:681–86, 1953.
20. KINSELL, L. W.; LAWRENCE, L.; BALCH, H. E.; and WEYAND, R. Hypophysectomy in Human Diabetes. Diabetes, **3**:358–66, 1954.
21. KISIELISKI, W.; SVIHLA, G.; and BRUES, A. M. Preparation of Radioactive Glass Beads. Science, **112**:400–401, 1950.
22. KNOWLTON, A. I.; POOL, J. L.; and JAILER, J. W. Lack of Effect of Hypophysectomy upon Metastatic Adrenocortical Carcinoma with Cushing's Syndrome. J. Clin. Endocrinol., **14**:205–14, 1954.
23. LACASSAGNE, A., and NYKE, W. Procédé de destruction de l'hypophyse du lapin par le radon. Compt. rend. Soc. de biol., **117**:956–58, 1934.
24. LAWRENCE, J. H.; AEBERSOLD, P. C.; and LAWRENCE, E. O. Comparative Effects on X-rays and Neutrons on Normal and Tumor Tissue. Proc. Nat. Acad. Sc., **22**:543–57, 1936.
25. ———. The Comparative Effects of Neutrons and X-rays on Normal and Neoplastic Tissue. Occas. Pub. Am. Assoc. Adv. Sc., **4**:215–19, 1937.
26. LAWRENCE, J. H., and LAWRENCE, E. O. The Biological Action of Neutron Rays. Proc. Nat. Acad. Sc., **22**:124–33, 1936.
27. LAWRENCE, J. H.; NELSON, W. O.; and WILSON, H. Roentgen Irradiation of the Hypophysis. Radiology, **29**:446–54, 1937.
28. LI, M. C.; RALL, J. E.; MACLEAN, J. P.; LIPSETT, M. B.; RAY, B. S.; and PEARSON, O. H. Thyroid Function Following Hypophysectomy in Man. J. Clin. Endocrinol., **15**: 1228–38, 1955.
29. LIPSETT, M. B.; MACLEAN, J. P.; WEST, C. D.; LI, M. C.; and PEARSON, O. H. An Analysis of the Polyuria Induced by Hypophysectomy in Man. J. Clin. Endocrinol., **16**: 183–95, 1956.
30. LUFT, R., and OLIVECRONA, H. Experiences with Hypophysectomy in Man. J. Neurosurg., **10**:301–16, 1953.
31. ———. Hypophysectomy in Man: Experiences in Metastatic Cancer of the Breast. Cancer, **8**:261–70, 1955.
32. LUFT, R.; OLIVECRONA, H.; IKKOS, D.; KORNERUP, T.; and LJUNGGREN, H. Hypophysectomy in Man: Further Experiences in Severe Diabetes Mellitus. Brit. M. J., **2**:752–62, 1955.
33. LUFT, R.; OLIVECRONA, H.; and SJOGRAN, B. Hypophysectomy in Man: Experiences in Severe Diabetes Mellitus. J. Clin. Endocrinol., **15**:391–408, 1955.
34. MALAMUD, N.; BOLDREY, E. B.; WELCH, W. K.; and FADELL, E. J. Necrosis of Brain and Spinal Cord Following X-ray Therapy. J. Neurosurgery, **11**:353–62, 1954.
35. MATEYKO, G. M., and EDELMANN, A. The Effect of Localized Cathode-Ray Particle Irradiation of the Hypophysis and Whole-Body X-Irradiation on Gonadotrophin, Thyrotrophin, and Adrenocorticotrophin of the Rat Pituitary. Radiation Research, **1**:470–87, 1954.
36. MENDELSOHN, M. L., and BODANSKY, O. The Value of Liver-Function Tests in the Diagnosis of Intrahepatic Metastases in the Nonicteric Cancer Patient. Cancer, **5**:1–8, 1952.
37. MORGAN, R. H. Pituitary Tumors. Am. J. M. Sc., **220**: 577–90, 1950.

0018000

38. Murphy, W. T., and Schwippert, H. Pituitary Irradiation in Prostatic Carcinoma. Radiology, **56**:376–83, 1951.
39. Northfield, D. W. C. Radon Implantation for Acromegaly and Cushing's Syndrome. Proc. Roy. Soc. Med., **42**: 845–53, 1949.
40. Pearson, O. H.; Ray, B. S.; Harrold, C. C.; West, C. D.; Li, M. C.; MacLean, J. P.; and Lipsett, M. B. Hypophysectomy in the Treatment of Advanced Cancer. Tr. A. Am. Physicians, **68**:101–11, 1955.
41. Perrault, M. Hypophysectomie et cancer du sein. Presse med., **80**:1639–40, 1953.
42. Perrault, M.; Le Beau, J.; Klotz, B.; Sicard, J.; and Clavel, B. L'hypophysectomie total dans le traitement du cancer du sein. Premier cas français. Avenir de la méthode. Therapie, **7**:290–300, 1952.
43. Rahm, H. Experimentelles zur Roentgenbestrahlung der Hypophyse. Brun's Beitr. klin. Chir., **126**:642–57, 1922 (cites Gramegna in 1909 as applying pituitary irradiation therapeutically).
44. Rothenberg, S. F.; Jaffe, H. L.; Putnam, T. J.; and Simkin, B. Hypophysicteny with Radioactive Chromic Phosphate in Treatment of Cancer. A.M.A. Arch. Neurol. & Psychiat., **73**:193–99, 1955.
45. Santos, C. Gezielte scharf lokalisierte Roentgentherapie. Strahlentherapie, **96**:47–63, 1955.
46. Sheehan, H. L., and Summers, V. K. The Syndrome of Hypopituitarism. Quart. J. Med., **18**:319–78, 1949.
47. Shimkin, M. B.; Boldrey, E. B.; Kelly, K. H.; Bierman, H. R.; Ortega, P.; and Naffziger, H. C. Effects of Surgical Hypophysectomy in Man with Malignant Melanoma. J. Clin. Endocrinol., **12**:439–53, 1952.
48. Stone, R. S., and Larkin, J. C., Jr. The Treatment of Cancer with Fast Neutrons. Radiology, **39**:608–20, 1942.
49. Stone, R. S.; Lawrence, J. H.; and Aebersold, P. C. A Preliminary Report on the Use of Fast Neutrons in the Treatment of Malignant Disease. Radiology, **35**:322–27, 1940.
50. Tobias, C. A.; Anger, H. O.; and Lawrence, J. H. Radiological Use of High-Energy Deuterons and Alpha Particles. Am. J. Roentgenol., **67**:1–27, 1952.
51. Tobias, C. A.; Van Dyke, D. C.; Simpson, M. E.; Anger, H. O.; Huff, R. L.; and Koneff, A. A. Irradiation of the Pituitary of the Rat with High-Energy Deuterons. Am. J. Roentgenol., **72**:1–21, 1954.
52. Van Dyke, D. C.; Contopoulos, A. N.; Williams, B. S.; Simpson, M. E.; Lawrence, J. H.; and Evans, H. M. Hormonal Factors Influencing Erythropoiesis. Acta haemat., **11**:203–22, 1954.
53. Wilson, R. R. Radiological Use of Fast Protons. Radiology, **47**:487–91, 1946.
54. Woodard, H. Q.; Escher, G. C.; and Farrow, J. H. Changes in the Blood Chemistry of Patients with Disseminated Carcinoma of the Breast during Endocrine Therapy. Cancer, **7**:744–57, 1954.
55. Zirkle, R. E., and Tobias, C. A. Effects of Ploidy and Linear Energy Transfer on Radiobiological Survival Curves. Arch. Biochem., **47**:282–306, 1953.

Fig. 1.—An autoradiograph of the proton beam as it crosses a 6-inch-thick, solid block of lucite (full size).

Fig. 2*a*.—A lateral roentgenogram of a patient's sella turcica in correct alignment for proton irradiation.

Fig. 2*b*.—Same as 2*a*, with an autoradiograph of the beam superimposed (full size).

Fig. 3.—An antero-posterior roentgenogram of a patient's sella turcica in the correct alignment for proton irradiation (full size).

Fig. 4.—The irradiation energy density pattern in the region of the sella turcica in a phantom head subjected to a complete rotation schedule.

Fig. 5.—A photomicrograph of a section of pituitary from a patient who received 26,000 rad and survived 7 months ($\times 8\frac{1}{2}$).

Fig. 6.—A photomicrograph of a section of pituitary from a patient who received 26,000 rad and survived 6 months ($\times 8\frac{1}{2}$).

0018001

1

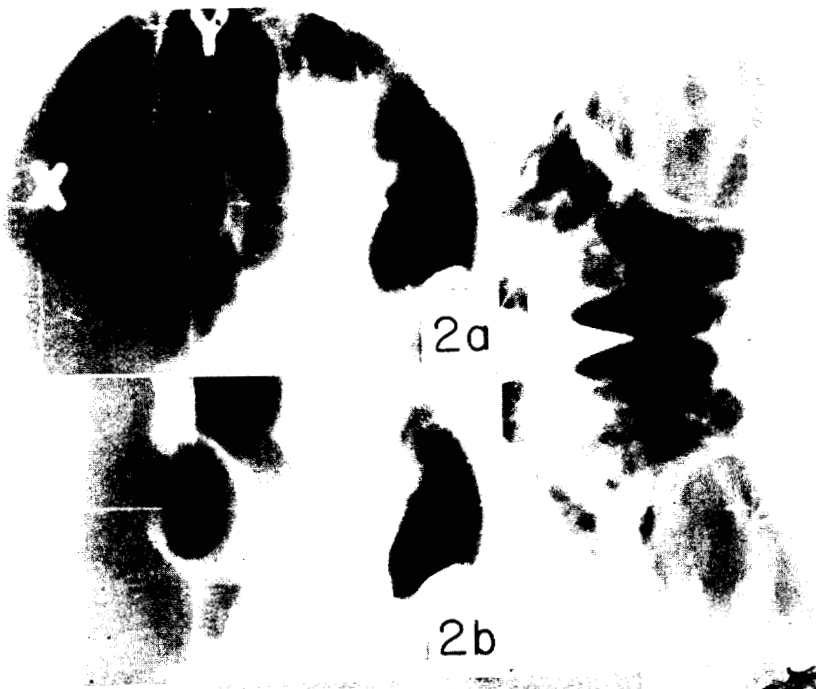

3

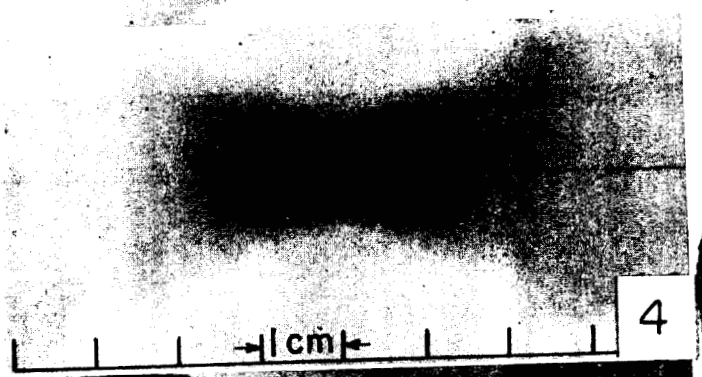

4



5

6

0018002

FIG. 7.—A photograph of the sella turcica from a patient who received 30,000 rad and survived 14 months.[6]

FIG. 8.—A photograph of the pituitary remnant dissected from the sella turcica shown in Figure 7.[6]

0018003

0018004

FIG. 9.—A photomicrograph of a section of the pituitary shown in Figs. 7 and 8 ($\times 8\frac{1}{2}$).

FIG. 10.—A photograph of the brain from the case in Figures 7–9.[6]

FIG. 11.—A photomicrograph of the thyroid from the patient whose pituitary is shown in Figure 5 ($\times 400$).

FIG. 12.—A photomicrograph of the thyroid from the patient whose pituitary is shown in Figure 6 ($\times 400$).

0018005

9

10



11

12

0018006