Am J Clin Oncol (CCT) 12(4): 311–315, 1989.

© 1989 Raven Press Ltd., New York

702242

Neutron Radiotherapy for Malignant Gliomas

Brian R. Griffin, M.D., Mitchell S. Berger, M.D., George E. Laramore, Ph.D., M.D., Thomas W. Griffin, M.D., William P. Shuman, M.D., Robert G. Parker, M.D., Lawrence W. Davis, M.D., and Marie Diener-West, Ph.D.

File Copy 7012
Pub. # 5030
Study # 7611, 8002
Site: Glioma
Modality: ntr
Status: Pub

Neutron radiotherapy has been used for patients with malignant gliomas for over a decade; a substantial number of patients have been treated to date. Pathologic analysis of surgical specimens posttreatment and autopsy specimens have documented an increased antitumor effect of neutrons against malignant gliomas, compared with photon irradiation. However, results of neutron trials to date have not shown a survival advantage over conventional radiotherapy for these patients. This article reviews current surgical, radiotherapeutic, and chemotherapeutic approaches to these tumors, the rationale for neutron treatment, and the results of trials of neutron radiotherapy conducted to date for patients with malignant gliomas.

Key Words: Malignant gliomas—Neutrons.

REPOSITORY Fermi IAB Neutron Therapy Facility (NTF)
COLLECTION Radiation Therapy Oncology Group (RTOG) RTOG Published Material
BOX No. Binder - collected + copied from shelf
FOLDER RTOG Published Materials Copied 4/21/94 AT FERMILAB

Malignant gliomas present a particularly challenging problem in cancer management. Although accounting for only approximately half of all newly diagnosed primary brain tumors, malignant gliomas are responsible for a disproportionately high percentage of deaths that occur from central nervous system neoplasms (1). Local recurrence of malignant gliomas remains an overwhelming problem. Although they tend to remain confined to the central nervous system, these tumors typically infiltrate adjacent vital brain structures, usually preventing their complete surgical removal.

The availability of advanced surgical techniques has changed the way these tumors can be approached surgically. Large, aggressive tumor resections can now be performed safely, leading to a reduced tumor burden prior to further therapy. Although the goal of surgery is to perform a radical resection, this is not always possible or indicated. Recent advances in stereotactic surgery enable any intracranial region of interest to undergo biopsy with safety and millimeter precision (2,3). Lesions greater than 1 cm and located in more superficial areas can also be accurately sampled via a burr hole with the aid of high-resolution ultrasonography (4). This latter technique has the advantage of not requiring bulky stereotactic head frames, computed tomography (CT), or magnetic resonance (MR) scans.

It is often difficult to grossly distinguish tumor from normal adjacent brain tissue. Intraoperative ultrasonography readily identifies echogenic tumor and normal anatomical structures in contrast to hypoechoic brain and edema (5). Contrast enhancing and nonenhancing lesions depicted on CT scans are routinely identified with sonographic techniques. Current investigations indicate a close (within 5–10 mm) correlation between the intraoperative ultrasonographic and CT scan findings in defining the tumor boundaries, thus

From the Department of Radiation Oncology (B.R.G., G.E.L., T.W.G.), the Department of Neurological Surgery (B.R.G., M.S.B.), and the Department of Radiology (W.P.S.), University of Washington, Seattle, Washington; the Department of Radiation Oncology, University of California–Los Angeles, Los Angeles, California (R.G.P.); the Department of Radiation Therapy, Albert Einstein College of Medicine, Montefiore Medical Center, Bronx, New York (L.W.D.); and the Radiation Therapy Oncology Group, Statistical Center, Philadelphia, Pennsylvania (M.D-W.).

Address correspondence and reprint requests to Dr. Brian R. Griffin, Department of Radiation Oncology, University Cancer Center, RC-08, 1959 N.E. Pacific St., Seattle, WA 98195, U.S.A.

0016329

enabling greater tumor resection without sacrificing normal brain structures (44). The use of CT–stereotactic localization techniques coupled with the surgical laser has resulted in a novel computer-assisted system that enables the neurosurgeon to precisely remove deep lesions (6). This method allows the resection to correspond to any abnormal area visualized on the CT or MR scans (7). More superficial lesions located in critical functional areas can now be operated on in the same manner using CT–stereotactic localization and intraoperative physiological mapping of the brain to avoid language, sensory, and motor areas (45). Thus, the extent of surgical resection can be maximized to a greater degree than previously possible in eloquent brain regions without sacrificing patient safety.

Recently completed retrospective studies suggest that patient performance status and survival time with malignant gliomas is improved with gross total tumor resection, compared with subtotal resection (8,9). Additionally, contrast-enhanced CT scans are useful in predicting a favorable prognosis following surgery and radiotherapy as determined by the amount of residual tumor present (10). Thus, the neurosurgeon should strive to achieve as much tumor removal as is safely possible for malignant gliomas.

The beneficial effect of conventional postoperative radiotherapy for patients with malignant gliomas has been established; the median length of survival is doubled to approximately 36 weeks with radiotherapy, versus 14 weeks for supportive care alone (11). Nevertheless, malignant gliomas are radioresistant neoplasms; they persist or recur locally even after 7,000–8,000 cGy given at conventional fractionation (12), a dose that exceeds the normal tissue tolerance of the brain (13). A possible mechanism for this radioresistance is tumor cell hypoxia. Numerous studies in many biological systems have shown that hypoxic cells are significantly more resistant to the effects of photon radiation than are well-oxygenated cells, and it has been postulated that these hypoxic cells are responsible for tumor recurrence (14).

However, clinical trials of the highly electron-affinitive hypoxic cell sensitizer misonidazole in malignant gliomas have been disappointing. Studies by the European Organization of Radiation Therapy Centers (15), the United Kingdom Medical Research Council (16), and the Radiation Therapy Oncology Group (RTOG) (17) demonstrated no benefit for the addition of misonidazole to radiation therapy compared with radiation therapy alone for these neoplasms. A different type of radiosensitizer currently under investigation is the group of halogenated pyrimidines. These agents are incorporated into the DNA of proliferating cells. Because there is little mitotic activity in the normal brain, these agents should theoretically selectively sensitize tumor cells in malignant gliomas. The Northern California Oncology Group is currently testing bromodeoxyuridine in malignant gliomas, although results are not yet available.

Clinical studies assessing the role of chemotherapy as a substitute for radiation in treating newly diagnosed malignant gliomas have been disappointing. A variety of studies using single agent or multiagent chemotherapy as the only therapeutic modality in this situation have yielded results inferior to those achieved with radiation alone (18–22). Subsequent investigations were designed to evaluate the effectiveness of chemotherapy when used as an adjuvant agent or at the time of tumor recurrence. To date, the most useful drugs have been the chloroethyl-nitrosoureas, of which BCNU (carmustine) is the most widely used compound. Early clinical studies carried out in a controlled fashion demonstrated a modestly prolonged median survival time with BCNU (18,23,24) when added to radiotherapy. More recently, dose schedules as well as routes of administration have been varied, to improve the tumor concentration of the drug. One such example is through the use of intracarotid BCNU (25,26), which allows for a greater regional tissue concentration with potentially less systemic toxicity. However, its risk-to-benefit ratio is still in question (27,28). Several other nitrosoureas have been used separately or in combination with other agents, i.e., CCNU (lomustine) (24,29), MeCCNU (semustine) (30), PCNU (31), and streptozotocin (32), although these drugs have failed to show an advantage over BCNU.

Current investigations using chemotherapy for malignant gliomas involve alternative dosing regimens such as a high drug dose administration with bone marrow rescue and strategies designed to overcome drug resistance using multiple non–cross-resistant agents in combination. Future randomized prospective trials will be required before these agents can be advocated as standard adjuvants to radiation therapy for patients with malignant gliomas.

Fast neutron radiation theoretically could be more effective against hypoxic tumor cells than conventional radiotherapy. The oxygen enhancement ratio (OER) is the ratio of the dose of radiation required to produce a specified biological effect under anoxic conditions to the dose required to produce the same effect under well-oxygenated conditions. The OER for conventional photon radiation is approximately 2.5–3.0 for most mammalian cells, while the OER for neutron radiation is significantly smaller (1.4–1.7). Because of the high linear energy transfer (LET) characteristics of neutron

0016330

radiation, a greater proportion of biological damage is via "direct" mechanisms than with low LET radiation; consequently, there is less need for cells to be well oxygenated to have both a long free radical lifetime and to stabilize free-radical damage (33). This effect is potentially important in glioblastoma multiforme, which by definition contains necrotic areas (34) presumably surrounded by zones of hypoxic cells. However, reoxygenation of tumor cells during the course of conventional radiotherapy may also occur, potentially diminishing the theoretical advantage of neutrons over low LET radiotherapy.

Another characteristic of neutron radiation of possible significance in malignant gliomas is reduced cellular repair of radiation injury. There is much less repair of both sublethal (35) and potentially lethal (36) damage after neutron irradiation than with low LET irradiation. The inability to control malignant gliomas with photon treatment may be due to their inherently large capacity for repair of radiation injury, which potentially could be overwhelmed by neutron irradiation.

There is evidence to suggest that fast neutrons exert a considerable antitumor effect against malignant gliomas. Laramore et al. (37) described 36 patients treated with whole-brain irradiation with neutrons alone or a combination of x-rays and neutrons ("mixed beam"). No difference in survival time was seen for patients with grade IV tumors compared with historical control subjects treated with x-rays, but the survival time was worse for patients with grade III lesions treated with neutrons (Kernohan and Sayre schema) (38). Autopsies were performed on 15 patients; the tumor appeared to be eradicated in 14 of the 15 cases. The patient's brains showed a coagulative necrosis replacing the gross tumor volume that contained only occasional abnormal cells; these appeared to be reactive astrocytes rather than residual tumor. Areas of gliosis and white matter degeneration were found in the brain remote from the tumor site (39) and probably were related to the ultimate cause of death. Catterall et al. (40) described 16 patients treated with fast neutrons to the entire brain who had a postirradiation craniotomy or who came to autopsy. Similar to the results of Laramore et al. (37), there was no improvement in length of survival compared with historical controls; additionally, in 69% of the cases, no tumor or only microscopic tumor could be demonstrated. These pathologic results differ markedly from the picture that is seen after photon irradiation, either given alone or in combination with radiosensitizers or chemotherapy, where persistent, actively growing glioma is the rule. Despite this demonstrated ability to sterilize malignant glioma, these studies clearly showed that neutron irradiation had unacceptable toxicity when delivered to the entire brain.

A subsequent randomized study conducted by the RTOG limited neutron treatment to a boost volume around the preoperative tumor mass as defined by CT scan (41). All patients initially received 5,000 cGy to the whole brain, and then randomly chosen patients received a 1,500-cGy photon boost or an equivalent boost dose with neutrons. The classification system of Nelson et al. (34) was used to determine tumor histology, and 158 evaluable cases were entered in the study. The median survival time for patients with glioblastomas was very similar for the neutron-boost group (9.6 months) and the photon-boost group (8.5 months). However, for patients with anaplastic astrocytoma, the median survival time was 15.8 months for the neutron-boost group, versus 26.3 months for the photon-boost group. This difference was not statistically significant due to the small number of patients with anaplastic astrocytoma. Autopsies were performed on 12 patients in each treatment arm. In nine of 12 neutron-boost patients, no viable tumor could be identified, although scattered bizarre cells were seen within the necrotic tumor volume, as in previous studies. In the photon-boost group, however, all 12 patients undergoing autopsy had an infiltrative, proliferating, viable tumor present in their specimens. Progressive tumor was the cause of death in the photon-boost patients, as opposed to the neutron-boost patients, for whom treatment-related side effects appeared to be the major cause of death.

To define a treatment regimen that would harness the antitumor effect of neutrons yet maintain acceptable toxicity, the RTOG performed a follow-up study in which patients with malignant glioma were randomly chosen to receive a range of neutron-boost doses given concomitantly with photon irradiation (42). One hundred ninety evaluable cases of glioblastoma multiforme (34) or anaplastic astrocytoma were treated with 4,500 cGy/150 cGy/fx/five fractions per week whole-brain photon irradiation along with a twice-weekly neutron boost to the tumor volume as defined by CT scan. The patients were randomly chosen to receive six different neutron-boost doses ranging from 360 to 600 cGy. No significant differences in overall survival time were observed among the various neutron dose levels. The median survival time for patients with glioblastoma multiforme was 9.9 months, compared with 22 months for patients with anaplastic astrocytoma. For patients having a less aggressive tumor histologic description (anaplastic astrocytoma), there was a suggestion that patients receiving higher doses had poorer overall survival times than patients [illegible]

0016331

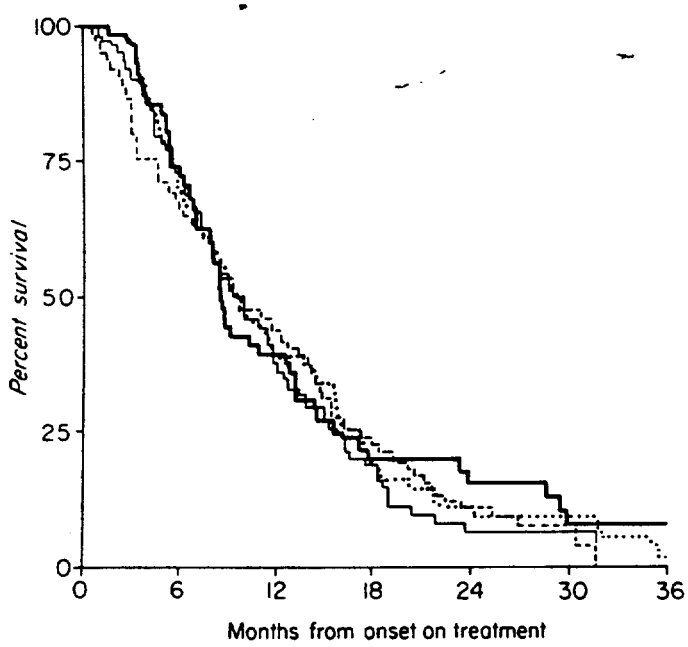

FIG. 1. Survival as a function of treatment for the subgroup of patients having the diagnosis of glioblastoma multiforme. The experimental arms of various Radiation Therapy Oncology Group studies are compared with standard photon irradiation [RTOG 76–11: photons plus photon boost (bold line)]. 79–18 photons plus BCNU is represented by the broken line, 76–11 photons plus neutron boost by the dotted line, and 80–27 photons plus neutron boost by the fine line.

the lower dose levels and also the historical photon control subjects. Autopsies were performed on 35 patients. At all dose levels there were patients with both evidence of active, proliferating tumor and radiation damage to normal brain tissue. It appears that in using this "field-within-a-field" boost technique, no therapeutic gain is seen for patients with malignant glioma.

Despite having an apparent ability to eradicate malignant glioma, fast neutron radiotherapy has not led to an improved length of survival for patients with glioblastoma multiforme, compared with conventional photon treatment for these patients. Figure 1 shows survival data for patients with the diagnosis of glioblastoma multiforme treated with high-dose photons alone, with high-dose photons plus BCNU chemotherapy, and with neutron-boost radiation given either after or concomitantly with the whole-brain photon irradiation. There is no significant difference in results among the various treatments (42). For anaplastic astrocytoma, the situation appears even more discouraging because studies to date suggest a worse outcome for neutron-treated patients, compared with results with conventional radiotherapy for this group. Certainly, there is no indication of a therapeutic window in which tumor can be sterilized with neutron radiotherapy without causing unacceptable damage to a normal brain; this may be due in large part to the diffuse, infiltrating nature of malignant gliomas, which require extensive radiation fields to encompass the entire tumor volume.

Regarding future research with neutrons for malignant gliomas, the trials to date suggest that patients with anaplastic astrocytoma should be excluded from pilot studies involving neutrons. For patients with newly diagnosed glioblastoma multiforme or recurrent malignant gliomas, it is possible that studies using agents designed to selectively protect the normal brain against neutrons or agents aimed at selectively increasing the local neutron dose to the tumor cells (e.g., tagged antibodies) (43) will be feasible in the future.

Acknowledgment: This work was supported in part by the National Cancer Institute under grants CA-12441, CA-22133, and contract CA-97282.

REFERENCES

1. Walker MD. Brain tumors. In: Holland JF, Frei E, (eds.) *Cancer medicine*. Philadelphia: Lea and Febiger, 1973:1385–407.
2. Heilbrun MP, Roberts TS, Apuzzo MLJ, et al. Preliminary experience with Brown-Roberts-Wells (BRW) computerized tomography stereotaxic guidance system. *J Neurosurg Sci* 1983;59:217–22.
3. Kelly PJ, Earnest F, Kall BA, et al. Surgical options for patients with deep-seated brain tumors: computer-assisted stereotactic biopsy. *Mayo Clin Proc* 1985;60:223–9.
4. Berger MS. Ultrasound guided stereotaxic biopsies through a burr hole using a newly designed apparatus. *J Neurosurg Sci* 1986;65:550–4.
5. Chandler WF, Knabe JE, McGillicuddy J. Intraoperative use of real time ultrasonography in neurosurgery. *J Neurosurg Sci* 1972;57:157–63.
6. Kelly PJ, Kall BA, Goerss S, et al. Computer-assisted stereotaxic laser resection of intra-axial brain neoplasms. *J Neurosurg* 1986;64:427–39.

0016332

7. Kelly PJ, Kall BA, Goerss S, et al. Results of computer-assisted stereotactic laser resection of deep-seated intracranial lesions. *Mayo Clin Proc* 1986;61:20–7.
8. Ammirati M, Vick N, Liao Y, et al. Effect of the extent of surgical resection on survival and quality of life in patients with supratentorial glioblastomas and anaplastic astrocytomas. *Neurosurgery* 1987;21:201–6.
9. Ciric I, Ammirati M, Vick M, et al. Supratentorial gliomas: surgical considerations and immediate postoperative results. *Neurosurgery* 1987;21:21–6.
10. Murovic J, Turowski K, Wilson CB, et al. Computerized tomography in the prognosis of malignant cerebral gliomas. *J Neurosurg* 1986;65:799–806.
11. Walker MD, Alexander E, Hunt W, et al. Evaluation of BCNU and/or radiotherapy in the treatment of anaplastic gliomas. *J Neurosurg* 1978;49:333–43.
12. Salazar OM, Rubin P, Feldstein ML, Pizzutiello R. High dose radiation therapy in the treatment of malignant gliomas: final report. *Int J Radiat Oncol Biol Phys* 1979;5:1733–40.
13. Sheline GE, Wara WM, Smith V. Therapeutic irradiation and brain injury. *Int J Radiat Oncol Biol Phys* 1980;6:1215–28.
14. Gray LH, Conger AE, Ebert M, et al. Concentration of oxygen dissolved in tissues at time of irradiation as factor in radiotherapy. *Br J Radiol* 1953;26:638.
15. EORTC Brain Tumor Group. Misomidazole in radiotherapy of supratentorial malignant gliomas in adult patients: a randomized double blind study. *Eur J Cancer* 1983;19:39–42.
16. Medical research council. Medical research council working party on misonidazole in gliomas in conjunction with radiotherapy in the treatment of grades III and IV astrocytoma. *Br J Radiol* 1983;56:673–82.
17. Carabell SC, Bruno LA, Weinstein AS, et al. Misonidazole and radiotherapy to treat malignant glioma: a phase II trial of the Radiation Therapy Oncology Group. *Int J Radiat Oncol Biol Phys* 1981;7:71–7.
18. Walker MD, Alexander E, Hunt WE, et al. Evaluation on BCNU and/or radiotherapy in the treatment of anaplastic gliomas. *J Neurosurg* 1978;49:333–43.
19. Mealay J, Chen TT, Pedlow E. Brain tumor chemotherapy with mithramycin and vincristine. *Cancer* 1970;26:310–67.
20. Reagan TJ, Bisel HT, Childs DS, et al. Controlled study of CCNU and radiation therapy in malignant astrocytoma. *J Neurosurg Sci* 1976;44:186–90.
21. Shapiro WR, Young DF. Treatment of malignant glioma. A controlled study of chemotherapy and irradiation. *Arch Neurol* 1976;33:494–500.
22. Jellinger K, Vole D, Grisold W, et al. Multimodality treatment of malignant gliomas. Comparison of several adjuvant approaches. *Zentralbl Neurochir* 1981;42:99–122.
23. Walker MD, Green SB, Byar DP, et al. Randomized comparisons of radiotherapy and nitrosoureas for malignant gliomas after surgery. *N Engl J Med* 1980;303:1323–9.
24. Salero CL, Monfardini S, Brambilla C, et al. Controlled study with BCNU vs. CCNU as adjuvant chemotherapy following surgery plus radiotherapy for glioblastoma multiforme. *Cancer Clin Trials* 1979;2:43–8.
25. Greenberg HS, Ensminger WD, Jaeger JF, et al. Intraarterial BCNU chemotherapy for the treatment of malignant gliomas of the central nervous system: a preliminary report. *Cancer Treat Rep* 1981;65:803–10.
26. West CR, Avellanosa AM, Barva NR. Intraarterial 1,3-bis(2-chloroethyl)-1-nitrosourea (BCNU) and systemic chemotherapy for malignant gliomas: a follow-up study. *Neurosurgery* 1983;13:420–6.
27. Kapp J, Vance R, Parker JL. Limitations of high dose intra-arterial 1,3-bis(2 chloroethyl)-1-nitrosoureas (BCNU) chemotherapy for malignant gliomas. *Neurosurgery* 1982;10:715–9.
28. Greenberg HS, Ensminger WD, Layton PB, et al. Phase I–II evaluation of intra-arterial diaziquone for recurrent malignant astrocytomas. *Cancer Treat Rep* 1986;70:353–7.
29. Garrett MJ, Hughes HT, Freedman LS. A comparison of radiotherapy alone with radiotherapy and CCNU in cerebral glioma. *Clin Oncol* 1978;4:71–6.
30. Ushio Y, Hayakawa T, Hasegawa H, et al. Chemotherapy of malignant gliomas. *Neurosurg Rev* 1982;7:3–12.
31. Feun LG, Stewart DT, Leavens ME, et al. A phase II trial of 1-(2-chloroethyl)-3-(2,6-dioxo-3-piperidyl)-1-nitrosourea (PCNU, NSC 95466) in recurrent malignant brain tumors. *J Neurooncol* 1983;1:45–8.
32. Green SB, Byar DP, Strike TA, et al. Randomized comparisons of BCNU, streptozotocin, radiosensitivity, and fractionation of radiotherapy in the postoperative treatment of malignant glioma [Abstract]. *Proc Annu Meet Am Soc Clin Oncol* 1984;3:269-C-1018.
33. Withers HR. Biological basis for high LET radiotherapy. *Radiology* 1973;108:131–7.
34. Nelson JS, Schoenfeld D, Tsukeda Y, Fulling K, Lamarche J, Peress N. Necrosis as a prognostic criterion in malignant, supratentorial astrocytic gliomas. *Cancer* 1983;52:550–4.
35. Hall EJ. *Radiobiology for the radiologist.* 2nd ed. Hagerstown, Maryland: Harper and Row, 1978: 139–41.
36. Hall EJ, Kroljevic U. Repair of potentially lethal radiation damage: comparison of neutron and X-ray RBE and implications for radiation therapy. *Radiology* 1976;121:731–5.
37. Laramore GE, Griffin TW, Gerdes AJ, Parker RC. Fast neutron and mixed (neutron/photon) beam teletherapy for grades III and IV astrocytomas. *Cancer* 1978;42:96–103.
38. Kernohan JW, Sayre GP. Tumors of the central nervous system. In: *Atlas of tumor pathology.* Section 10, fascicles 35 and 37. Washington, D.C.: Armed Forces Institute of Pathology, 1952: 17–42.
39. Shaw CM, Sumi SM, Alvord EC, Gerdes AJ, Spence A, Parker RG. Fast neutron irradiation of glioblastoma multiforme: neuropathological analysis. *J Neurosurg* 1978;49:1–12.
40. Catterall M, Bloom HJG, Ash DV, et al. Fast neutrons compared with megavoltage X-rays in the treatment of patients with supratentorial glioblastoma: a controlled pilot study. *Int J Radiat Oncol Biol Phys* 1980;6:261–6.
41. Griffin TW, Davis R, Laramore GE, et al. Fast neutron radiation therapy for glioblastoma multiforme: results of an RTOG study. *Am J Clin Oncol* 1983;6:661–7.
42. Laramore GE, Diener-West M, Griffin TW, et al. Randomized neutron dose searching study for malignant gliomas of the brain: results of an RTOG study. *Int J Radiat Oncol Biol Phys* (In press).
43. Nowak TP. Monoclonal antibodies: prospects for specific immunotherapy for gliomas. *Am J Clin Oncol* 1987;10:278–80.
44. LeRoux P, Berger MS, Mack L. Correlation of intraoperative tumor volume to contrast enhanced CT scans. *J Neurosurg* (In press).
45. Berger MS, Ojemann GA. Intraoperative physiological brain mapping to maximize the extent of tumor resection and enhance safety in malignant glioma surgery. *Neurosurgery* (In press).

0016333