

File Copy	
Pub. #	1112 5007
Study #	7610
Site:	hn
Modality:	part
Status:	pub

702216

● Original Contribution

REPOSITORY FERMILAB NTF
RADIATION THERAPY ONCOLOGY GROUP
COLLECTION RTOG PUBLISHED MANUSCRIPTS REG

BOX NO. BINDER - Collected & Copied From Shelf
RTOG PUBLISH MANUSCRIPTS
FOLDER Copied 4-21-94 At Fermilab NTF

MIXED BEAM RADIATION THERAPY FOR UNRESECTABLE SQUAMOUS CELL CARCINOMAS OF THE HEAD AND NECK: THE RESULTS OF A RANDOMIZED RTOG STUDY

THOMAS W. GRIFFIN, M.D.,¹ ROGER DAVIS, M.A.,² GEORGE E. LARAMORE, PH.D., M.D.,³
MOSHE H. MAOR, M.D.,⁴ FRANK R. HENDRICKSON, M.D.,⁵
ANTONIO RODRIGUEZ-ANTUNEZ, M.D.⁶ AND LARRY DAVIS, M.D.⁷

Three hundred and twenty-two patients with inoperable squamous cell carcinomas of the head and neck were entered on a randomized study comparing "mixed beam" radiation therapy with photon radiation therapy. Patients with histologically proven tumors of T-stage T₂, T₃, or T₄ and any N-stage originating in the oral cavity, oropharynx, supraglottic larynx, or hypopharynx were eligible. One hundred forty-five patients were randomized to photon treatment and 177 were randomized to mixed beam treatment. No significant differences could be demonstrated between the experimental and control groups for primary tumor control or overall survival, although there was an advantage for mixed beam treatment over photon treatment for patients with metastatic cervical adenopathy (69 vs. 55% complete response rate in the nodes, $p = .024$). It is concluded that mixed beam radiation therapy does not offer a significant advantage over photon radiation therapy for patients with advanced squamous cell carcinomas of the head and neck.

Mixed beam, High-LET, Neutrons.

INTRODUCTION

Although uncommon when compared to other human malignancies, squamous cell carcinomas of the head and neck are responsible for 13,000 deaths in the United States each year.¹ Despite major advances in the fields of radiation therapy, surgery, and chemotherapy, uncontrolled local-regional disease is still the most common cause of death from these tumors.³ The survival rates with conventional treatment for patients with advanced, unresectable tumors remains poor, and in an attempt to improve upon these results, and on those in other tumor systems, the National Cancer Institute instituted a study testing the feasibility of fast neutron radiation therapy in 1971.

Fast neutron radiation therapy studies were started because of two significant theoretical advantages of high LET radiation over conventional photons: 1) a lower oxygen enhancement ratio (OER), and 2) a predominantly direct effect form of cell damage which is less

susceptible to variations in cell cycle and repair by tumor cells. These theoretical advantages led to clinical studies in the United States, Europe and Japan.

The first two years of the research effort in the United States were spent adapting laboratory based cyclotrons for medical use and characterizing the radiobiological properties of the various neutron beams. Phase I-II clinical trials were initiated in 1973, and were continued until 1977. The results of these studies have been previously reported.^{9,11}

In 1977 a phase III study testing fast neutron radiation therapy in head and neck cancer was opened to patient accrual. This study, coordinated by the RTOG, tested both fast neutrons alone and "mixed beam" irradiation (a mixture of neutrons and photons) against conventional photon radiation therapy in patients with unresectable squamous cell carcinomas of the head and neck. Three hundred and twenty-two patients were accrued over 63 months to the mixed beam randomization. Because the patient populations in the mixed beam and neutron

¹ Chairman, Department of Radiation Oncology, University of Washington, Seattle, WA.

² Dana Farber Cancer Institute, Boston, MA.

³ Associate Professor, Department of Radiation Oncology, University of Washington, Seattle, WA.

⁴ Associate Professor, Department of Radiotherapy, M.D. Anderson Hospital and Tumor Center, Houston, TX.

⁵ Chairman, Department of Therapeutic Radiology, Rush-Presbyterian St. Luke's Medical Center, Chicago, IL.

⁶ Director of Radiation Therapy, Cleveland Clinic Foundation, Cleveland, OH.

⁷ Chairman, Department of Radiation Oncology, Albert Einstein College of Medicine, New York, NY.

Reprint requests to: Thomas W. Griffin, M.D., Department of Radiation Oncology, University Hospital, RC-08, 1959 N.E. Pacific St., Seattle, WA 98195.

Accepted for publication 17 May 1984.

019100

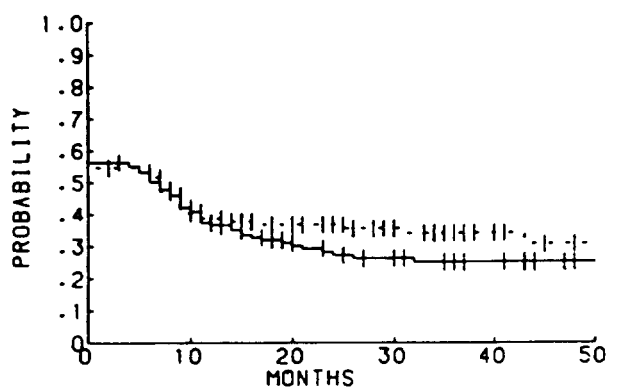
Table 3. Patient characteristics

	Mixed beam		Photons		Total			Mixed beam		Photons		Total	
	#	%	#	%	#	%		#	%	#	%	#	%
Sex							Patient appearance (Contd)						
Male	117	70	96	69	213	70	Normal	106	63	96	69	202	66
Female	50	30	43	31	93	30	Emaciated	34	20	23	17	57	19
Age							Region of primary						
<50	19	11	17	12	36	12	Oral cavity	43	26	38	27	81	26
50-59	47	28	48	35	95	31	Oropharynx	88	53	68	49	156	51
60-69	61	37	54	39	115	38	Hypopharynx	17	10	19	14	36	12
≥70	35	21	18	13	53	17	Larynx	19	11	14	10	33	11
Unknown	2	1	0	0	2	1	T-Stage						
Institution							T2	34	20	28	20	62	20
U of W	43	26	36	26	79	26	T3	83	50	66	47	149	49
GLANTA	7	4	9	6	16	5	T4	50	30	45	32	95	31
MANTA	15	9	9	6	24	8	N-Stage						
TAMVEC	44	26	35	25	79	26	N0	55	33	48	35	103	34
Fermilab	58	35	50	36	108	35	N1	30	18	16	12	46	15
Year of randomization							N2a	13	8	18	13	31	10
1977	14	8	13	9	27	9	N2b	17	10	12	9	29	9
1978	46	28	33	24	79	26	N3a	12	7	10	7	22	7
1979	47	28	38	27	85	28	N3b	40	24	33	24	73	24
1980	33	20	35	25	68	22	N3c	0	0	2	1	2	1
1981	22	13	17	12	39	13	Largest diameter of primary						
1982	5	3	3	2	8	3	4 cm or smaller	63	38	48	35	111	36
Time since first symptoms							5 cm or larger	98	59	81	58	179	58
<6 months	137	82	109	78	246	80	Unknown	6	4	10	7	16	5
6 months-1 year	17	10	19	14	36	12	Differentiation						
>1 year	12	7	10	7	22	7	Low grade	31	19	26	19	57	19
Unknown	1	1	1	1	2	1	Intermediate grade	74	44	65	47	139	45
Karnofsky performance							High grade	21	13	26	19	47	15
60 or below	14	8	9	6	23	8	Unknown	41	25	22	16	63	21
70	16	10	22	16	38	12	Infiltration						
80	50	30	30	22	80	26	Exophytic						
90	82	49	63	45	145	47	Superficial	17	10	23	17	40	13
100	5	3	15	11	20	7	Moderately infiltrating	13	8	4	3	17	6
Patient appearance							Deeply infiltrating	69	41	57	41	126	41
Obese	27	16	20	14	47	15	Unknown	60	36	51	37	111	36
								8	5	4	3	12	4

Tables 4 and 5 show clearance rates at the primary site and in the lymph nodes by treatment. The differences observed at the primary site are not significantly different. The differences in the lymph nodes are ($p = .024$). These effects on cervical adenopathy from squamous cell carcinomas of the head and neck have been reported in detail elsewhere.⁵

Figures 3 and 4 show survival and disease-free survival curves by treatment. There are no significant differences between the two groups for either endpoint. Table 6 lists the 2-year survival rates by primary site, T-stage, N-stage, and Karnofsky performance status. Again there are no significant differences between treatments.

The following severe normal tissue complications were reported on the follow-up forms: soft tissue necrosis, bone necrosis, soft tissue fibrosis, fistula formation, local pain, edema, xerostomia, and radiation caries. The rates of severe or worse complications were 16% for the mixed



TREATMENT	ALIVE	DEAD	TOTAL	MEDIAN
— MIXED BEAM	50	117	167	7.0
- - - PHOTON	50	89	139	7.0

Fig. 1. Time to local/regional failure by treatment.

HL 19100
4 6 17

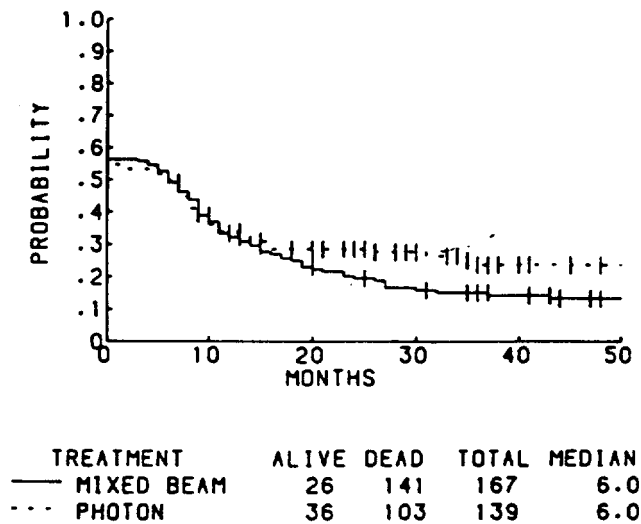


Fig. 4. Disease-free survival by treatment.

of the neutron beams; an increased percentage of neutrons vs. photons in the neck due to increased gamma contamination at depth; underdosage of a portion of the primary tumor due to an exaggerated "hour glass effect" for neutron isodose curves; geographic mass of the primary site due to restrictions in patient set-up imposed by fixed, horizontal treatment beams; differences in biological behavior between primary head and neck tumors and metastatic cervical adenopathy; and a statistical fluke. In any case, it is interesting to note that these results were predicted by Guichard *et al.*, who found an increased population of hypoxic cells in metastatic adenopathy when compared to equivalently sized primary tumors.⁶

These results are also consistent with results reported from independent pilot studies carried out at the Uni-

Table 6. Two-year disease free survival by prognostic characteristics

	Photons %	Mixed beam %
T-Stage		
T ₂	50	36
T ₃	27	19
T ₄	18	10
N-Stage		
N ₀	56	25
N ₁	31	29
N ₂	20	20
N ₃	7	8
Karnofsky status		
100	67	0
90	26	25
80	30	21
70	14	12
60 or below	11	0
Region of primary		
Oral cavity	26	6
Oropharynx	31	27
Hypopharynx	5	6
Supraglottic larynx	57	26

versity of Washington and M.D. Anderson Tumor Institute showing an advantage for mixed beam irradiation in metastatic cervical adenopathy.^{4,7}

Mixed beam radiation therapy was originally conceived as a temporizing measure. It was designed to overcome the limitations of using physics laboratory based equipment previously described in this section. Unfortunately, as used in this study, it must be concluded that mixed beam radiation therapy does not offer a significant overall advantage over photon radiation therapy for patients with advanced squamous cell carcinomas of the head and neck.

REFERENCES

1. Cancer Statistics: *Ca Cancer J. Clin.* 33: 17, 1983.
2. Catterall, M., Bewley, D.K., Sutherland, I.: Second report on a randomized clinical trial of fast neutrons compared with X or gamma rays in treatment of advanced cancers of the head and neck. *Br. Med. J.* 1: 1942-1953, 1977.
3. Fletcher, G.H., Jesse, R.H.: The place of irradiation in the management of the primary lesion in head and neck cancer. *Cancer* 39: 862-867, 1977.
4. Griffin, T.W., Laramore, G.E., Parker, R.G., Gerdes, A.J., Hebard, D.W., Blasko, J.C., Groudine, M.T.: An evaluation of fast neutron beam teletherapy of metastatic cervical adenopathy from squamous cell carcinomas of the head and neck region. *Cancer* 42: 2517-2520, 1978.
5. Griffin, T.W., Davis, R., Laramore, G.E., Hussey, D.H., Hendrickson, F.R., Rodriguez-Antunez, A.: Fast neutron irradiation of metastatic cervical adenopathy: The results of a randomized RTOG study. *Int. J. Radiat. Oncol. Biol. Phys.* 9: 1267-1270, 1983.
6. Guichard, M., Courdi, A., Fertil, B., Malaize, E.P.: Radio-sensitivity of lymph node metastases versus initial subcutaneous tumors in nude mice. *Radiat. Res.* 78: 278-285, 1979.
7. Hussey, D.H.: Fast neutron teletherapy for metastatic cervical adenopathy from carcinomas of the head and neck region. Presented at the International Cancer Congress, Seattle, 1982.
8. Kaplan, E.L., Meier, P.: Nonparametric estimation from incomplete observations. *JASA* 53: 457-481, 1958.
9. Laramore, G.E., Griffin, T.W., Tesh, D.W., Wong, H.H., Parker, R.G.: Phase I pilot study on fast neutron teletherapy for advanced carcinomas of the head and neck region: Final report on local control and survival. *Cancer* 51: 192-199, 1983.
10. Mantel, N., Haenszel, W.: Statistical aspects of the analysis of data from retrospective studies of disease. *J. Nat. Cancer Inst.* 22: 719-748, 1959.
11. Maor, M.H., Hussey, D.H., Barkley, H.T., Peters, L.J.: Neutron therapy for head and neck cancer: 1. A final report of the MDAH-TAMVEC pilot studies. *Int. J. Radiat. Oncol. Biol. Phys.* 9: 1255-1260, 1983.
12. Rasey, J.S., Carpenter, R.E., Nelson, N.J., Parker, R.G.: Cure of EMT-6 tumors by X-rays or neutrons: effect of mixed fractionation schemes. *Radiology* 123: 207-212, 1977.
13. Stone, R.S.: Clinical experience with fast neutron therapy. *Am. J. Roentgenol.* 59: 771-785, 1948.