UNIVERSITY OF CALIFORNIA HOSPIT

TREATMENT RECORD

700498

NAME ... LOCATION D PAGE 1

DATE	DOCTOR'S ORDERS	NURSES' NOTES
[illegible]	1. Bed rest	
	2. Regular diet	
	3. Fluids ad lib.	
	4. Elixir phenobarb. 6/cc h.s. prn for sleep.	
	5. Codeine 0/(30) x2 ℥ 4° prn for Aspirin 0/6 ʒ leg pain. Davies.	J. Montgomery 10 30 pm
	Hold breakfast for blood chemistry. Davies.	J. Montgomery 10 30 pm
4/19	1. Hold breakfast for blood chem. on Monday morning 4/22	
	2. Have Calc.-free [illegible] leurs + tubes at bed-side by 6:30 a.m. Davies.	J. Montgomery 8 pm
4/24	1 ice packs + alcohol sponges to axillae + groin for any temp. over 40°-C.	
	2. Check temp. ℥ 2°. + notify interne if continues to rise. Davies	
	Shave skin of rgt. leg from groin to mid lower leg. Soak rgt. foot for 30' in soapy warm water and trim back [illegible] - also use orange stick. Gently clean rgt. leg c̄ soap + water - use tape remover + remove all scales, etc. Davies.	
	Urine to C.M.L. lab. Davies	D. [illegible] 2 [illegible]

0002504

REPOSITORY DOE - Chicago Ops - Center FOR Human RADIOBIOLOGY

COLLECTION CHR/Plutonium Dors

BOX No. 1 OF 2

FOLDER 40002 Medical Files Redacted

Date	Doctor's Orders	Nurses' Notes
4/24	1. Aspirin 0/3 ℥ 4° while awake. 2. Soda 5% G/W i.v. stat. Davies. T. Montgomery 5pm	
4/25	1. Encourage fluids + fortified fruit juices. 2. U.C. Vit. Compound 4/cc t.i.d. 3. Gently wash leg c̄ warm soap & water & remove scales c̄ tape removes - t.i.d. Davies.	8 3/4
4/26	To 437 by 8:00 a.m. Davies. T. Montgomery 5pm	
4/27	D.C. aspirin. Davies. T. Montgomery 4pm	
4/26	Penicillin - 20,000 u. 1 m. ℥ 3°. Davies. urine to Cold lab. Davies. D Cannon 3 30/	
4/29	D.C. any pre-operative orders - no surgery in a.m. Davies V.S.R.	
5/2/46	Pre-operative Orders. 1. Nothing by mouth after midnight 2. Tap-water enema L.S. 3. Scopolamine 0/000 3 ℔ at 6:45 a.m. 4. Prep by interne. 5. To surg. by 7:00 a.m. sharp. Davies T. Montgomery 5pm	
5/3/46	Pre-operative Orders 1. On side until awake 2. Check B.P., P & R. ℥ 1/2° until stable 2° 3. Eggs ice chips & sips water [illegible]	

C002505

Form 3-172-[illegible]

UNIVERSITY OF CALIFORNIA HOSPI

[illegible] RECORD

[illegible] WARD

NAME [illegible] LOCATION [illegible] PAGE

DATE	DOCTOR'S ORDERS	NURSES' NOTES
	4. Regular diet as tolerated	
	5. Penicillin 20,000 u. q 3° i.m.	
	6. Codeine 0/03 a [illegible] q 3° prn for pain.	
	7. U.C. V.V. compound 4/cc & i.d	
	8. Keep cast elevated on pillow & exposed - do not cover cast.	
	Davies	D Connor 1.30
5/5/46	1. ice packs & alcohol sponge to axillae & groin if temp. rises over 40°.	
	2. Aspirin 0/3 q 4° while awake.	
	Davies	V.E.R
5/7	D.C. aspirin	
	Davies	V.M. 5 pm
5/8	Aspirin 0/3 q 6° while awake.	
	Davies	V.E.R
5/15	D.C. penicillin & aspirin.	
	Davies	V. Montgomery 7 pm
5-21	Penicillin u. 20,000 i.m. q. 3 h	
	Balmer	M. Mickey
5-25	DC Penicillin	
	Balmer	D Connor 4.30
5-25-46	May be discharged to Mother	
	Jensen	D. Connor 1.00

0002506

[illegible]

SNOP CODED

AUG 25 1977

Summary by [illegible], (Ge.)

This [illegible] boy entered UCH on 4/17/46 [illegible] being flown from Australia because of X-ray Bx of either osteogenic [illegible] or [illegible] of ~~[illegible]~~ right knee.

Boy perfectly well until Jan 6 1946 when he fell a few feet from a hammock and injured rt knee. Follow 24 hrs in bed he seemed all right and played as usual. About 10 days later, mother noted tender mass on inner aspect of knee which did not cause disability, however swelling became larger and on Feb 20th X-rays were dx'd as fractured femur [illegible], and leg was placed in cast. On March 14th a radiologist in Sydney dx'd Osteogenic Sarcoma.

There has been [illegible] of PI but appetite remains good. He has also been [illegible] temperature, exact elevation not known.

Course: Myringotomy of left ear on 4-76 when temperature to 40° Gradual drop in T° to normal on 4/28, then [illegible] rise to 40° on 4/29. Left ear draining [illegible] material & rt HT [illegible] & bulging so rt myringotomy was done.

P.E.

T° - 40° P 108 R 22

G.W. Somewhat irritable little boy, alert & cooperative [illegible] WD & W.N.

Skin & M.M. Normal

Nodes Small non-tender post cervical [illegible] ; firm enlarge inguinal nodes bilaterally.

0002501

AUG 25 1972

[illegible] no abnormalities

Eye: Conjunctivae + [illegible] EOM intact. Pupils [illegible] to light [illegible] [illegible]

Ear: [illegible] in both [illegible]

Nose: Septum intact in M.L.

Mouth: M.M. normal. Tongue normal. Good hygiene.

Throat: Sl. hypertrophied, non-inflammed tonsils

Lungs: Clear to P&A.

Heart: P.M.I. in 5th I.S. at M.C.L. ACD not enlarged. Sounds of good quality, rate 188 5 pulse deficit, sinus arrhythmia. Apical harsh systolic murmur

Abdomen } No abnormalities noted
Back }

Extremities.
Upper: normal
Left leg: normal
Rt. leg: Much pain on slightest motion or pressure. Knee + lower femur swollen but not hot nor red.

0002508

Neuromuscular: Grossly normal
Reflexes: Physiological, non pathological

Impression: Malignant Bone tumor of rt femur

SNOP CODED

[illegible]

C.C.

Pain and swelling of right knee — of about 3 months duration.

P.I.

This day was perfectly well on Jan. 6, 194[illegible] when he fell from a [illegible] a few feet from the floor, and complained of hurting his right knee. He was put to bed, awoke the next morning and apparently was quite normal, playing as usual. However, about 10 d. after the injury, the mother noted swelling on the inner aspect of his right knee, which was tender to pressure but didn't cause disability in playing or running.

The swelling gradually became more marked, and 3 weeks later he awoke crying (from pain in knee?), but the next day he was up playing, and he still had no fever, and joint wasn't red or hot 5 weeks [illegible]

On Feb. 20th, an X-ray was diagnosed as "fracture of fever c̄ large clot of blood" and on Mar. 3rd, the leg was placed in a cast. Plates were sent to a Sidney Aust. Radiologist who diagnosed "Osteogenic [illegible]" on Mar. 14th. In Sidney, several different radiologists called it either [illegible] or osteogenic [illegible] family decided to come to the U.S.

For the past month, there have been occasional feverish spells, but [illegible] temperature. He has been taking

0002509

[illegible]

P.H.

This was a F.T.N.D. – 9½ lb

Its growth and development were normal.

He was given unpasteurized milk.

Illnesses

(1) Occasional tonsillitis

(2) Rare colds

Immunization

(1) Diphtheria

(2) Vaccinated 5 d. ago

Operations

0

Accidents

See P1.

Allergies

0

Systems:

Essentially negative except for convulsions

[illegible] fever (?) as a baby

F.H.

F = L. + W. aet 46

M = L. + W. aet 37

1S = L. + W. aet 6

1B = L. + W. aet 8

[illegible] to T.B.

P.E. T = 37° P = 96 B.P. = 108/70

Gen.

[illegible] + nourished, very cooperative

[illegible]

0C02510

[illegible]

Essentially normal

[illegible]

[illegible] (tender)

Head

Normal shape + appearance. No tender areas.

Eyes

Pupils are r.r. + eq. react to l. + a.

Fundi normal.

Ears

Canals are reddened but drums - appear normal

Nose

No obstruction. Slight mucoid discharge

Mouth

Good hygiene.

Pharynx

Tonsils slightly enlarged - not odd.

Neck

No enlargements or stiffness.

Lungs

Clear to P. + A.

Heart

P.M.I. = 5th I.S. + 1 cm. outside M.C.L.

Sounds of regular rate + rhythm

At apex there is a loud, rasping, systolic (m) transmitted toward axilla

No diastolic component. Heard c change of position

Abdomen

No tenderness. L.S. + K. not palpated.

Back

No deformity or C.U.A. tenderness.

Extremities

Left = normal.

0002511

[illegible]

[illegible] by [illegible] when moved.
Swelling of rt. knee most marked on [illegible] (inner aspect). Also there is considerable tenderness especially on the inner aspect. There is slightly increased warmth, but not increased redness. (Gentian violet has been applied to area on inner aspect which was burned by compresses 1 mo ago.

Pathos

Physiological

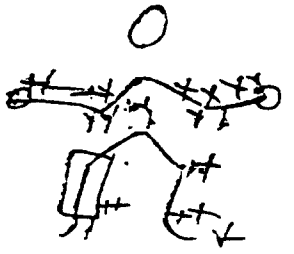

Summary:

1) R. knee injury on Jan. 6, 1946, but was apparently normal for 10 d. p. this.
2) Gradual increased swelling of r. knee of 3 mo duration.
3) Feverish spells for last month. (Tenth = ?)
4) Slight loss of weight in last month
5) Kenneth complains of pain in rt. knee when flexed or when pressure is applied
6) Loud systolic (m) at ~~right~~ apex (of heart)
7) Swelling + tenderness of rt. knee esp. on inner aspect of knee. Marked pain when flexion is attempted.
8) Sed rate (Mintzler) = 45 mm in 1 hr.

Impression:

1) Osteogenic sarcoma or (from history and x-ray)
2) Evingly tumor

Plan: [illegible] x-ray + [illegible] for

0002512

(3)

[illegible]

Eaver, J.C.
[illegible]

Blood + urine (on 4/17):

Hb = 98%
R.B.C. = 5.81 M
W.B.C. = 9,850
Diff. = P.M.N. = 55
Lymphoid = 41
MONO = 3
EOS = 4

Urine Sp. Gr = 1.0
P.H = 4.5
Alb = trace
Sugar = 0
Sed = 4-5 wbc / H.P.F.
otherwise neg.

Sed. rate = 45 mm / 1 hr.

Type = A.

Eaver, J.C.

4/18/75
alk. phosphatase - 11 (-0-5 [illegible]
acid " - less than 2 (0-2 [illegible]
[illegible]

Higher,
Pt. life is sore but otherwise he is unchanged.
He wants to see his mother almost continually.

Eaver, J.C.

0002513

[illegible]

[illegible] conference
and the [illegible] consultant of [illegible]
[illegible]
[illegible]
that this be tropical first before any
radical procedure be carried out on
the leg. However all present felt
that the leg should be removed
regardless of prognosis to alleviate pain
to a slough design. To be considered
further at later date.
Febrile 39° & seems to be rather
unhappy & not eating well.

Davies

4/7/16 — [illegible] is very good mood today,
and while he says that he feels warm,
he doesn't come otherwise affected by his
fever (which was 39° today)

Evans, J.C.

4/22 Calcium. - 8.6 mg %
phos. - - 4 mgm. %.

Davies

4/24 Febrile - 40.1°C. Since entry pt. has
continued c̄ high fever, usually
about 38°. Today he has risen considerably
higher and seems rather irritable &
refuses to eat but no specific complaints
[illegible] shows clear lungs (pt.
cooperative [illegible]) throat very slightly
injected. Abd. ō No CVA tenderness.
No cough or labored breathing
[illegible] No immediate evidence for
[illegible] except tumor. — will get CBC &
[illegible]

0002514

[illegible]

Davis

[illegible]

[illegible]

R.B.C. = 3.89 M.

Hb = 81%

Diff:

P.M.N. = 87% (19 N.F.)

LYMPHO = 14%

EOSIN = 2%

BASO = 1%

MONO. = 1

~~[illegible]~~ normal.

URINE:

PH = 7.0

Clear, yellow

$\bar{0}$ Alb

$\bar{0}$ Sugar

Sed:

2-3 wks./H.D.F.

Eames, J.C.

4/25/46 Pt.'s & tends down to 37° today and pt. feels much better. This is his lowest temp since day of entry. His leg pains him only when moved.

Eames, J.C.

4-26-46 8:30 AM. T = 39° Pt seen by Dr. Ryan & [illegible] in Pt Consult.
No subjective complaints except for pain of osteosarcoma.
Exam Left MT quite injected, [illegible] in the superior aspect a definite

0002515

[illegible] and
[illegible] of [illegible]
[illegible]
[illegible] by
a round [illegible] mass in the ant
portion of the canal immediately in front
of the drum. Mass has 3-4 hemorrhagic
[illegible] on superior surface, black line
on inferior aspect — perhaps mass pulsates.
MT portion seen, is injected though
less so than left. Landmarks
not visualized.
Nose moderate, chiefly dried, m-p
disch.
Throat [illegible] large, ragged, moderately
injected. Very little p-n I seen.
Lungs & heart clear.

Abdom soft, non-tender

Impression Bilateral otitis media,
acute, purulent.
Do not know what the
mass in rt canal is? Bleb on drum?
Advise ENT consult stat

Consider Myringotomy, chemotherapy.

[illegible] — W. Ryan

4/26/46 EARS [illegible] [illegible] [illegible] on the drum which was
[illegible] + serous fluid [illegible]. Left ear [illegible] described with
pars flaccida bulging. Left ear parasitosis + serous fluid
thin [illegible] under [illegible] pressure. [illegible]

0002516

4/29 - 1000. 37 - [illegible] has [illegible]
To [illegible] [illegible] [illegible]
[illegible] [illegible] [illegible]
[illegible] [illegible] [illegible]
[illegible] [illegible] [illegible] [illegible]
[illegible] [illegible] [illegible]
[illegible] [illegible]

[illegible]

4.27.46 Temp down to normal yesterday, but has risen to 39°C at 11AM today. Felt sore during morning rounds and at Rt sac on Bch on drum gate except for dried blood from right. NT quite injected bulbar c̄ Pandemic almost obliterated. No marked tenderness on either side. Phonos: Very mildly injected - yet coughing. Chest: Clear to percu.

Probably UMPA at now, and management, as that is probably indicated now.

Advise Management if ENT concur
Culture to show
Pick A - shenbard. as well as chemotherapy

[illegible]

4.29.46 Management [illegible] at HT. Mashbach
Allergy Hosp. Dr. [illegible] Culture to
[illegible]

[illegible]

4/29/46
Hbp 240/0
[illegible] 24 [illegible]

0002517

[illegible] 10

4/3 - Temp. has regularly fallen again today, following [illegible] - may be affected [illegible]. [illegible]

Davies

5/1 Temp. 38^3 Lft. canal filled c purulent material. Rgt. drum shows very little evidence of drainage.

Davies.

5-2-41. Both ears seemed granulating c still a little discharge beneath MT. Not injected; appear to be doing well.
[illegible] a little hard [illegible]. Throat now appears quite benign.
Lungs clear except for occas. rattles
(of course rhonchi & probably transmitted from U.R. tract.
Continued low grade fever probably due to the malignancy rather than the subsiding otitis and U.R.T. Of course can't rule out infection. [illegible] from lack of physical findings and [illegible] [illegible] [illegible]
[illegible] ultimate [illegible] that [illegible] [illegible] [illegible] I don't believe there is sufficient [illegible] infection to [illegible] D.C. [illegible]
[illegible]

0002510

[illegible]
[illegible]
[illegible]

[illegible signature]

[illegible]
Agree with Dr. Wilson.

Chorg [illegible]

Operative Note -
Date - 5/3/46
Operation - Biopsy of tumor of lower
Lft. Femur.
Surgeon - Dr. Larsen. Asst. - Dr. Capeller.
Oper. Findings -
The bony tumor was very roughly large, & extremely dense bone & very little vascularity. Very [illegible]
Procedure
The skin of right leg from groin to ankle was shaved, prepped and draped in usual manner.
A 6 inch incision was made on the lateral surface of leg just above [illegible]. This was carried down through the subcutaneous tissue to expose the [illegible]. The latter was incised longitudinally the length of [illegible] [illegible]. [illegible] was stripped along its [illegible] [illegible] the [illegible] exposed.
A large specimen was chipped from the [illegible] [illegible] [illegible]

[illegible]
[illegible]
[illegible]
[illegible]
[illegible]
[illegible]
sutures. The subcutaneous tissues & skin was closed c 7 60 cotton.

A light gauze dressing was placed over wound & the leg & foot placed in a posterior splint/cast. Patient was taken to ward in good condition.

Drains - 0
Fluids - 0
Specimen to U.C. Path. To Dr. Milkey & To Ortho. path. lab.

D. Davies

5/3 Resting quietly. Alert & comfortable. Able to take food & fluids.

Davies.

5/6/46 [illegible]

Treatment series to right lower femur started today.

H. Steinbach

5/10/46 [illegible]

Treatment series concluded today. Treatment was instituted only as a palliative measure to control pain with no attempt to destroy the tumor. This fact should be conveyed to the patient's physician in Australia.

H. Steinbach

5/12 Afebrile. Feeling fine. Edema subsided. Drug completed. Path. report unofficially showed an plastic tissue interpreted as [illegible] carcinoma. Dressing changed today.

0002520

[illegible]

[illegible]

Dawn

5/15 [illegible] slight [illegible] [illegible] in [illegible]. [illegible] [illegible] [illegible] [illegible] to show definite [illegible] in [illegible].

Dawn.

5-16 Pt. to be discharged whenever pt's. mother can make the necessary arrangements for the transportation back home.

(Coleman)

5-20 Called to see pt. tonight because of spike in fever to 39.5. On examination pt. is very hot and perspiring quite freely. Lungs are clear to auscultation and percussion - no cough. No CVA tenderness - no earache or sore throat. Can find no cause for sudden rise -

9[50]

Coleman

5-21 Pt's. temp. 39.0°. Unable to see rash on chest described by child's mother - child denies sore throat - tonsils hypertrophied but only slightly red - ear drums are normal. To be started back on penicillin

Coleman

5/31 C.B.C.

[illegible] / 79%

RBC - 4.3 M

WBC 14,750

Diff:

Polys - 64% F/NF 60/4

Lymphocytes 35%.

0002521

[illegible]

[illegible]

Entry [illegible]

Discharge 5-25-46

Diagnosis [illegible]

Treatment [illegible]

Course Pt. developed [illegible] & had [illegible]

Condition

on Discharge Fair

Advice Try to build child up as much as possible.

[illegible]

0002522