712869

Reprinted from CANCER, Vol. 43, No. 3, March 1979. Copyright, © 1979, by the American Cancer Society, Inc. J. B. Lippincott Company.
Printed in U.S.A.

EXPERIENCE WITH PION RADIOTHERAPY

MORTON M. KLIGERMAN, MD, CARL F. VON ESSEN, MD, MIRKUTUB K. KHAN, MD, ALFRED R. SMITH, PhD, CHARLES J. STERNHAGEN, MD, AND JOSE M. SALA, MD

REPOSITORY LANL/RC
COLLECTION Dr Off Files
BOX No. C-4 D66
FOLDER BAE 800-460 79

Forty-one patients with a total of 86 tumors were treated with negative pi mesons (pions) at the Los Alamos Meson Physics Facility (LAMPF) through December 31, 1977. An additional 30 tumors in the total patient population were treated with 100 kVp x-rays to assess comparative effects on skin nodules and 8 patients received additive photon or electron radiation to pion-treated portals. Of 52 evaluable tumors in 20 patients treated with pions only and followed for 3 to 22 months, 81% (42 tumors) completely regressed; 6% (3 tumors) partially regressed; and 13% (7 tumors) did not respond, although 5 of the 7 have shown no growth for 10 months. Of eight tumors in seven patients treated with a combination of pions and conventional radiation, three tumors showed complete response and five tumors showed partial response, though the resected specimens in two (one with complete and one with partial response) revealed no tumor microscopically. Reactions in normal tissues have been mild, with some patients exhibiting no normal tissue reaction, as compared with relatively marked tumor response.

Cancer 43:1043–1051, 1979.

BEST COPY AVAILABLE

COOPERATIVE STUDIES to test the potential of negative pi mesons (pions) in radiation therapy for advanced solid tumors are being conducted by the University of New Mexico Cancer Research and Treatment Center, Albuquerque, and the Los Alamos Scientific Laboratory, at Los Alamos, New Mexico. This paper summarizes preliminary results in a series of patients with primary and metastatic tumors of the skin, head and neck, lung, abdomen, and pelvis. They were treated with pions under Phase I and II studies to assess tolerance of normal tissues and tumor responses before randomized clinical trials can begin.

At Los Alamos, pions are produced by bombarding a carbon target with high energy protons. The protons are accelerated to approximately 760 MeV by the half-mile-long LAMPF linear accelerator. Negative pions produced by the proton-carbon interaction are collected, transported, and focused by an electromagnetic channel. The properties of the transport channel and its tuning have been described by Paciotti *et al.*[5] The dosimetry of the pion beams used in this study has been reported by Smith *et al.*[6] Negative pions have unique properties which led scientists to predict their usefulness in cancer treatment.[1] One of their advantages is the manner in which they can be shaped to produce damage to the tumor bearing volume, while largely sparing surrounding normal tissue.

Ionizing radiation can be classified according to its linear energy transfer (LET). When the ionization density per unit path length is low, the radiation is said to be characterized by low LET. X-rays, gamma rays, electrons, and protons are types of low-LET radiation. When the ionization density is high, the radiation is called high LET. Neutrons and heavy ions (such as those of helium, neon, or carbon) are examples of high-LET radiation. With high-LET radiation, there is a markedly increased capacity for irreparable damage of critical molecules (*i.e.*, double-strand breaks in DNA). This results in a biologic response different from that seen in conventional irradiation. Cells exposed to low-LET radiation exhibit up to three times more resistance to

Presented at the 60th Annual Meeting of The American Radium Society, New Orleans, Louisiana, April 26–30, 1978.

From the Cancer Research and Treatment Center and the Department of Radiology, University of New Mexico, Albuquerque, New Mexico, and the Los Alamos Scientific Laboratory, Los Alamos, New Mexico.

Supported in part by U. S. Public Health Service Grants No. CA-16127 and CA-14052 from the National Cancer Institute, Division of Research Resources and Centers, and by the U. S. Department of Energy.

Address for reprints: Morton M. Kligerman, MD, Director, Cancer Research and Treatment Center, 900 Camino de Salud, University of New Mexico, Albuquerque, NM 87131.

Accepted for publication September 11, 1978.

0008-543X/79/0300/1043 $0.95 © American Cancer Society

FILE BARCODE 00132971
COPIED FOR 00132971.001 HSPT
1087126

TABLE 1. Number of Sites/Number of Tumors Treated with Pions (Through December 31, 1977)

Site	Cases/Tumors
Brain:	
Primary (Glioma)	1/1
Metastases (Breast)	1/3
Skin and Subcutaneous Tissue:	
Primary	2/3
Metastases (Breast)	5/23
Metastases (Melanoma)	5/22
Metastases (Stomach)	1/2
Lip (Metastases)	1/2
Buccal Mucosa	1/1
Tongue	2/2
Nasopharynx	3/3
Larynx:	
Primary and Metastastic Neck Mass	2/3
Metastasis (Tongue)	1/1
Breast (Male)	1/1
Lung:	
Primary (Superior Sulcus)	1/1
Metastases (Tongue)	1/1
Metastases (Melanoma)	1/5
Stomach	1/1
Pancreas	4/4
Liver (Metastases)	1/1
Bladder	1/1
Rectum	3/3
Prostate	1/1
Sarcomas	1/1
TOTAL	41/86

injury if they are not well oxygenated. Thus, hypoxic cells, large numbers of which are usually present in tumors, are less sensitive to damage than are well oxygenated cells of the tumor and the surrounding normal tissue. Also, cells are more resistant to low-LET radiation in certain phases of the cell cycle than in others. The dense ionization of high-LET radiation overcomes the protective effect of hypoxia, killing those cells almost as effectively as well-oxygenated cells. High-LET radiation also reduces differences in cellular sensitivity due to cell cycle variations.

Neutrons differ from heavy charged particles in that the neutron dose in tissue is absorbed exponentially, similar to dose absorption of x-rays or the gamma rays of cobalt. Heavy charged particles, such as heavy ions and pions, distribute their dose with a Bragg peak, a region of intense radiation which can be located at the tumor volume.

Since pions deposit low-LET radiation as they pass through tissue (the plateau region), but produce a high-LET component in the stopping (tumor) region, they have advantages of both high-LET and low-LET radiation. Because they are negatively charged, the stopping pions are absorbed by the positively charged nuclei of oxygen, carbon and nitrogen atoms. This absorption makes the nuclei unstable and they disintegrate, producing neutrons, protons, deuterons, tritons, alpha particles, and heavy ions. These events increase the total dose in the pion stopping region, and alter the biological effectiveness of the dose in that region because of the dense ionization produced by the alpha particles, neutrons and heavy ions.

MATERIALS AND METHODS

In the early pion clinical studies,* seven patients underwent pion or x-ray irradiation of 65 metastatic tumor nodules in the skin. Results indicated that pions were 1.42 times more effective than 100-kVp x-rays in acute biological response of the skin.[4] One of these patients with 16 tumor nodules (primary breast) could be followed for 346 days before additional treatment was required, at which point data on time to regrowth of tumor were obtained to assess therapeutic gain. For repression of regrowth at 300 days, 37% more x-irradiation than equivalent doses of pions was required, indicating greater tumor effect by pions for the same amount of acute skin injury.[5]

Increased accelerator intensity has enabled treatment of larger and deeper tumors, progressing to lesions deep to the skin, then to tumors of the head and neck, pelvis, lung, abdomen, and brain, at escalating dosage levels for each different type of critical structure. As of December 31, 1977, forty-one patients with a total of 86 tumors had been treated with pions at LAMPF (Table 1). In addition, 30 tumors in the total patient population had been treated with 100 kVp x-rays to assess comparative effects on skin nodules (described above), and 8 patients had received additive photon or electron radiation to pion-treated portals. Additive conventional radiation therapy is needed on occasion because the maximum tolerated pion doses for the various normal tissues of the body (mucous membranes, lung, brain, etc.) are still being

* October–December 1974, and repeated June–August 1976. The Los Alamos accelerator was not available for patient use between January 1975–May 1976, mainly due to refurbishing for high intensity operations.

00132971.002

1087127

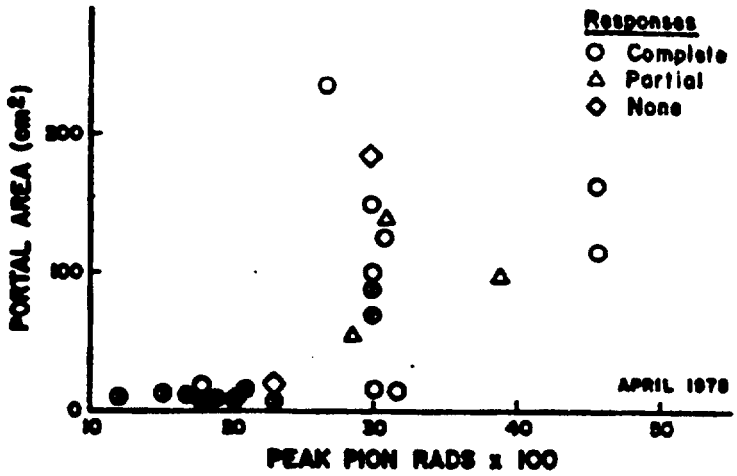

FIG. 1. The diagram shows gross tumor response of 52 evaluable cases treated with pions only, correlating area of treatment (which is related to tumor size) with pion dose. Responses noted are complete regression, partial regression (at least 25% but less than 100% of the largest diameter), or no regression (less than 25% of the largest diameter). The numbers inside the symbols represent the number of tumors with that type of response at that size and dose. This area of the chart is expanded in Fig. 2 for ease of interpretation. The analysis showed 42 tumors (81%) completely regressed, 3 tumors (6%) partially regressed, and 7 tumors (13%) did not respond. Five of the 7 lesions which did not respond are discussed in Fig. 2.

determined. To ensure patient safety, the National Cancer Institute-approved study design calls for relatively low doses at the start of treatment of each new type of body tissue. These doses are gradually increased for successive patients when no ill effects are observed in those patients treated with the lower doses. For patients whose tumors are not eliminated after relatively low doses of pion therapy and where there is relatively little normal tissue response, additional x-ray treatment is given to the pion-treated area. Other treatment is also given if the patient's condition warrants. Postpion surgery is given for curative intent, and chemotherapy for palliative intent.

Daily doses of peak pions for the small tumor areas varied from 90 to 180 peak pion rads a day. This variation was planned in the skin nodule study described above, to obtain a dose response curve to determine the relative biological effectiveness (RBE) for acute skin reactions and time delay to tumor regrowth. For the large tumor volumes, and for doses of 3000 rads and more, the daily maximum tumor doses varied between 100 and 137 rads.

The modulated pion peak was spread to dimensions of 5, 6, and 8 cm in depth. To attempt to maintain constant RBE across the peak, as determined by single and fractionated biological studies using induced growth delay of multicellular tumor spheroids (MTS), the

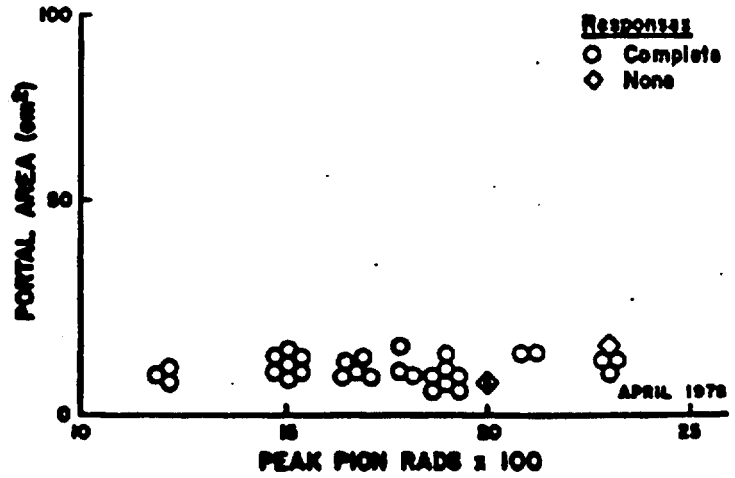

FIG. 2. This diagram is an expanded view of the multiple small lesions receiving from 1175 to 2300 rads of peak pions (see Fig. 1). The five lesions receiving 2000 rads which did not decrease significantly in size were five metastases to the lung, primary malignant melanoma of the thumb. However, these have not grown for the observed time of 10 months, although no further treatment has been given. See the text for a discussion of the remaining partial responders and nonresponders.

0185 0976
CODIED FOR 00132971.003 USPT
1087128

TABLE 2. Responses of Evaluable Tumors Treated with Pions and Conventional Radiation

Case no.	Portal area (cm^2)	Peak pion rads	x or e^- Rads/Elapsed time	Gross response
11	130	2807 + 5100e^-/4 weeks		Complete
12	80	1677 + 4180x/4.5 weeks		Complete
	80	1677 + 4180x/4.5 weeks		Partial
17	228	2667 + 2380x/2.5 weeks		Partial*
26	170	3000 + 2550x/3 weeks		Partial**
29	90	1900 + 4900e^-	/10 weeks	Partial
			2440x	
30	190	1800 + 3900e^-/7.5 weeks		Complete*
32	235	2400 + 4180x/4.5 weeks		Partial

* No tumor cells in resected specimen.
† Mass continues to regress after 9 months.

total dose in the proximal portion of the peak had to be increased over the total dose in the distal end of the peak. This is because of a greater amount of high-LET radiation in the distal end, as compared with the proximal end. In the beam with an 8 cm spread, a useful beam for deep-seated tumors, the distal end of the peak had a physical dose of only 70% of that of the leading edge. The dose is prescribed at the leading edge. Uniformity of dose distribution was obtained, when possible, by use of opposing portals.

FIG. 3. Case 17: Pretreatment lateral x-ray of a large presacral mass invading or intimately associated with demineralized anterior cortex of the sacrum. This 45-year-old female had a six-month history of low back pain with no symptoms linked with the colon or rectum.

In this report, an evaluable tumor was characterized as one in which 1) the peak pion portal area adequately covered the tumor; 2) the desired tumor dose, prescribed and recorded as the maximum dose to the tumor, was delivered; and 3) the patient survived sufficiently long to permit observation of complete disappearance or a plateau in gross tumor response. In addition to failure to meet these criteria, tumors not considered evaluable included those which were treated early in Phase I studies to begin to collect data on tolerance of the skin, lung, liver, gastrointestinal mucosa, and brain and to obtain some suggestion of the level of doses required to obtain a tumor response. Some patients participating in Phase I studies (particularly those with abdominal lesions) succumbed to disease outside of the peak pion treatment volume before adequate time had elapsed to assess the total response to pions.

At this writing, the variation in dose over the tumor volume must await reconstruction of the total tumor volumes and then the volume dose distribution. Preliminary calculations indicate peak pion doses in the tumor volume as low as 70% of the maximum doses.

RESULTS

Sixty tumors in 26 patients were evaluable, while 26 tumors in 15 patients were not evaluable. Analysis of data for 52 evaluable tumors in 20 patients treated with pions only and followed for 5 to 22 months from the start of treatment is presented in Figs. 1 and 2, which relate area treated, peak pion dose, and gross tumor response. The analysis showed 81% (42 tumors) completely regressed; 6% (3 tumors) partially regressed; and 13% (7 tumors) did not respond. The responses recorded are gross responses. Partial response is defined as equal to or greater than 25%, but less than 100%, reduction in greatest diameter.

The five lesions at 2000 rads (Figs. 1, 2) which did not respond represent five lung

00132971.004

1087129

nodules of metastatic melanoma, primary in the skin of the thumb. These received a total dose in 20 fractions over 37 days. Although there was no regression, there has been no growth and no evidence of radiation fibrosis at 10 months. The nonresponder at 2300 rads (Figs. 1 and 2) was one of four small melanomas. The other three did respond. It is of interest that the nonresponder grew in an area given prophylactic radiation some four years earlier at the time of the original "curative" operative procedure. The nonresponder at 3000 rads, 188 cm² portal (Fig. 1), was a rectal carcinoma. Although the bleeding stopped and the lumen opened sufficiently to stop the patient's symptoms of cramps and alternating constipation and diarrhea, the tumor did not meet the minimum criterion of 25% reduction in diameter required to place this tumor in the partial response category. However, there was no evidence of rectal mucosal change, acutely or during follow-up, now at 9 months. The tumor is now regrowing.

The partial responder at 2850 rads, 56 cm² (Fig. 1), was a large melanomatous metastasis in the submental region. The diameter of the tumor decreased to 50% of the original size and remained unchanged until the patient's death, four months later, of widespread disease. The treatment was given in 19 days, 15 fractions. A severe dry desquamation of the skin healed rapidly once the treatment was stopped.

The partial responder at 3100 rads, 140 cm² (Fig. 1), was a patient with an oral lesion extending from the left buccal mucosa into the trigone, over the gingiva and into the floor of the mouth, extending just short of the midline anteriorly. He had persistence localized to the gingiva at the end of treatment. Retrospectively, volume dose calculation revealed that this area received only 2000 rads. He has had a succesful resection, with primary healing and is alive without disease at five months after start of treatment.

It is believed that a major reason for partial response of the 3900 rads 100 cm² tumor (Fig. 1), was due in part to failure by the investigators to appreciate the lateral extent of the tumor. This patient had a massive base of tongue tumor, extending anteriorly into the floor of the mouth, with a deep fissure and severe trismus. At resection, a large amount of tumor was found involving the right carotid vessels. The surgeon indicated the normal tissues appeared in such excellent condition that he would not have known that any radiation had been given. The patient is alive without disease at 10 months.

FIG. 4. Case 17: Pretreatment CT slice shows a large presacral mass. Contrast medium is in the bladder to aid in localization of the pion beam to the mass with minimal treatment of the bladder.

Subsequent conventional radiation was added to pions when there was an incomplete response after the pion course and the normal tissue appeared to have responded minimally. Photons and electrons were used according to a treatment plan which would best limit the low-LET radiation to the pion treat-

FIG. 5. Case 17: After 1500 peak pion rads in 15 fractions, 19 days, only 75% of the tumor remained. Proctoscopy revealed normal rectal mucosa. The field was given an additional 700 rads of peak pions, 5 fractions, 5 days, followed by 2300 rads 10 MV photons in 14 fractions, 18 days, without further regression of the mass and no mucosal changes. Four weeks later, an uneventful abdominoperineal resection was performed. The specimen above shows the mass to be the residual tissue of involved lymph nodes. Multiple slices through this specimen were found to be negative for tumor on microscopic examination.

0185 0978

COPIED FOR
H 00132971.005

1087130

FIG. 6. Case 17: View of the mucosa after surgical resection with the original small ulcer completely covered with normal mucosa.

ment volume. Gross response of eight tumors in seven patients treated with a combination of pions and subsequent conventional radiation (x-rays and/or electrons) is presented in Table 2. Of these, three tumors showed complete response and five tumors showed partial response. However, two were excised (one with complete response and one with partial response), and no tumor cells were found on microscopic examination (cases 17 and 30).

In case 26 of Table 2, the major problem was a large, fixed left-sided neck mass. The primary laryngeal mass responded completely to treatment with pions only. At eight months the larynx is free of tumor, multiple biopsy



FIG. 7. Case 27: Pretreatment posterior-anterior x-ray showing a superior sulcus tumor. This 55-year-old male had a 1-year history of dyspnea and a 6-month history of pain in the anterior-superior left chest, as well as weight loss and fatigue.

proven, though there is a +1 residual laryngeal edema. The neck mass treated with combination therapy continues to decrease at each monthly observation, but is still palpable. The patient's skin showed at most only a Grade I erythema at the end of pion radiotherapy, when there was a reduction of the tumor to approximately 30% of the greatest diameter.

CASE REPORTS

Case 17

A 45-year-old female complained of pain in the low back for six months. She had no rectal symptoms, specifically no bleeding, diarrhea, constipation or change in bowel habit. A spasm of the rectum was noted on barium enema, and a large presacral mass was observed on lateral pelvic x-ray examination (Fig. 3). The decreased density of the anterior sacral cortex indicated either tumor invasion or tumor so intimately associated that its blood supply had decalcified the bone. The extent of the lesion could be seen on the CT scan, with contrast medium delineating the bladder (Fig. 4). Considered completely inoperable, this patient was the first treated in the pelvic region with pions. Through a portal of 12 by 19 cm, 2200 peak pion rads were delivered in 20 fractions, 36 days. At the end of treatment, 75% of the tumor was gone. The patient had no diarrhea and no bleeding. Proctoscopy twice a week revealed completely normal rectal mucosa. The residual mass was given 2300 rads of 10 MV photons in 14 fractions, 18 days. No further regression of the mass and no mucosal changes were noted. Four weeks later, an uneventful abdominoperineal resection was performed. Multiple sections of the residual mass (Figs. 5–6) revealed no tumor microscopically. The small original ulcer on the posterior rectal wall was well healed. The patient is alive and well 10 months after the start of pion treatment. There are no bladder symptoms. The vaginal mucosa is normal with no lateral fibrosis. The skin is very slightly tanned with very fine desquamation. There is no subcutaneous fibrosis.

Case 20

A 68-year-old male had a five-week history of a painless, semifixed submental mass on the right of the base of the tongue. The tumor extended from the vallecula almost to the dorsum of the tongue. It was fixed to the larynx mesially and extended anteriorly and then along the lateral wall of the pharynx to the posterior pharyngeal wall. The biopsy showed a Grade III epidermoid carcinoma. The patient received 3000 peak pion rads in two courses, 27 fractions in 47 days. The primary tumor disappeared after only 1500 rads. At the end

COPIED FOR HSPT 00132971.006

1087131

of treatment, the faucial region and pharynx had a 3 mm patch of pseudodiphtheritic membrane, but otherwise the normal tissues were almost free of reaction. The patient received a planned right radical neck dissection and is alive and free of disease at 10 months. *Remarks*: Rapid complete tumor regression with little normal tissue reaction.

Case 27

A 55-year-old male had a one-year history of dyspnea and a six-month history of pain in the anterior-superior left chest, as well as weight loss and fatigue. Routine x-ray examination revealed a large superior sulcus tumor (Fig. 7). Computerized axial tomograms showed an additional large mass in the left mediastinum and in the retrosternal region (Fig. 8). The biopsy revealed a poorly differentiated epidermoid carcinoma. The patient received a total of 2700 peak pion rads in two courses, 23 fractions over 42 days. The computerized tomographic (CT) films at eight months are negative (Fig. 9). There is no evidence of pulmonary fibrosis.

FIG. 8. Case 27: Pretreatment CT slice inferior to the gross mass in Fig. 7 reveals a large tumor mass in the hilum and retrosternal space, not appreciated on routine study.

Case 30

In 1974, a 56-year-old female developed a recurrence of a well-differentiated basal cell carcinoma of the anterior chest wall which had been "completely" removed surgically two years earlier. She tolerated this lesion until repeated hemorrhaging brought her to her physician. The tumor had an area of 10 cm × 15 cm, and completely undermined the skin. The base below the level of the subcutaneous tissues was infected with *B. proteus*. The tumor depth was estimated to be 4 cm. Many bridges of tumor, thinly covered with epithelium formed a grid over the infected base (Fig. 10). She was given 1800 peak pion rads in 11 fractions, 14 days. Two 3 cm areas of moist desquamation occurred as the epithelium lost its nutritional support with the marked tumor regression. Five weeks after treatment, regression amounted to 80% and the surrounding tissues appeared to be in excellent condition. Additional conventional radiotherapy, 3900 rads of 12 MeV electrons, in 23 fractions over 33 days, was added and well tolerated, an indication of the relative tolerance of the normal skin to pion therapy. Six months after the start of pion therapy and two months after the additional electron beam treatment, a 5 cm diameter area of tissue loss remained (Fig. 11). The ulcer was excised and the wound grafted. Multiple sections through the surgical specimen revealed no tumor cells. There has been no recurrence.

Case 34

A 57-year-old male presented with a history of right-sided VI nerve palsy for four months, right-sided headache for two months, and numbness of the right face for two weeks. A large right-sided nasopharyngeal tumor was biopsied and reported as a poorly differentiated epidermoid carcinoma. He received 3000 peak pion rads in 24 fractions over 38 days with a five-day separation between two courses. The tumor disappeared after 1900 rads. Three days after treatment the pharynx showed only injection, a first-degree mucositis (there was a small patch of second-degree reaction). This rapidly healed and at three months the mucosa was normal. There is no evidence of disease at five months. *Remarks*: Again, rapid complete regression with modest normal tissue reaction.

FIG. 9. Case 27: CT slice at 8 months posttreatment reveals no evidence of tumor or pulmonary fibrosis. The patient is alive and functioning at his presymptomatic level.

COPIED FOR HSDT 00132971.007

1087132

FIG. 10. Case 30: Pretreatment view of recurrent basal cell tumor of the anterior chest wall. The tumor completely undermined the skin, with the base below the level of the subcutaneous tissues infected with *B. proteus*. Evidence of hemorrhage, which brought this 56-year-old female to her physician, and many bridges of tumor covered with a thin layer of epithelium are shown by the photograph.

FIG. 11. Case 30: Posttreatment view 6 months after the start of pion therapy. (1800 peak pion rads in 11 fractions, 14 days) and subsequent electron therapy (3900 rads of 12 MeV electrons, given in two courses, 23 fractions, 33 days). The ulcer was excised and a primary skin graft performed. Multiple sections through the surgical specimen revealed no tumor cells.

DISCUSSION

While these data are still anecdotal and must be proved by prospective randomized clinical trials, they are indicative of a trend toward therapeutic gain for pions, for sites other than skin, where such a gain has already been suggested.[8] It appears that maximum toxic doses have not yet been reached in any of the various tissues under study. In all the patients treated, the normal surrounding tissues have shown only mild acute reaction or, in many patients, essentially no reaction. For example, no patient undergoing pelvic irradiation has developed diarrhea. At the same time, many tumors have regressed two to three times faster than would be expected with ordinary x-rays. No significant untoward effects have been observed in any patient treated with pions, over observation times ranging from 5 to 22 months. No radiation sickness was encountered in any treatment site. For these reasons, the pion doses are being raised 10% in the next treatment cycle.

An analysis is currently in progress examining the relationships between tumor size, dose, normal tissue reaction, tumor response, and length of remission in patients treated to date.[8] The principal problem in pion radiotherapy is the development of reliable computerized treatment planning, which shows complete volume distributions of the low- and high-LET components of the pion beams and the transformation of these distributions to effective doses. Until this type of data is available, full assessment of the cause of some failures will not be possible.

However, sufficient dose information is available to permit a rapid completion of Phase I–II studies at least in the head and neck and the pelvis so that initiation of Phase III trials for some sites should be possible by 1979.

Protocols for Phase III clinical trials are completed for various types of large solid tumors which are not well managed by any other treatment or combination of treatments, to attempt to improve local/regional control as well as long-term survival. The criterion of success of the project will be a two- to threefold improvement in five-year survival rate, since the research team believes that less than this in tumors with a 5 to 20% five-year survival rate would not be deemed sufficient

COPIED FOR HSDT 00132971.008

1087133

justification to recommend support of additional pion facilities throughout the nation. It is believed that combination therapy will be necessary for long-term survival because of the advanced disease status of the patients being accepted for treatment. Protocols have been developed for tumors of the brain (gliomas), head and neck, esophagus, superior sulcus of the lung, urinary bladder, stomach, pancreas, prostate, rectum, and uterine cervix.

REFERENCES

1. Fowler, P. H., and Perkins, D. H.: The possibility of therapeutic applications of beams of negative pi-mesons. *Nature* 189:524–528, 1961.
2. Kligerman, M. M., Wilson, S., Sala, J., von Essen, C., Tsujii, H., Dembs, J., and Khan, M.: Results of clinical applications of negative pions at Los Alamos. Proceedings, Third Meeting on Fundamental and Practical Aspects of the Application of Fast Neutrons and Other High LET Particles in Clinical Radiotherapy, The Hague, The Netherlands, Sept. 1978, Oxford: Pergamon Press (In press).
3. Kligerman, M. M., Sala, J. M., Wilson, S., and Yuhas, J. M.: Investigation of pion treated human skin nodules for therapeutic gain. *Int. J. Rad. Oncol. Biol. Phys.* 4:263–265, 1978.
4. Kligerman, M. M., Smith, A., Yuhas, J. M., Wilson, S., Sternhagen, C. J., Helland, J. A., and Sala, J. M.: The relative biological effectiveness of pions in the acute response of human skin. *Int. J. Rad. Oncol. Biol. Phys.* 4:333–339, 1977.
5. Paciotti, M. A., Bradbury, J. N., Helland, J. A., Hutson, R. L., Knapp, E. A., Rivera, O. M., Knowles, H. B., and Pfeuffer, G. W.: Tuning of the first section of the biomedical channel at LAMPF. *IEEE Trans. Nucl. Sci.* NS-22:1784, 1975.
6. Smith, A. R., Rosen, I. I., Hogstrom, K. R., Lane, R. G., Kelsey, C. A., Amols, H. I., Richman, C., Berardo, P. A., Helland, J., Kittell, R., Paciotti, M., and Bradbury, J.: Dosimetry of pion therapy beams. *Med. Phys.* 4:408–413, 1977.

COPIED FOR
HSPT
00132971.009

1087134

COPIED FOR
HSPT

00132971.010

1087135