709965

stimulating factor (FSF) activity in certain animal systems (3,4). Thus the response to HCG can not be directly equated to that which might be obtained with human (HLH) administration.

Despite these limitations, certain working concepts have emerged from clinical studies in patients with hypogonadotropic hypogonadism which in the main correspond to the information derived from animal studies where more pure pituitary gonadotropins of animal origin have been used.

This report will summarize our experience with respect to the testicular response following HMG and HCG administration. Preliminary studies with HLH or human growth hormone (HGH) treatment will also be presented.

A. EFFECT OF HMG ON THE IMMATURE GERMINAL EPITHELIUM

Although FSH and LH act in concert during normal puberty to produce testicular maturation, we desired to determine whether or not FSH could stimulate immature germinal epithelium. Therefore HMG was administered to three hypogonadotropic patients as their initial form of gonadotropic therapy (D.L., C.H., D.D., see Tables 1, 2, 3, 4). The details of these patients' clinical, hormonal and testicular status before and after treatment have been documented previously (5-7). The dose of HMG was adjusted in an attempt to administer that dose of FSH which had been shown to stimulate ovarian follicular growth and later to restore spermatogenesis after hypophysectomy (8). At the same time we endeavored to keep the LH dose low enough to avoid Leydig cell stimulation. This latter point had no precedence since the minimal effective dose for LH action on Leydig cell function is unknown. The daily FSH dose ranged from 27.3 (raised to 81.9 I.U. in patient D.L. after two weeks) to 148.6 I.U. and for LH was 42.5 to 261.2 I.U. Treatment was carried out for five and one-half to six weeks. Essentially two types of response were noted. In patient D.L. the seminiferous tubules remained the same size and no proliferation of the immature germinal epithelium occurred. (See photomicrographs published in reference 5).

On the other hand, in patient C.H. the mean seminiferous tubular diameter increased from 58.6 $\mu \pm 1.5$ to 71.0 $\mu \pm 1.4$ (5). However no proliferation of germinal cells was noted, e.g. control, 42.7 $\pm$ 2.1 cells per tubular cross section and 49.1 $\pm$ 2.3 cells per tubular cross section following HMG therapy. C.H.'s LH dosage was the highest of the three patients, ranging from 130.6 to 261.2 I.U. per day. Furthermore his plasma testosterone level increased from a control of 0.05 μg% to 0.11 μg%, which suggests that his interstitial cells were stimulated by the administered LH in his HMG preparation. In patient D.D. two different sized tubules existed before treatment (Table 1). This observation might be related to

1066741

DOE/HQ

Table 1. Seminiferous Tubule Diameter in Normal Adult Males and in Males with Prepuberal Hypogonadotropic Hypogonadism.

Patient	Age (yrs)	Diagnosis	Mean Diameter (μ) of 10 Circular Tubules	
RV 11	27	Normal male	189.6	
RV 16	36	"	185.4	
RV 20	50	"	162.6	
RV 28	30	"	166.6	Group Mean 171.8 ± 12.0 (S.D.)
RV 32	46	"	174.0	
RV 38	24	"	156.6	
RV 53	41	"	168.0	
M.B.	23	Hypogonadotropic eunuchoidism	55.4	
B.S.	25	"	57.3	
J.P.	20	"	62.7	
F.H.	19	"	59.3	Group Mean 62.1 ± 8.8 (S.D.)
C.H.	17	"	58.6	
D.D.	22	Craniopharyngioma [a]	79.5 (96.1)[b]	
E.J.	28	Idiopathic selective pituitary deficiency[c]	66.6	

a. Patient had TSH and gonadotropin deficiency. ACTH secretion was presumed to be normal by testing; HGH secretion presumed normal because of his normal height. He was on thyroid replacement therapy.

b. Two populations of tubules in biopsy specimen. Smaller tubules used for group mean calculations.

c. Sella turcica as well as suprasellar area was normal. Decreased HGH, FSH, LH secretion by radioimmunoassay or bioassay testing. Presumed normal TSH and ACTH secretion by appropriate testing, e.g., RAI uptake, PBI, response to metapirone, 17-ketogenic steroid excretion.

1066742

DOE/HQ

Table 2. Hypogonadotropic Hypogonadism Pretreatment Studies

Patient	Age	Urinary Gonadotropins GGA	FSH	Urinary Estrogens	Plasma Testosterone
D.L.	20	<0.7	-	<0.2	-
J.P.	20	<0.7	-	<0.2	-
M.S.[a]	20	-	<3.8, 1.6	<0.2	0.05
H.G.	24	<0.7, 0.9	-	-	0.02, 0.02, 0.15
G.G.[a]	19	<0.7	-	-	-
D.D.	21	<0.7	-	<0.2	-
P.N.	16	<0.7	-	<0.2	-

Hormonal data before treatment. GGA refers to a general gonadotropin assay method which measures the combined effect of FSH and LH. (Normal adult male range 0.7 - 3.8 mg. -eq. per 24 hours). Urinary estrogens determined biologically. (Normal adult male range 0.3 - 3.0 μg. -eq. estradiol benzoate per 24 hours). Plasma testosterone by double isotope derivative method. (Normal adult range 0.23 - 1.44 μg. %.) a Patients with anosmia.

previous therapy with methyl testosterone, since exogenous androgen can stimulate the immature seminiferous tubule to some extent. Only general gonadotropin assays were conducted prior to treatment so that the precise status of his endogenous FSH and LH levels is unknown. Following HMG therapy the mean seminiferous tubular diameter of D.D. increased to 109.3 ± 4.5 μ. At this time an increase in germinal cell numbers was also noted, but maturation had not progressed beyond the cell type noted before treatment, i.e., the pachytene spermatocyte.

These data could be interpreted in the following manner: FSH by itself does not affect the immature seminiferous tubule unless Leydig cells are stimulated by concomitant administration of LH or unless the seminiferous tubules have been previously exposed to endogenous or exogenous testosterone. de Kretser (9) noted early seminiferous tubular maturation and an increase in plasma testosterone levels in a patient with hypogonadotropic eunuchoidism when the FSH/LH dosage was 200/500 I.U. three times weekly for five months. Rosemberg et al. (10) in their studies on prepuberal males with cryptorchidism noted germinal cell stimulation and early Leydig cell maturation following HMG therapy of equivalent or higher FSH and LH doses.

1066743

DOE/HQ

Table 3. Summary of Histologic Findings in Hypogonadotropic Hypogonadism before and after HCG Therapy

Patient	Previous Therapy	Duration HCG Therapy (weeks)	Most Advanced Germ Cell Type	
			Before HCG	After HCG
D.L.	HMG (7 wks)	23	Immature germinal epithelium	Early differentiation of spermatogonia
J.P.	None	59	"	Sd Spermatid
D.D.	1) intermittent methyl testosterone (? yrs) 2) HMG (6 wks)	25	Pachytene spermatocyte	Sd Spermatid
P.N.	None	56	No biopsy	Pachytene spermatocyte
E.J.	1) "Pituitary" shots (1 mo duration, age 14) 2) HGH therapy (15 wks)	10	Pachytene spermatocyte	Sc spermatids

1066744

DOE/HQ

Table 4. Studies to Induce Spermatogenesis in Hypogonadotropic Hypogonadism

Patient	Age	HCG Duration of treatment (weeks)	HCG Sperm Count mill/ml	HCG-HMG Duration of treatment (weeks)[c]	HCG-HMG Sperm Count mill/ml	Highest Sperm Count
J.P.	20	59	Azoo	7	1-2/hpf	39[b]
M.S.[a]	20	16	59	-	-	71[b]
H.G.	22	85	(42)	-	-	(42)
G.G.[a]	19	78	Azoo	5	1/hpf	1-3/hpf
D.D.	22	25	Azoo	15	1-2/hpf	14.7
E.J.	28	30[d]	Azoo	13	0.3	48
P.N.	16	56	Azoo	19	occasional dead sperm	

In patient H.G., the bracket surrounding the sperm count indicates that this was the only specimen obtained. a. Patients with anosmia. b. Patients who were married and achieved a pregnancy. c. Duration in weeks refers to that interval between onset of treatment and the first appearance of sperm in the ejaculate. d. During the last twenty weeks HGH therapy was added.

B. EFFECT OF HCG ON THE IMMATURE TESTIS

Seven patients received HCG therapy at a dosage of 2000-5000 I.U. three times weekly for 16 to 85 weeks. Four patients (D.L., J.P., P.N., G.G.) exhibited the classic form of hypogonadotropic eunuchoidism, i.e., no discernible evidence of effective endogenous gonadotropin secretion. Two of the seven patients (M.S., H.G.) were considered as variants of the syndrome resembling the subcategory "Fertile Eunuch." Both men were devoid of androgen effects and demonstrated very low plasma testosterone levels (see Table 2). On the other hand, urinary FSH excretion was at the lower limit of the normal adult male range on one occasion in patient M.S. Patient H.G. exhibited a normal urinary GGA (general gonadotropin assay) titer on one of two occasions while his control testicular biopsy specimen revealed seminiferous tubular stimulation. The mean tubular diameter was 116.4 $\mu \pm 18.6$ and spermatogenesis had progressed to the Sd spermatid level. The remaining patient, D.D., has been described before (Table 1 and section A).

In the patients who demonstrated positive evidence of endogenous FSH secretion prior to treatment, therapy with HCG alone pro-

1066745

DOE/HQ

duced full spermatogenesis including spermatozoa in the ejaculate. This response occurred within 16 and 85 weeks, respectively. Patient H.G. was unable to submit a seminal fluid specimen until the 85th week of treatment. Therefore we are uncertain as to the exact time that full spermatogenesis developed.

The remaining five patients were still azoospermic at the completion of HCG therapy alone. Treatment lasted 25 to 78 weeks (Table 4). Despite the azoospermia, examination of the testicular biopsy specimens in D.L., J.P., D.D., and E.J. revealed that spermatogenesis had been stimulated by HCG therapy in each patient where a pre-HCG biopsy was available for comparison (Table 3, Figs. 2,3). The question as to why HCG therapy by itself should initiate spermatogenesis in these hypogonadotropic "prepuberal" patients remains unclear. The fact that sufficient endogenous FSH secretion existed in patients M.S. and H.G. affords a plausible explanation as to why Leydig cell function plus full spermatogenesis was achieved by only HCG therapy. However no such evidence was present in patients D.L. and J.P. It may be that the "FSF" activity present in HCG permits germinal cell stimulation. On the other hand, it may be that the endogenous testosterone secretion initiated by HCG therapy has a definite but limited action with respect to stimulating spermatogenesis. Lastly it is possible that LH acts directly on the germinal epithelium. Definitive conclusions will have to wait until purified HLH is used in similar patients.

C. EFFECT OF COMBINED HCG-HMG TREATMENT

Five patients received combined HCG-HMG therapy of varying dose schedules when solo HCG treatment of 25 to 78 weeks was still associated with azoospermia (Table 4). The treatment schedule is listed below:

	HCG (I.U., t.i.w.)	FSH (HMG) (I.U.)
J.P.	2000	64.5 - 74.3 daily
D.D.	2000-4000	63.0 - 74.3 daily
G.G.	4000	150 t.i.w.
E.J.	4000	75 t.i.w.
P.N.	4000	75 t.i.w.

The addition of HMG (FSH) to the therapeutic regimen was successful in four out of the five patients as measured by the appearance of spermatozoa in their seminal fluid (Table 4). It required from 5 to 19 weeks of combined HCG-HMG therapy for this event to occur. Seminal fluid specimens were submitted for analysis once weekly. The varying HMG (FSH) dosage did not appear to affect the response to treatment in this limited study. HCG-HMG administration was continued to a maximum of four years (J.P., see reference 6). The highest seminal fluid sperm concentration was achieved in

1066746

DOE/HQ

E.J. (48 mill/ml) after a total of 60 weeks[1] of combined therapy. In J.P., the highest sperm count noted was 39 mill./ml. HMG therapy was discontinued in P.N., D.D. and G.G. after 34, 45 and 32 weeks, respectively.

It is difficult to explain why combined HCG-HMG therapy did not produce numerically greater sperm counts. Fundamental information pertinent to this point is lacking. That is, at what point in time do males attain normal sperm production during their puberal process? Until these data are obtained, we have to consider the following possibilities: 1) treatment did not last long enough, 2) the proper FSH/LH ratio was not employed, 3) HCG exerts an action which is qualitatively different from that exerted by HLH, 4) the testis as well as the pituitary-hypothalamic system is defective in patients with this syndrome. (11)

It is also possible that the multiple biopsies employed to document the response to treatment might have influenced sperm production. However, no testicular biopsy was performed in patient G.G.

Only two patients were married while receiving treatment (J.P., M.S.). J.P.'s wife became pregnant twice and delivered two normal male infants. M.S.'s wife became pregnant once and delivered a normal female infant.

D. EFFECT OF HLH ON LEYDIG CELL FUNCTION

The dose of administered HLH required to produce normal Leydig cell function has not been established. Therefore we initiated studies in our patients with hypogonadotropic eunuchoidism in an effort to obtain this information. Data from our HMG therapy experience (see discussion patient C.H.) suggested that the effective HLH dosage might approximate 200 I.U. per day.

M.S. (Tables 2,4) who had received HCG for over three years was selected for study. His current HCG dose was 2000 I.U. three times weekly and his sexual maturation was essentially complete. Just prior to starting HLH and twenty-four hours after his last dose of HCG blood was sampled for plasma testosterone assay (see Table 5). The value was 1.2 μg % (normal adult male range 0.28 - 1.44 μg % (12)) which confirmed our clinical judgment that he was receiving optimal HCG therapy.

During the four weeks of HLH treatment (400 I.U. three times weekly) M.S. stated that he experienced vasomotor symptons, e.g. hot flashes, on those days he did not receive his medication. Li-

1. There were two periods of therapy, 28 weeks and 32 weeks, with a one-year interval between.

1066747

DOE/HQ

Table 5. Comparison Between HCG and HLH Administration in terms of Leydig Cell Function (Patient M.S.)

Hormone	Dosage Schedule	Duration of Therapy at Indicated Dosage	Time Interval Between Treatment and Blood Sampling (hrs)	Serum HLH Levels[c] (mIU/ml)	Plasma Testosterone (T) Levels[d] (µg %)
HCG[a]	2000 I.U. t.i.w.	43 wks	24	-	1.2
HLH[b]	400 I.U. t.i.w.	4 wks	12	9.4	0.23
HLH	400 I.U./d.	4 d	4	33.0	0.34
HLH	200 I.U./d.	4 d	8½	6.8	0.11
HCG	2000 I.U. t.i.w.	3 wks	24	-	0.63

a. HCG, Ayerst Laboratories; b. HLH-LER 856, lot A-1, 200 I.U./vial (VPW), kindly supplied by the National Pituitary Agency; c. Serum HLH assayed by radioimmunoassay method of Midgley (16); d. Plasma testosterone levels determined by a modification of the displacement technique of Nugent (17).

1066748

DOE/HQ

bido was reported to be normal but his sexual potentia had decreased slightly. Twelve hours after an injection of 400 I.U. HLH, his serum HLH level was 9.4 m.I.U./ml. but his plasma testosterone was 0.23 μg %, which is below the normal male range. His plasma testosterone increased to 0.34 μg % after four days of 400 I.U. HLH per day and dropped to 0.11 μg % after four days of 200 I.U. per day. Serum LH levels were 33 m.I.U./ml four hours after 400 I.U. of HLH and 6.8 m.I.U./ml eight and one-half hours after 200 I.U. He then returned to HCG therapy at his previous dose schedule. Androgen withdrawal symptoms disappeared one week after the resumption of HCG therapy, and his plasma testosterone titer was 0.63 μg % two weeks later.

These preliminary data indicate that for optimal maintenance of Leydig cell function in patients without endogenous LH secretion, HLH therapy using saline as the diluent will have to be administered daily at doses slightly above 400 I.U. These observations as to daily dose requirements are in keeping with the recent data on half-life studies for HCG and HLH (a fast and slow component for each: t 1/2 HCG = 11 hr, 23 hr; t 1/2 HLH = 21 min, 235 min). (13,14,15)

E. EFFECT OF HGH ON TESTICULAR FUNCTION

It has been suggested that when growth hormone and gonadotropin deficiency exist together the testes of prepuberal males are less developed than when only gonadotropin deficiency is present. (18) If this is true, HGH may exert a stimulatory action on the testis.

To evaluate this hypothesis we studied the effect of HGH therapy on patient E.J.'s testicular function (Table 1). This patient demonstrated deficient HGH and gonadotropin secretion with intact thyroid and adrenal cortical function. Testicular biopsy specimens were obtained prior to and following HGH[2] therapy (5mg thrice weekly). Before treatment, examination of his biopsy specimen revealed an immature testis except for an occasional seminiferous tubule containing maturing germinal cells. The most advanced cell type observed was the pachytene spermatocyte (Fig.1). The mean tubular diameter in E.J.'s control biopsy specimen was comparable to that noted for patients with presumably normal HGH but deficient gonadotropin secretion (Table 1), 66.6 μ vs 62 ± 8.8 μ. After fifteen weeks of HGH therapy his biopsy specimen was unchanged (Fig. 2), including the mean tubular diameter (65.9 μ). At this time his plasma testosterone level was 0.04 μg %.[3] Since a control testosterone titer was not obtained, HGH was discontinued for three weeks

2. Kindly supplied by the National Pituitary Agency. Bioassay of this HGH preparation revealed the presence of 2.0 I.U. HLH and 4.0 USP units Prolactin per mg. No FSH activity was detected.

3. Performed by Dr. Hortense Gandy using the double isotope derivative method.

1066749

DOE/HQ

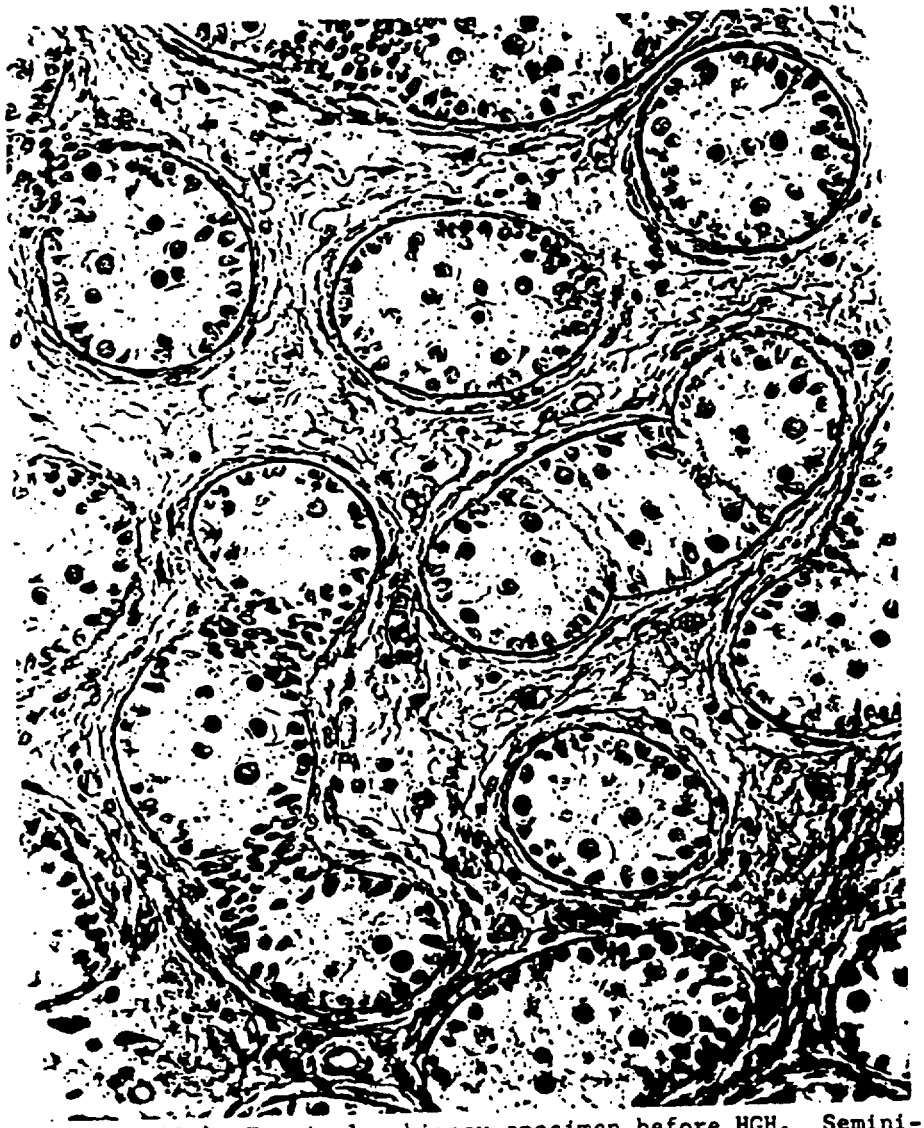

Fig. 1. (x 63.) Testicular biopsy specimen before HGH. Seminiferous tubules contain mainly an immature germinal epithelium with an occasional germ cell undergoing differentiation.

1066750

DOE/HQ

Fig. 1A (x 160.) E.J. before HGH, higher magnification. Note pachytene spermatocytes.

1066751

DOE/HQ

Fig. 2. (x 63.) E.J. testis specimen after HGH. Essentially no change in the number of cells undergoing maturation. Tubules are of the same size as before HGH.

1066752 DOE/HQ

Fig. 3. (x63.) Testicular biopsy specimen following HCG therapy Definite increase in tubular diameter. Spermatogenesis has been stimulated.

1066753 DOE/HQ

at which time his plasma testosterone level was 0.02 μg %. His body height increased 5/8" during HGH therapy. Thereafter his treatment consisted of HCG for ten weeks, then combined HGH and HCG for twenty weeks and finally HCG plus HMG for seven months. His third testicular biopsy specimen obtained after his combined HCG-HGH therapy (Tables 3 and 4) revealed active spermatogenesis (Fig. 3) which had progressed to the Sc spermatid stage. The mean tubular diameter had now increased to 93.8μ. Maturation of his interstitial cells into Leydig cells was evident and his plasma testosterone titer was 1.17 μg %.

There was no evidence in this patient that HGH had any effect on his testicular status. However these results do not reject the possibility that HGH might supplement the action of FSH and LH during testicular maturation in normal puberty.

ACKNOWLEDGEMENTS

These studies supported in part by NIH grants AM05161 and AM05436 and AEC contract AT(45-1)-2225-T6.

REFERENCES

1. Paulsen, C.A., The Testis, In Textbook of Endocrinology, ed. Williams, R.H., 4th edition, W.B. Saunders Co., Philadelphia, 1968.
2. Rosemberg. E., In Gonadotropins 1968, ed. Rosemberg, E., Geron-X, Inc., Los Altos,Calif. p 426, 1968.
3. Crooke, A.C. and Butt, W.R. J. Obstet. Gynaec. Brit. Comm., 66: 297, 1959.
4. Albert, A., J. Clin. Endocr. 29: 1504, 1969.
5. Paulsen, C.A., ed., Estrogen Assays in Clinical Medicine, University of Washington Press, Seattle, 1965.
6. Paulsen, C.A., In Proceedings of the Sixth Pan American Congress of Endocrinology, Mexico City 1965, Amsterdam, Excerpta Medica Foundation, p. 212, 1966.
7. Paulsen, C.A., In Gonadotropins 1968, ed. Rosemberg, E. Geron-X, Inc., Los Altos, Calif. p 491, 1968.
8. MacLeod, J., Pagianos, A. and Ray, B., Fertil. Steril., 17; 7, 1964.
9. deKretser, D.M., Thesis, M.D., Monash University, Melbourne, Australia, 1969.
10. Rosemberg, E., Mancini, R.E., Crigler, J.F. and Bergada, C., In Gonadotropins 1968. ed. Rosemberg, E., Geron-X, Inc., Los Altos, Calif., p 527, 1968.
11. Bardin, C.W., Ross, G.T., Rifkind, A.B., Cargille, C.M. and Lipsett, M.B., J. Clin. Invest., 48: 2046, 1969.
12. Paulsen, C.A., Gordon, D.L. Carpenter, H.M., Gandy, H.M. and Drucker, W.D., Recent Progr.Hormone Res., 24: 321, 1968.
13. Kohler, P.O., Ross, G.T. and Odell, W.D., J. Clin. Invest., 47: 38, 1968.

1066754

DOE/HQ

14. Yen, S.S.C., Llerena, O., Little, B. and Pearson, O.H. J. Clin. Endocr., 28: 1763, 1968.
15. Rizkallah, T., Gurpide, E. and Vande Wiele,R.L., J. Clin. Endocr., 29: 92, 1969.
16. Midgley, A.R. Jr., Endocrinology, 79: 10, 1968.
17. Mayes, D. and Nugent, O.A., J. Clin. Endocr., 28: 1169, 1968.
18. Albert, A., Underdahl, L.O., Green, L.F. and Lorenz, N., Proc. Staff Meeting Mayo Clinic 28: 698, 1953.

DISCUSSION

MACLEOD: Dr. Paulsen, in your studies with long-continued administration of HCG in eunuchoid patients in whom you observed some degree of maturation of spermatogenesis, have you taken into account the FSH-like activity contained in HCG?

PAULSEN: Yes, we have to consider that HCG has several effects on the germinal epithelium. One is by stimulating endogenous testosterone secretion. The other may relate to a direct action on the germinal epithelium by the FSH property of HCG. What we need is comparable data as to the effect of HLH on the immature testis.

ROSEMBERG: The amount of FSH activity intrinsic to the HCG molecule could be estimated and this will be negligible in the studies reported here.

DICZFALUSY: Making an approximation, I think it is fair to say that in most HCG preparations the FSH-like activity corresponds to 1 IU for every 1,000 IU of HCG. Hence, this amount of FSH will not really have any effect.

ROSS: Dr. Paulsen, when you report detecting no follicle-stimulating hormone activity in the urine of these eunuchoidal patients, what quantity of urine in relationship to the 24-hour output have you injected per animal? What is the nature of the extract which you used: fraction A, B, C? I ask these questions to emphasize the difference between "failure to detect" and "total absence" of activity.

PAULSEN: I tried to be careful by stating that the urinary gonadotropins were "undetectable" as opposed to "absent". In general we inject a 12-hour aliquot per assay animal. We have not defined the small amounts of urinary gonadotropins which may be present in these patients. All we can state is that there is less gonadotropin excreted in these patients than is present in normal adult males. We use fraction A for our assays.

1066755

DOE/HQ

PRINTED IN U.S