CONF-810595--1

BNL-29670

DISCLAIMER

Departments of Medicine[1] and Chemistry,[2]

Brookhaven National Laboratory,

Upton, N.Y., USA

and

Division of Ophthalmology and Department of Radiology, North Shore University Hospital, Manhasset, NY, Departments of Ophthalmology and Radiology, Cornell University Medical College, New York, NY[3]

and

Department of Psychiatry and Behavioral Science

State University of New York, Stony Brook

Stony Brook, New York[4]

MASTER

"Non-invasive Nuclear Detection of Choroidal Melanoma"

S. Packer,[1,3] R. M. Lambrecht,[2] R. G. Fairchild,[1]

A. P. Wolf,[2] H. L. Atkins,[1] I. Fand[4]

This work was supported by National Cancer Institute Grant CA24597 and CA22749.

DISTRIBUTION OF THIS DOCUMENT IS UNLIMITED

Malignant melanoma of the choroid in an eye with clear media can be diagnosed with an accuracy exceeding 95% with the use of the indirect ophthalmoscope. The clinician has need for a non-invasive test that will help in several situations, 1. eye with opaque media, 2. following small pigmented lesion and 3. assessment of choroidal melanoma before and after radiation treatment. The use of the diagnostic modalities of nuclear medicine, modified to ophthalmology, may be able to fulfill these needs.

There are three basic problems in the use of radiopharmaceuticals to diagnose intraocular melanoma. The first is the specificity of the pharmaceutical for the tumor. The second is the physical characteristics of the radionuclide that is labeled to the tumor-seeking chemical. The third is the biodistribution of the radiopharmaceutical and resultant tumor to background ratios that are critical for non-invasive detection. The last factor is related to the limitations of nuclear detection instrumentation. This paper will discuss our efforts to deal with these problems.

We have studied the biodistribution of over 30 radiopharmaceuticals thought to be tumor-seeking agents. Several animal models have been used. Initially our work was with the Greene melanoma in hamsters and more recently with the Harding-Passey Melanoma (13) in mice. The biodistribution studies were often erratic and it was not until we started using autoradiography and obtaining melanin analyses, that we realized the uneven distribution of pigment-affinic radiopharmaceuticals within the Greene melanoma. The distribution in the Harding-Passey was quite uniform, therefore we now use autoradiography in the Harding-Passey melanoma for screening potential radiopharmaceuticals. The results for biodistribution studies Packer (9), and autoradiography Fand (7), have been published and will not be repeated in their entirety in this paper.

From this work we concluded that there are several radiopharmaceuticals that are appropriate for use as melanoma localizing agents (Table 1).

The next problem is nuclear instrumentation. Blanquet (2) led the way with a dual pinhole collimator that we have further modified, by Bockslaff (3) and by Packer (10). In addition, we have had limited experience with two other detection systems. The ultrasound guided gamma probe, Wainstock (12) and a dual eye probe counting system designed by Packer and Lambrecht. We will report in this paper our results with our modified dual pinhole collimator and a pigment affinic agent (iodine-123 labeled quinoline) and a non-specific tumor seeking agent (gallium-67 citrate).

Methods

Biodistribution studies were performed primarily in the Greene melanoma in hamsters and Harding-Passey melanoma in mice. The techniques have been published by Packer, et al. (9). The melanin analyses were outlined by Watts, et al. (13) and the techniques for autoradiography have been described by Fand (7).

Our modification of Blanquets' (2) dual pinhole collimator has been described, Packer, et al. (10) Figure 1. For the sake of brevity we wish to emphasize results in this paper.

Results

Table 1 lists the biodistribution data of the radiopharmaceuticals with high tumor uptake and high tumor to background ratios.

Figure 2 shows the uneven distribution of sulfur-35 labeled chlorpromazine, a pigment-affinic agent, in the Greene melanoma. Figure 3 shows the even distribution of this same radiopharmaceutical in the Harding-Passey melanoma.

Table 2 shows the melanin content of various animal tissues. Table 3 shows that the variations seen in animal tissues do occur in human melanoma. Figure 4 shows the relationship between chlorpromazine uptake in the different animal models used. We feel that this difference is due to the different melanin content (13).

Table 4 shows the scan results with iodine-123 4,3-dimethyl-7-iodoquinoline (DMQ) and gallium-67 citrate using the dual pinhole collimator. Figure 5 shows the results of a positive scan with gallium-67 citrate. A quantitization can be obtained that may prove useful in following small tumors or tumors that have been treated with radiation.

Discussion

The conclusion reached from this work was that pigment-affinic agents may suffer in localizing melanoma since there is uneven and erratic melanin distribution from case to case. Therefore our efforts have more recently been towards false melanin precursors, such as thiouracil. Other investigators are also persuing these compounds as tumor localizing agents (1,4,5,11).

Results will vary with different animal models. We feel that the Harding-Passey melanoma, because of its more uniform melanin distribution, may be a better experimental model than the Greene melanoma. Obviously, a melanoma specific agent, rather than a melanin-specific agent, is more desirable. Of continued interest also is the 2-fluorine-18 2-D-deoxyglucose because of the resurgence of radiotherapy. The glucose utilization of an irradiated melanoma is expected to be less than in the untreated melanoma. Therefore, this agent is being considered for diagnosis and after treatment for evaluation of the status of the melanoma. The limitations of each of these radiopharmaceuticals as tumor localizing agents may necessitate dual isotope studies, i.e., melanoma-seeking

agent (e.g., quinoline, chlorpromazine) and a non-specific tumor-localing agent (2-D-deoxyglucose, gallium).

The limitations of the dual pinhole collimator and the resolution of the gamma camera may preclude the technique from being useful with small melanomas. The minimum detectable lesion has not been determined, (6) but in our hands it seems reliable only with large choroidal melanoma. The dual eye probe counting system with its increased sensitivity appears to be a more reasonable choice for following small melanoma. The pigment affinic agents may be inadequate for small melanomas, since the total amount of melanin in the eye (background) will be high. This is not the situation with large choroidal melanoma that are pigmented where the relative contribution of melanin containing ocular tissues that are background would be small. New tumor localizing agents that go to melanoma and not to normal melanin containing tissues will be needed. Our preclinical laboratory data with thiouracil indicate that when labeled with an appropriate gamma emitting nuclide it may be a more suitable radiopharmaceutical for following choroidal melanoma.

We acknowledge the help of Dr. A.B. Brill and technical assistance of Mr. Dennis Greenberg.

References

1. Bakker, C.N.M., Kaspersen, F.R., Van Langevelde, A., Pauwels E.K.J.: The Synthesis of ^{131}I-5-iodo-2-thioruacil with Iodo-gen™. Int. J. Appl. Radiat. Isot. 31(1980), 513-515.
2. Blanquet, P., Safi, N., Verin, M.B.P.: Radionuclide exploration in Ophthalmology. Int. J. Nucl. Bio. 2 (1975), 165-173.
3. Bockslaff, H., Dausch, D., Bornemann, H., Stoppler, L., Hundeshagen, H.: Nicht-invasiver nachweis intraokularer veranderungen mit einer gamma szintillationskamera. Alb. v. Graefes Arch. Klin. Exp. Ophthalmol. 211 (1979), 187-203.
4. Bockslaff, H., Kloster, G., Dausch, D., Schad, K., Hundeshagen, H., Stöcklin, G.: First clinical results using L-3-^{123}I-α-methyltyrosine for the non- invasive detection of intraocular melanona. Nuklearmedizin, eds. Schmidt, H.A.E., Wolf, F., Proc. 18th Meeting, Soc. Nucl. Med., Schattauer, Stuttgart, 1981, in press.
5. Dencker, L., Larsson, B., Olander, K., Ullberg, S., Yokota, M.: False percursors of melanin as selective melanoma seekers. Brit. J. Canc. 39 (1979) 449-456.
6. Evans, R.A., Bland, K.I.: Radionuclide scans not indicated for clinical stage I melanoma. Surg. Gyn. and Obst. 150 (1980), 532-534.
7. Fand, I., McNally, W.P.: The technique of whole body autoradiography in: Current Trends in Morphological Technique. Ed. J.E. Johnson, Jr., CRC Press, Inc. Boca Raton, FL, in press.
8. Packer, S., Redvanly, Lambrecht, R.M., Atkins, H.L., Wolf, A.P.: Quinoline analog labeled with iodine-123 in melanoma detector. Arch. Ophthalmol. 93 (1975) 504-508.

9. Packer, S., Lambrecht, R.M., Christman, D.R., Ansari, A.N., Wolf, A.P., Atkins, H.L.: Metal isotopes used as radioactive indicators of ocular melanoma. Am. J. Ophthalmol. 83 (1977), 80-94.

10. Packer, S., Lambrecht, R.M., Wainstock, M., Rogers, W.L., Margoulett, D., Goldberg, H.: Techniques for nuclear detection of intraocular melanoma. Nuklearmedizin, eds. Schmidt, H.A.E., Wolf, F. Proc. 18th Meeting, Soc. Nucl. Med., Schattauer, Stuttgart, 1981, in press.

11. Pauwels, E.K.J., Van Langevelde, A.: Personal Communication.

12. Wainstock, M.A., Rogers, W.L.: An ultrasound guided gamma probe for intraocular melanoma detection, in Nuclear Ophthalmology; (Croll, M.N., Brady, L.W., et al. (eds.)) J. Wiley and Sons, New York, 1976, 123-131.

13. Watts, K.P., Fairchild, R.G., Slatkin, D., Greenberg, D., Packer, S., Atkins, H.L., Hannon, S.J.: Melanin content of hamster tissues, human tissues and various melanomas. Canc. Res. 41 (1981), 467-472.

Figure Legends

Figure 1. Slit-lamp head positioning attachment for gamma camera. The eye pieces can be moved according to patient's interpapillary distance. Head strap is used to keep patient from moving.

Figure 2. Autoradiograph of ^{35}S-chlorpromazine distribution in the Greene melanoma (Hamster). Note the uneven distribution.

Figure 3. Autoradiograph of ^{35}S-chlorpromazine distribution in the Harding-Passey melanoma (mice). Note the even distribution.

Figure 4. Chlorpromazine distribution differs between the Harding-Passey and the Greene melanoma. The error bars show the greater variability in the Greene melanoma than in the Harding-Passey melanoma.

Figure 5. Dual pinhole eye "scan" obtained on patient with choroidal melanoma 48 hours after gallium-67 citrate.

Table 1

RADIOPHARMACEUTICAL UPTAKE IN MELANOMA

Radiopharmaceutical	Melanoma Model	Maximum Uptake(%)	Time (hrs)	Ratio Tumor/Blood
Sulfur-35 thiouracil	Harding-Passey	15.30	6	76.0
Indium-111 bleomycin	Greene	5.45	48	6.6
Gallium-67 citrate	Greene	4.87	48	14.9
2-Fluorine-18 2-D-deoxyglucose	Greene	2.32	2	17.8
Phosphorus-32-phosphate	Greene	2.25	72	8.3
Iodine-123-DMQ (4,3-dimethyl-7-iodoquinoline)	Greene	1.09	24	7.3

Table 2

MELANIN CONTENT IN VARIOUS ANIMAL TISSUES

Organ	Number of Samples	% by weight
Greene Melanoma (Hamster)	13	0.34 ± 0.11
Greene Melanoma Homogenates (Hamster)	5 2	0.44 ± 0.04 0.41 ± 0.005
Harding (Balb mouse)	5	0.68 ± 0.13
B-16 Melanoma (C57)	3	0.06 ± 0.02
KHDD Melanoma (C3H Mouse)	2	0.003 ± 0.001
Amelanotic Harding Passey	2	0.02 ± 0.003
Amelanotic Rabbit	1	0.01
Hamster Whole Eyeball	14	0.45 ± 0.11
C3H Mouse Whole Eye	3	0.40 ± 0.02
Hamster Tissues		
Liver	4	<0.0025
Lung	4	"
Blood	3	"
Brain	4	"
Heart	2	"
Spleen	2	"
Kidney	8	"
Gut	2	"
Muscle	1	"
Hamster Hair	1	0.39
Hamster Skin & Hair	1	0.13
Hamster Skin	2	0.13 ± 0.002

Table 3

MELANIN CONTENT IN VARIOUS HUMAN TISSUES

Human Melanoma Patient	Number of Samples	% by weight
1	3	0.84 ± 0.09
2	4	0.40 ± 0.2
3	1	0.34
4	1	0.09
5	6	<0.0025
6 metastatic melonama in Liver	3	0.41 ± 0.05
Lymph	3	0.44 ± 0.12
Bone	2	0.30 ± 0.06
Spleen	2	0.12 ± 0.03

Table 4

SUMMARY OF RADIONUCLIDE EYE SCANS

Patient	Radiopharmaceutical		% ^{32}P Uptake	Size (LxWxH) (mm)	Cell Type
LZ	^{123}I-DMQ	+	381	12x14x6	Epithelioid Necrotic
MG	^{123}I-DMQ	-	81	15x15x5	Mxd Cell
JM	^{123}I-DMQ	+	364	16x16x6	*
JL	^{123}I-DMQ	+	235	12x12x6	*
JW	^{123}I-DMQ	+	195	11x11x4	*
AD	^{123}I-DMQ	-	400	14x16x10	*
EE	^{123}I-DMQ	-	140	16x16x8	*
WE	^{67}Ga-citrate	+	494	14x14x6	Epithelioid
MB	^{67}Ga-citrate	+	320	10x10x7	*
AB	^{67}Ga-citrate	-	155	12x12x18	Spindle A/B
VG	^{67}Ga-citrate	+	200	16x14x6	*

*Patient treated with local radiation (iodine-125 or cobalt-60).





A


A
B

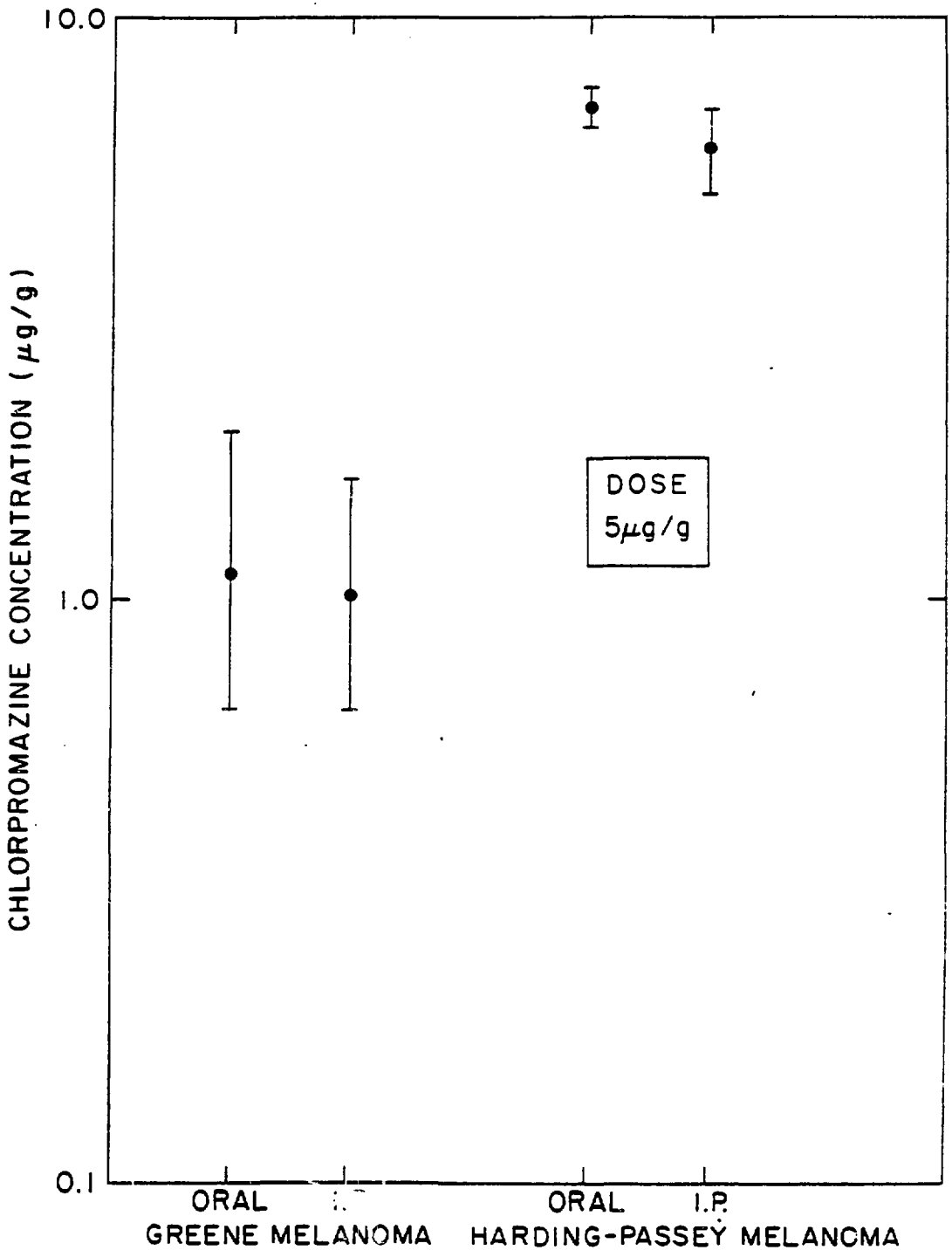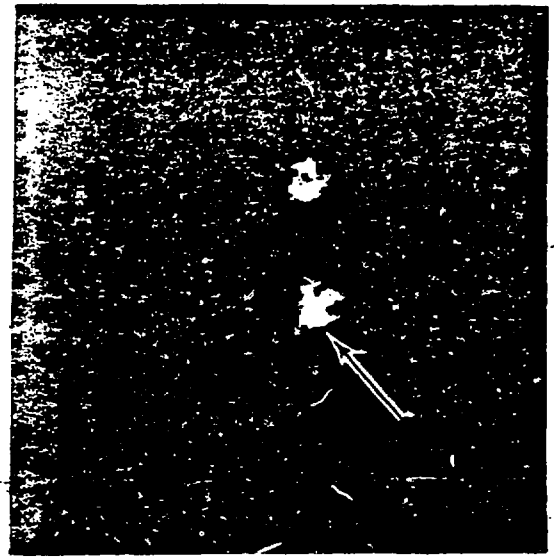
10.0
1.0
0.1
CHLORPROMAZINE CONCENTRATION (μg/g)
DOSE
5μg/g
ORAL
I.P.
ORAL
I.P.
GREENE MELANOMA
HARDING-PASSEY MELANOMA