Conf-740708--35

IAEA-SM-185/61

INTERNATIONAL ATOMIC ENERGY AGENCY

SYMPOSIUM ON DYNAMIC STUDIES WITH RADIOISOTOPES IN CLINICAL MEDICINE AND RESEARCH

Knoxville, Tennessee, USA, 15-19 July 1974

RECEIVED BY TIC JUL 26 1974

# $^{123}$I-Indocyanine Green ($^{123}$I-ICG) as an Agent for Dynamic Studies of the Hepato Biliary System

A.N. Ansari, H.L. Atkins, R.M. Lambrecht,
C.S. Redvanly, A.P. Wolf

Departments of Medicine and Chemistry,
Brookhaven National Laboratory
Upton, N.Y., 11973 U.S.A.

## Abstract

Indocyanine Green is exclusively extracted by hepatic polygonal cells and is excreted entirely in bile. It has no significant entero-hepatic circulation. These properties make indocyanine green a suitable agent for estimating liver function. Indocyanine green is commercially available and contains small amounts of sodium iodide. Development of a method to remove the sodium iodide adulterant allowed efficient labeling of the indocyanine green with iodine-123. The present study is a preliminary report of the distribution of $^{123}$I labeled indocyanine green in mice and dogs. Computer generated dynamic curves were obtained in rabbits. Serial scintiphotos were taken in normal and common bile duct obstructed dogs. Preliminary data indicates the feasibility of $^{123}$I-Indocyanine Green as a radiopharmaceutical agent for dynamic studies of the hepatobiliary system.

MASTER

DISTRIBUTION OF THIS DOCUMENT IS UNLIMITED

## INTRODUCTION

The medicinal use of dyes was appreciated as early as 1890, when methylene blue was recommended as an intestinal antiseptic. Since then various dyes have been used as diagnostic as well as therapeutic agents.

In 1909, Abel and Rowntree [1] introduced halogenated phthaleins for the study of hepatic physiology. Various dyes were investigated until Rosenthal and White, in 1925, reported the advantages of bromsulphalein (BSP) as a test of hepatic function [2]. Although the BSP liver function test is considered a sensitive one, it has the following main limitations:

1) There may be a local reaction at the site of the injection [3].

2) Severe generalized allergic (sometimes fatal) reactions can occur [4,5].

3) It can not be used in patients with jaundice.

4) Up to 20% renal excretion can occur in patients with severe liver disease [2].

In 1924 Delprat introduced the use of Rose Bengal as a liver function test [6]. Rose Bengal is taken up by, and stored in the hepatic polygonal cells rather than in the Kupffer cells of the liver [7]. It has a smaller ratio of extrahepatic clearance than that of BSP [8]. In 1955 Taplin et al. described $^{131}$I-labeled Rose Bengal as an agent for the determination of liver function [9]. The $^{131}$I-Rose Bengal test has been modified by various investigators but the use of radiolabeled Rose Bengal in the differential diagnosis of jaundice has not been universally accepted.

Another dye which has been commonly used for hepatic function tests is indocyanine green (ICC) first introduced by Fox et al.[10]. This dye (Fig. 1) is exclusively extracted and stored by polygonal cells of the liver before it is excreted into the bile. Hunton et al. have recovered over 97% of injected dye from the bile and have shown that this dye has no extrahepatic extraction

and that no ICG was detected in the urine of hepatectomized dogs nor in dogs or rats with biliary obstruction [11].

ICG has been extensively used in dye dilution curves applied to cardiac output measurement, coronary flow and for continuous recording of blood flow in the limbs. Since its introduction in 1957 it has been used in the study of hemodynamic changes during hemodialysis [12], measurements of pulmonary shunts [13], evaluation of the severity and progression of shock [14], angiography of the oculochoroidal circulation [15], estimation of blood volume [16], and as a test for determination of hepatic function [17,18].

Animal studies and human data indicated that:

1) the plasma decay is exponential or exponential in the initial stages.
2) it is rapidly and exclusively removed from the plasma by the liver and excreted in the bile.
3) the plasma disappearance rate is dose dependent [19].
4) there is no detectable urinary excretion of ICG [10].
5) it does not cross the placenta [20].

Taking these advantages into consideration, indocyanine green was thought to be potentially useful as a labelled compound for hepatic functional evaluation. This is a preliminary report on the evaluation of $^{123}$I-labeled ICG as an agent for liver function testing.

METHODS AND MATERIALS:

A. Preparation of $^{123}$I-ICG

Indocyanine Green ("Cardio-Green") was obtained from Hyson, Westcott and Dunning, Inc of Baltimore, Maryland. The commercial ICG contained 2-5% sodium iodide. The ICG was repurified to reduce the bulk stable iodine content to below the limits of chemical detection by x-ray fluorescence spectrometry.

We are presently evaluating several methods of labeling ICG. However, for this preliminary evaluation excitation labeling was used in order to introduce iodine-123 into the molecule [21]. Iodine-123 atoms and $^{123}I$-electronically excited ions resulting from the decay of xenon-123 via the nuclear transformation: $^{123}Xe \xrightarrow[2.1\ hr]{\beta^+,\ EC} {}^{123}I$ are the labeling species. See Fig. 1.

The BNL 60" cyclotron was used [22] to produce $^{123}Xe$ via the $^{122}Te$ $(\alpha,3n)$ $^{123}Xe$ nuclear reaction, or alternately, the $^{127}I$ $(p,5n)$ $^{123}Xe$ reaction was used at the Brookhaven Linac [23].

Less than 2 mg of the repurified, dried, crystalline ICG was placed in a pyrex reaction vessel, and carrier-free $^{123}Xe$ was adsorbed onto the dye at $77^{o}K$. After a decay period of approximately 6 hours, the remaining radioxenon was evacuated from the vessel, the ICG was dissolved, and the $^{123}I$-ICG was separated from the inorganic iodine-123. The specific activity of the $^{123}I$-ICG was generally 1-1.5 mCi/mg. The overall radiochemical yield was generally $\geq$ 10%. The radionuclidic purity was $\geq$ 99.8% as $^{123}I$, with the only radiohalogen impurity being $\leq$ 0.2% $^{125}I$.

The radiochemical purity was established by thin layer chromatography using aluminum oxide N. The developing solvent was: Pyridine: water: isopropyl alcohol: ammonia (4:4:12.5:0.4). The $^{123}I$-ICG, carrier free in iodine-123, was shown to be composed of at least two iodinated products, characterized by $R_f$ = 0.55 and $R_f$ = 0.80.

The free $^{123}I$-iodide was always $\leq$ 0.1% using either the above tlc system (iodide $R_f$ = 0.45), or on a tlc strip of silica gel and using 0.3 N HCl as the solvent gave iodide $R_f$ = 0.85 - 1.0.

B. Animal Experiments:

1) Tissue distribution in mice:

Mice were injected with 0.16 mg/kg to 43 mg/kg of ICG in the tail vein and tissue distribution studied from 30 seconds to one hour after injection. At least 3 mice were included in each group.

2) Dynamic studies in 2 rabbits were obtained through sequential imaging using a Searle Radiographics HP camera with a low energy parallel hole collimator interfaced with a Nuclear Data Med. II Computer System.

3) Five normal mongrel adult dogs were used to study the dynamics of biliary excretion of $^{123}$I-ICG. Three were used as controls. One dog had the common bile duct ligated surgically at its distal end near the duodenum 2 months prior to study. In another dog, an external fistula was created through a tube placed in the common bile duct, and a tie placed beyond the tube distally. $^{123}$I-ICG was injected intravenously as a bolus in doses of 35 uCi - 1.7 mCi. No dog received a loading dose of ICG greater than 1 mg/kg of body weight. Multiple blood samples were collected for estimation of blood disappearance rate of $^{123}$I-ICG.

RESULTS

The tissue distribution in mice receiving different loading doses is shown in Table I. When mice were injected with high specific activity $^{123}$I-ICG, the excretion of dye in the gut of mice was noted as early as 30 seconds after injection and in 15 minutes the activity in the gut exceeded that in the liver figure 2. With higher loading doses the extraction is slow, storage time is prolonged, and there is slow excretion from the liver. With a small loading dose the extraction from blood and excretion from the liver is rapid with a short retention time in the liver. When mice were injected with $^{123}$I-ICG in a dose of 0.16 mg/kg the hepatic half time was less than 15 minutes.

As the specific activity was improved by lowering the loading dose of indocyanine green, uptake in the spleen and lungs dropped. With a loading dose of 8 mg/kg of body weight, lung showed very high uptake and was the second highest organ after the liver.

The effects of different loading doses in mice is summarized in figures 3 and 4.

The loading dose effect was further studied in 2 New Zealand rabbits. One rabbit was injected intravenously with $^{123}I$ labeled indocyanine green with 15 mg/kg of body weight, and the other with 0.5 mg/kg of body weight. The curves extracted from the data collected are shown figure 5.

Figure 5a shows that with low specific activity, the extraction of the labeled dye is slow and the maximum activity in the liver is reached in approximately 30 minutes and then plateaus out. With a lower dose, i.e. 0.5 mg/kg of body weight, the activity peaked in approximately 10 minutes and excretion followed as seen in figure 5b.

When radiolabeled ICG was injected intravenously in normal dogs the mixing time in the blood was rapid and the $T_{\frac{1}{2}}$ of blood disappearance of the $^{123}I$-ICG was 7.6 minutes (range 7 to 10.5 minutes). The early disappearance was mono-exponential. The average plasma disappearance was 10.3 percent per minute (range 7.29 to 12.6% per minute). In one dog with complete bile duct obstruction, the blood disappearance was bi- rather than mono-exponential with a very slow second component (figure 6). Tissue distribution of $^{123}I$-ICG in dogs is given in table II. In normal dogs, the activity in the bile was noted as early as 3 minutes. Sequential scintiphotos in normal dog were obtained with the gamma camera and are shown in figure 7. This shows that immediately after injection the gall bladder fossa is seen as a filling defect and as the dye is ex-

creted by the polygonal cells in the biliary system, activity can be seen accumulating in the hepatic ducts and gradually entering the gall bladder. Figure (7-d) clearly shows both hepatic ducts, common bile duct and the gall bladder. A $^{99m}$Tc sulfur colloid liver scan Fig. 7f was taken at the end of the 24 hour $^{123}$I-ICG study.

In the serial scintiphotos obtained in a dog with common bile duct obstruction, the gall bladder is visualized as a cold area and the activity accumulates in the bile duct at the site of obstruction and is seen as a hot area (Fig. 8 a-c). These scintiphotos clearly indicate that the excretion of $^{123}$I-ICG is delayed as compared with the scintiphotos (Fig. 8 d-f), taken in a normal dog at a comparable time intervals.

COMMENTS

Indocyanine Green is exclusively extracted by the hepatic polygonal cells and its complete recovery from the bile makes this dye suitable for the study of liver function [10].

In spite of its exclusive use in various dose concentrations and in different clinical situations, serious side effects are rare. Michie et al. [24] has reported adverse reactions in 3 uraemic patients on chronic hemodialysis. Although the mechanism of adverse reaction was not clear in these patients, commercially available indocyanine green contains a small amount of sodium iodide and patients with allergy to iodides may manifest an adverse reaction to the dye [25]. Before labeling indocyanine green, it was purified of sodium iodide and then labeled, as described in the text, to make it free of side effects.

The present study indicates that carrier-free $^{123}$I-ICG behaves in a manner similar to unlabeled indocyanine green.

Hunton et al. [19] reported that a dosage of 9.0 mg/kg of body weight changed the plasma disappearance rate from 9.3% per minute to 3.8% per minute. The $T_{\frac{1}{2}}$ blood disappearance of 9.8 min. in dogs reported by Rapaport et al. [26] and 5.2 min and 10.5 min in two dogs reported by Wheeler et al. [27] is in agreement with our data. Similarly the plasma disappearance rate as reported here confirms that $^{123}I$ labeled ICG behaves like unlabeled ICG.

Our data shows that maximum concentration of $^{123}I$-ICG in mice and rabbits liver reaches a peak earlier and the excretion with smaller loading doses is faster.

The scintiphotos of hepato biliary system in normal dogs and a dog with complete bile duct obstruction indicate that one can differentiate the normal pattern from complete biliary obstruction.

## REFERENCES


[1] ABEL, J.J., ROWNTREE, L.G., On the Pharmacological action of some phthaleins and their derivatives with especial reference to their behavior as purgatives, I, J. Pharmacol. Exp. Ther. 1 (1909) 233.

[2] ROSENTHAL, SM., WHITE, E.C., Clinical applications of the bromsulphalein test for hepatic function, J.A.M.A. 84 (1925) 1112.

[3] SIEVERS, J.J., MOREY, G.R., SAMTER, M., Fixed anaphylatic sensitization, bromsulphalien studies, J. Allergy 20 (1949) 167.

[4] VENGER, N., Fatal reaction to sulfbromophthalein sodium in a patient with bronchial asthma, J.A.M.A. 175 (1961) 506.

[5] MALLIN, S.M., GAMBESCIA, J.M., A fatal reaction to sulfbromophthalein, J.A.M.A. 174 14 (1960) 166.

[6] DELPRAT, G.D., EPSTEIN, N.N., KERR, W.J., New liver function test: elimination of rose bengal when injected into circulation of human subjects, Arch. Int. Med. 34 (1924) 533.

[7] MENDELOFF, A.I., Fluorescence of intravenously administered rose bengal appears only in hepatic polygonal cells, Proc. Soc. Exp. Biol. & Med. 70 (1949) 556.

[8] SAPIRSTEIN, L.A., SIMPSON, A.M., Plasma clearance of rose bengal (tetraoidotetrabromfluorescein, Amer. J. Physiol. 182 (1955) 337.

[9] TAPLIN, G.V., MEREDITH, O.M., JR., KADE, H., The radioactive (I-131 tagged) rose bengal uptake - excretion test for liver function using external gamma ray scintillation counting techniques, J. Lab. and Clin. Med. 45 (1955) 665.

[10] FOX, I.J., BROOKER, L.G., HESELTINE, D.W., WOOD, E.H., A new dye for continuous recording of dilution curves in whole blood independent of variations in blood oxgyen saturation, Circulation 14 (1956) 937.

[11] HUNTON, D.B., BOLLMAN, J.L., HOFFMAN, H.N., Studies of hepatic function with indocyanine green, Gastroenterology 39 (1960) 713.

[12] GOSS, J.E., ALFREY, A.C., VOGEL, J.H.K., HOLMES, J.H., Hemodynamic changes during hemodialysis, Trans. Amer. Soc. Artif. Int. Organs 18 (1967) 68.

[13] MURRAY, J.F., DAVIDSON, F.F., GLAZIER, J.B., Modified technique for measuring pulmonary shunts using xenon and indocyanine green, J. Applied Physiol. 32 5 (1972) 695.

[14] RITZ, R., CAVANILLES, J., MICHAELS, S., SHUBIN, H., WEIL, M.H., Disappearance of indocyanine green during circulatory shock, Sur. Gynec. Obstet. 136 (1973) 5.

[15] FLOWER, R.W., Infrared absorption angiography of the choroid and some other observations on the effects of high intraocular pressure, Amer. J. Ophthalomology 74 (1972) 600.

[16] BRADLEY, E.C., BARR, J.W., Determination of blood volume using indocyanine green (cardio-green) dye, Life Sciences 7 (1968) 1001.

[17] COOKE, A.R., HARRISON, D.D., SKYRING, A.P., Use of indocyanine green as a test of liver function, Amer. J. Dig. Dis. 8 (1963) 244.

[18] KETTERER, S.G., WIEGAND, B.D., RAPAPORT, E., Hepatic uptake and biliary excretion of indocyanine green and its use in estimation of hepatic blood flow in dogs, Amer. J. Physiol. 199 (1960) 481.

[19] HUNTON, D.B., BOLLMAN, J.L., HOFFMAN, H.N., Hepatic removal of indocyanine green, Staff meeting of the Mayo Clinic 35 (1960) 752.

[20] PROBST, P., BAUMGARTNER, G., CAUCIG, H., FROHLICH, H., GRABNER, G., Studies on clearance and placental transfer of indocyanine green during labor, Clinica Chimica Acta 29 (1970) 157.

[21] LAMBRECHT, R.M., WOLF, A.P., Cyclotron and short-lived halogen isotopes for radiopharmaceuticals and labeled compounds. I.A.E.A. Vienna, 1973, Vol. I, pp. 275-290.

[22] LAMBRECHT, R.M., WOLF, A.P., The $^{122}Te\ (\alpha, 3n)\ ^{123}Xe \xrightarrow[2.1\ hr]{\beta^+, EC} {}^{123}I$ generator, Radiat. Res. 52 (1972) 32.

[23] LAMBRECHT, R.M., WOLF, A.P., Recent developments and new approaches at the cyclotron for the preparation of short-lived nuclides for radiopharmaceuticals. International Symposium on Radiopharmaceuticals. Feb. 11-15, 1974. Atlanta, Georgia. (to be published).

[24] MICHIE, D.D., WOMBOLT, D.G., CARRELTA, R.F., ZENCKA, A.E., EGAN, J.D., Adverse reactions associated with the administration of tricarbocyanine dye (Cardio-green) to uraemic patients, J. Allergy Clin. Immunology 48 4 (1971) 235.

[25] WOOENWEBER, H.L., KOMBER, J.L., Indocyanine green dye test for hepatic function determination, Office Pathology 5, (1968) 1.

[26] RAPAPORT, E., KETTERER, S.G., WIEGAND, B.D., Hepatic clearance of indocyanine green, Clin. Res. 7 (1959) 289.

[27] WHEELER, H.D., CRANSTON, W.I., MELTZER, J.I., Hepatic uptake and biliary excretion of indocyanine green in dogs, Proc. Soc. Exp. Biol. Med. 99 (1958) 11.

## LEGEND

Fig. 1 Chemical structure. Indocyanine Green.

Fig. 2 $^{123}$I-ICG distribution in mice, loading dose 0.16 mg/kg.

Fig. 3 Liver clearance of radioiodine labeled ICG in mice with different loading doses.

Fig. 4 Liver clearance of $^{123}$I ICG in mice as a function of loading dose and the time after administration.

Fig. 5 Dynamic liver clearance of $^{123}$I ICG in rabbits.

Fig. 6 $^{123}$I ICG Blood disappearance curve in dogs.

Fig. 7 Serial scintiphotos of hepatobiliary system in normal dog.
(A-D) shows excretion of $^{123}$I ICG from liver into biliary tree.
(E) 24 hour scintiphoto with residual activity in the gall bladder.
(F) $^{99m}$Tc Sulfur Colloid Scintiphoto taken after (E).

Fig. 8 Serial scintiphotos of hepatobiliary system comparison of normal with complete bile duct obstruction. (A, B and C) complete bile duct obstruction, (D,E and F) are normal.

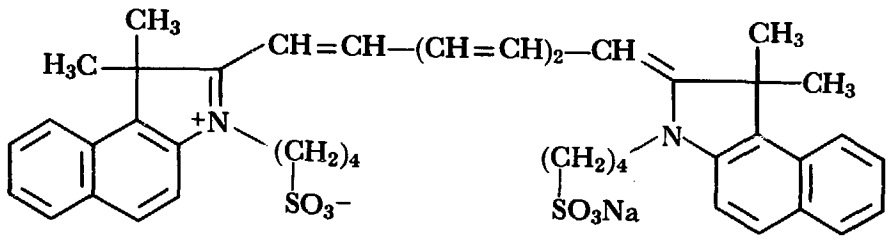


EXCITATION LABELED via THEN REPURIFIED $^{123}Xe \xrightarrow[2.1\ hr]{EC,\ \beta+} {}^{123}I$

$^{123}$I-ICG ($^{123}$I-Indocyanine Green)

**FIGURE 1**

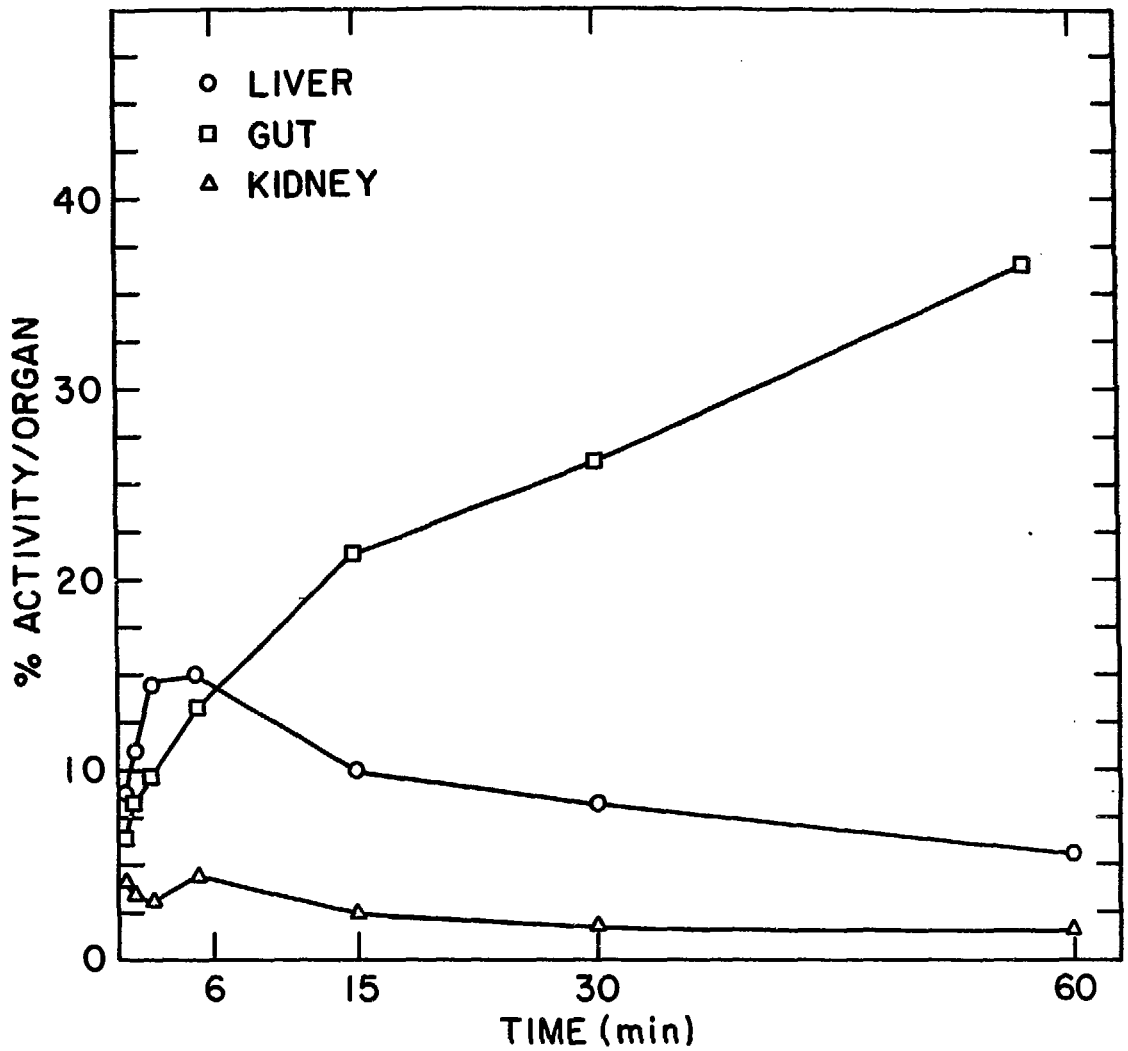


$^{123}I$ ICG DISTRIBUTION IN MICE, LOADING DOSE 0.16 mg/kg

FIGURE 2

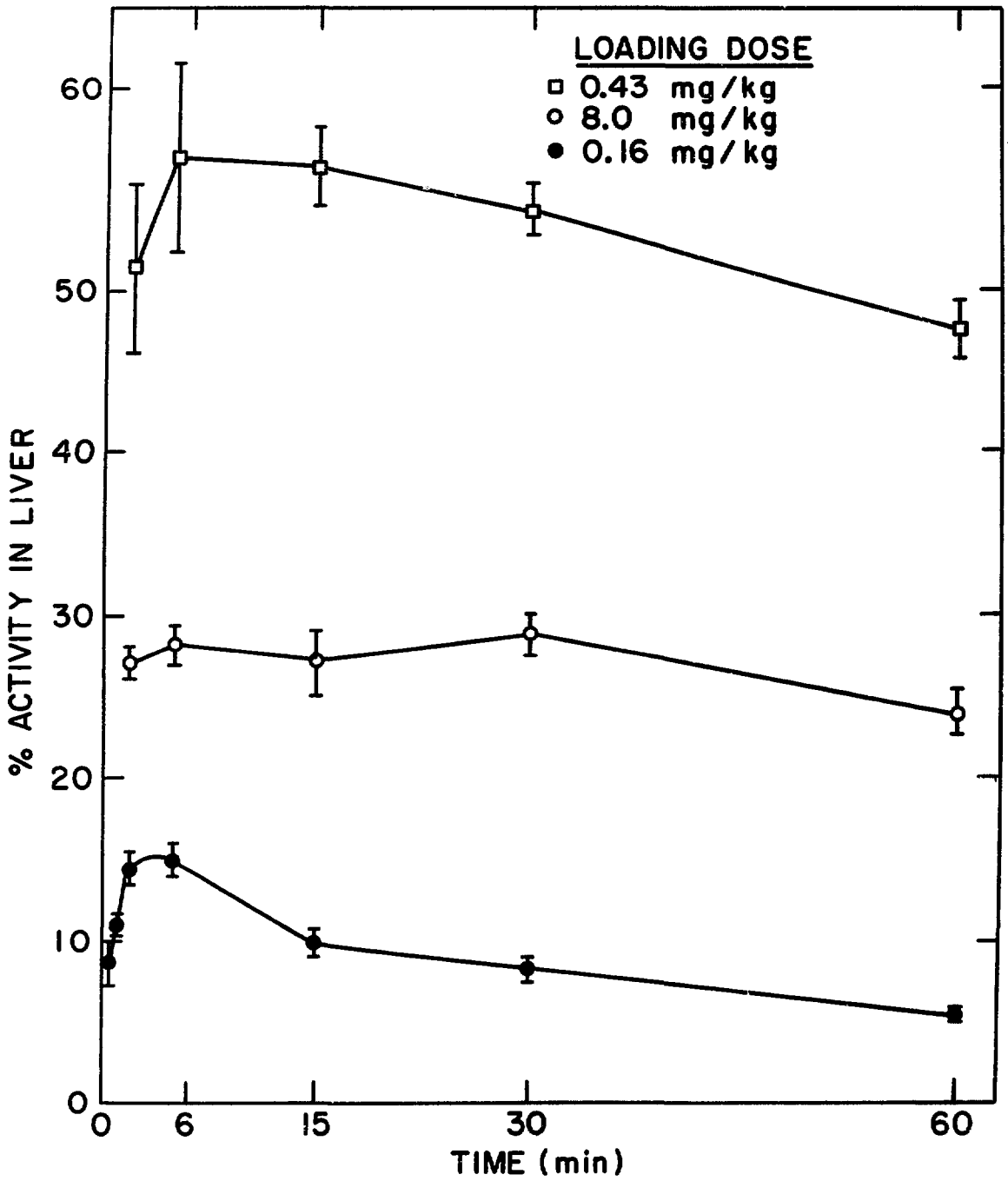


LIVER CLEARANCE OF RADIOIODINE LABELED ICG IN MICE

FIGURE 3

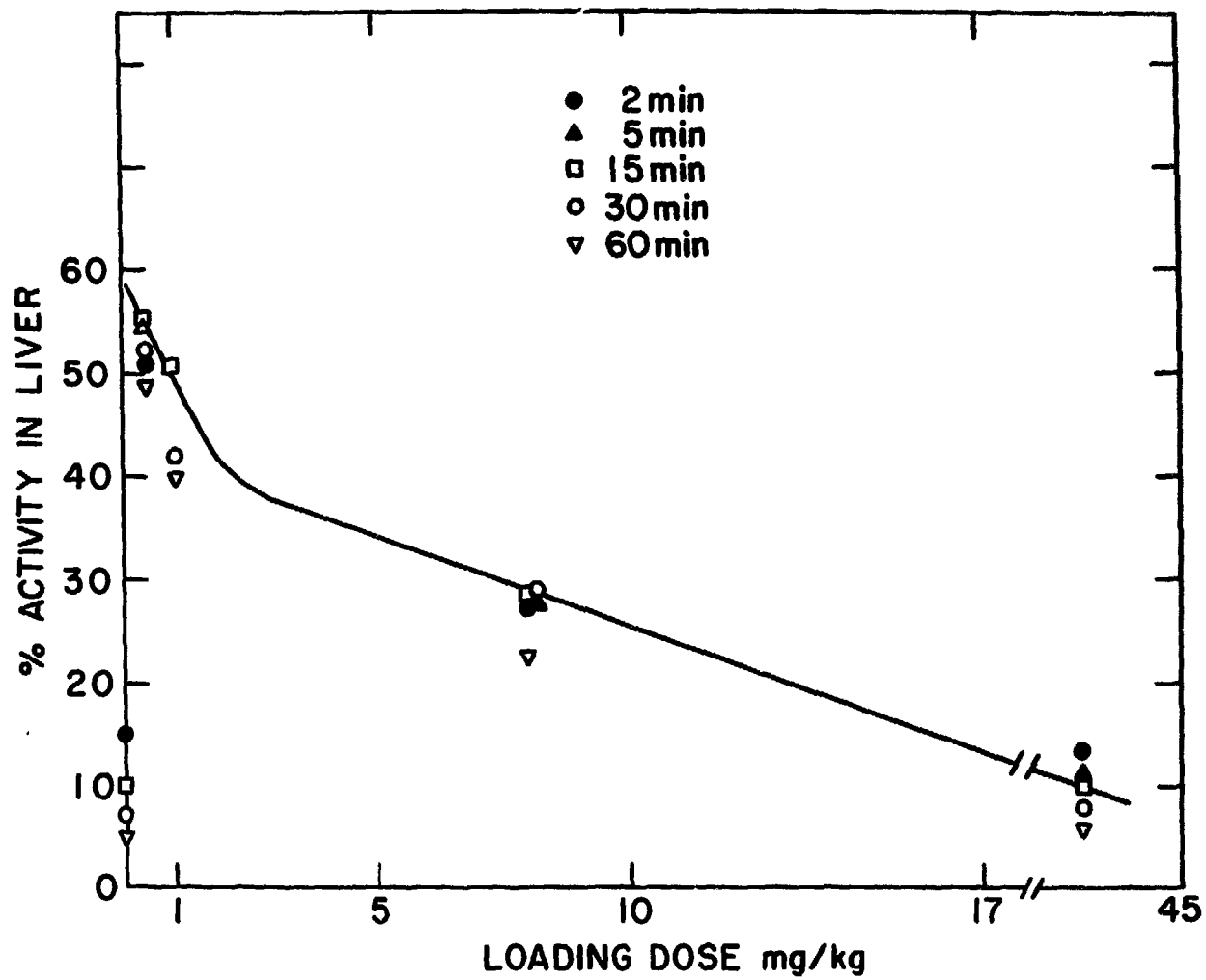


LIVER CLEARANCE OF $^{123}$I ICG IN MICE AS A FUNCTION OF LOADING DOSE AND THE TIME AFTER ADMINISTRATION

FIGURE 4

LOADING DOSE A: 15.0 mg/kg



0 30 45

LOADING DOSE B: 0.5 mg/kg



0 30 60

TIME (min)

DYNAMIC LIVER CLEARANCE OF $^{123}I$ ICG IN RABBITS

FIGURE 5

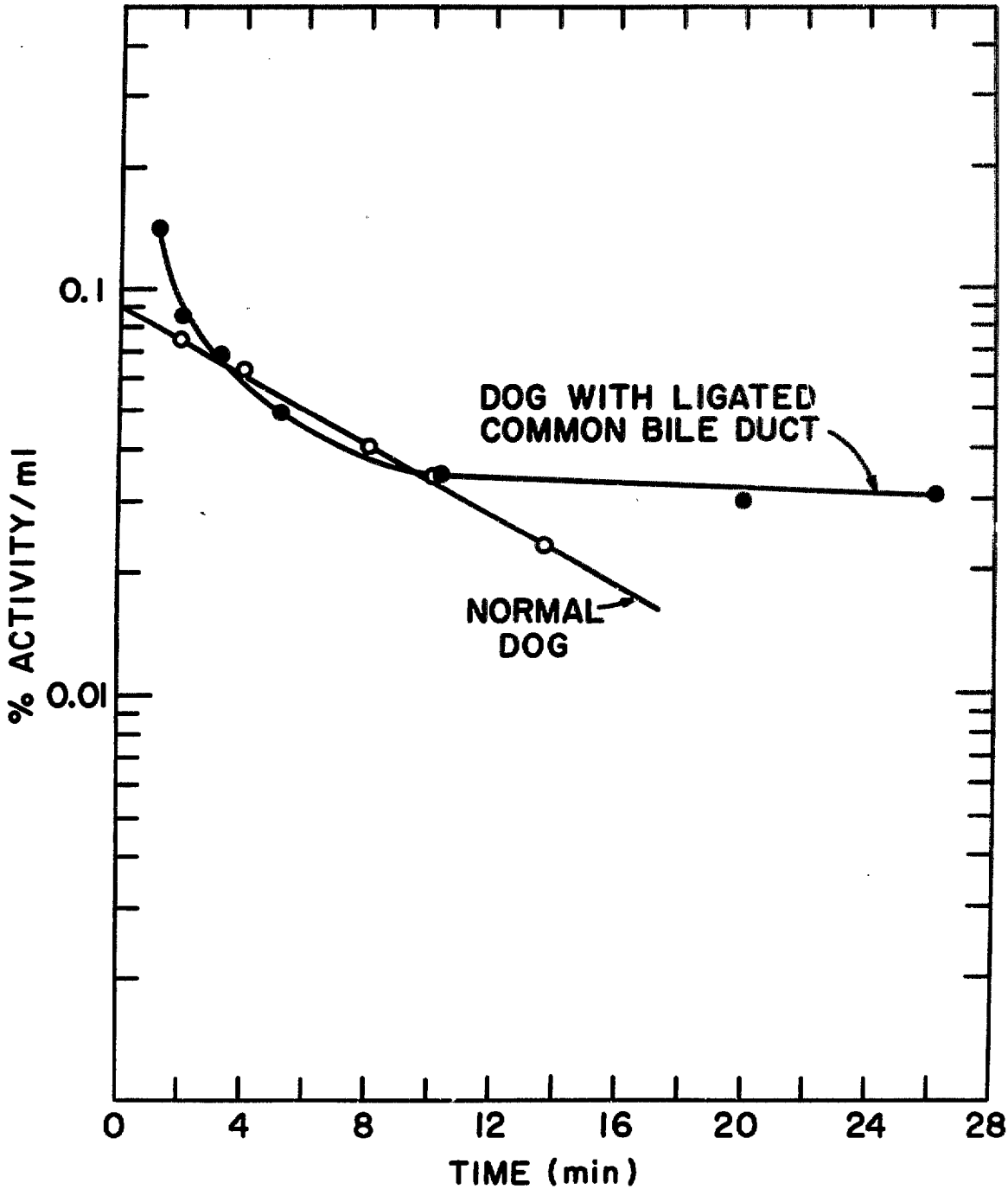


$^{123}I$ ICG BLOOD DISAPPEARANCE CURVE IN DOGS

FIGURE 6

(A) 15 minutes (B) 60 minutes (C) 80 minutes

(D) 2 hours (E) 24 hours (F)

SERIAL SCINTIPHOTOS OF HEPATOBILIARY SYSTEM IN NORMAL DOG. (A–D) SHOWS EXCRETION OF $^{123}I$ ICG FROM LIVER INTO BILIARY TREE. (E) 24 hour SCINTIPHOTO WITH RESIDUAL ACTIVITY IN THE GALL BLADDER. (F) $^{99m}Tc$ SULFUR COLLOID SCINTIPHOTO TAKEN AFTER (E).

FIGURE 7

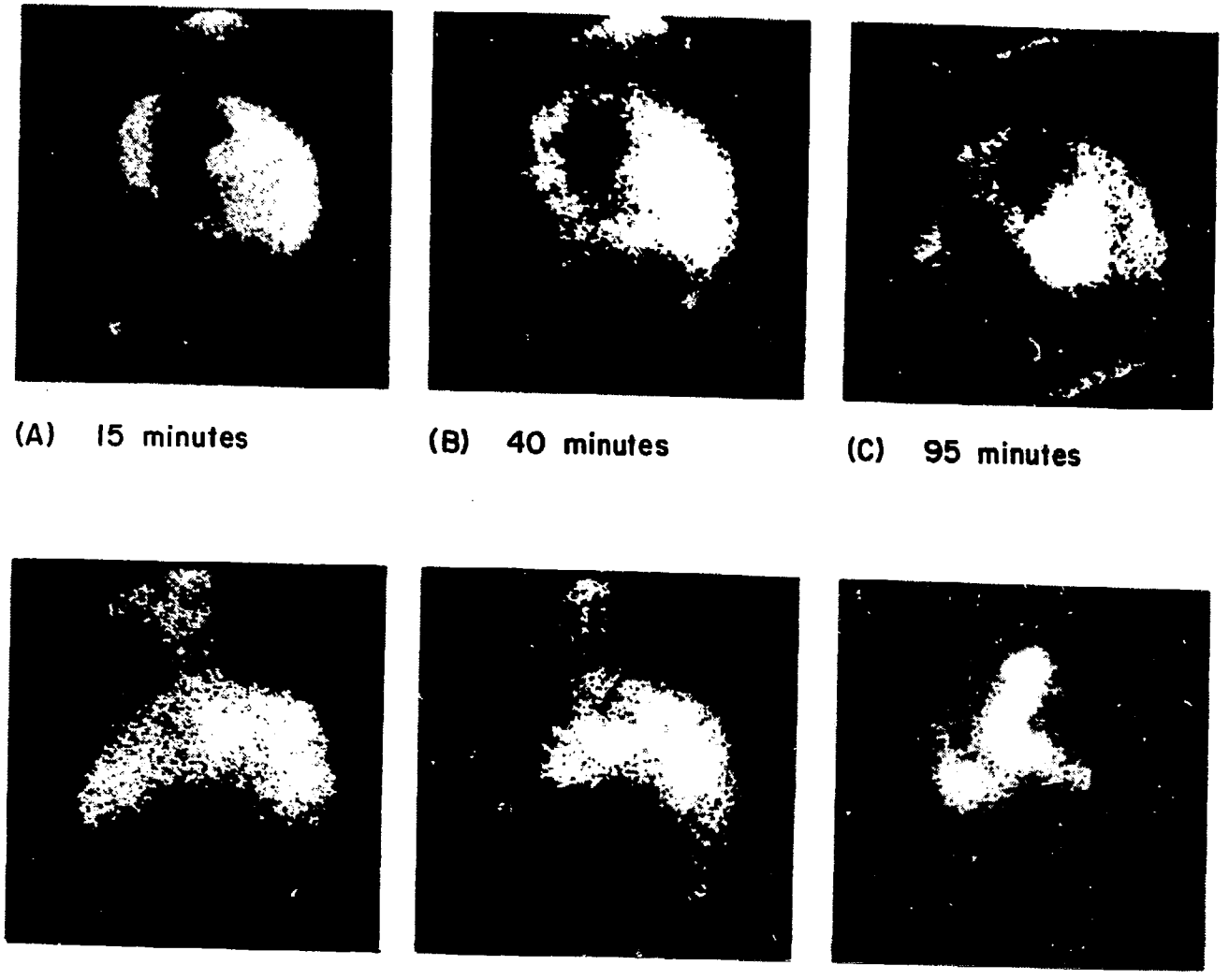


FIGURE 8

SERIAL SCINTIPHOTOS OF HEPATOBILIARY SYSTEM. COMPARISON OF NORMAL WITH COMPLETE BILE DUCT OBSTRUCTION. (A,B,and C) COMPLETE BILE DUCT OBSTRUCTION, (D,E,and F) ARE NORMAL.

**TABLE I ORGAN DISTRIBUTION OF $^{125}$I – INDOCYANINE GREEN IN MICE WITH DIFFERENT LOADING DOSES**

| Time of sacrifice | 0.5 min | 1 min | 2 min | | | | 5 min | | | | 15 min | | | | 30 min | | | | 60 min | | | |
|---|---|---|---|---|---|---|---|---|---|---|---|---|---|---|---|---|---|---|---|---|---|---|
| Loading dose mg/kg body weight | 0.16 | 0.16 | 0.16 | 0.43 | 1.0 | 8.0 | 0.16 | 0.43 | 1.0 | 8.0 | 0.16 | 0.43 | 1.0 | 8.0 | 0.16 | 0.43 | 1.0 | 8.0 | 0.16 | 0.43 | 1.0 | 8.0 |
| | % activity/organ | | % Activity/organ | | | | % Activity/organ | | | | % Activity/organ | | | | % Activity/organ | | | | % Activity/organ | | | |
| LIVER | 8.53 ±0.15 | 10.78 ±0.44 | 14.29 ±1.10 | 51.40 ±5.35 | 23.58 ±15.1 | 27.03 ±1.07 | 14.87 ±0.76 | 55.56 ±6.55 | | 28.333 ±1.51 | 9.87 ±0.76 | 55.17 ±2.09 | 50.50 ±5.51 | 27.30 ±2.24 | 8.27 ±0.83 | 52.17 ±1.34 | 42.25 ±1.9 | 28.90 ±1.60 | 5.79 ±0.29 | 47.51 ±4.68 | 40.52 ±1.05 | 23.96 ±1.32 |
| SPLEEN | 0.15 ±0.02 | 0.28 ±0.14 | 0.35 ±0.05 | 2.19 ±0.05 | 1.74 ±0.28 | 4.23 ±3.01 | 0.56 ±0.06 | 1.92 ±0.47 | 2.31 ±1.00 | 5.68 ±1.74 | 0.35 ±0.02 | 2.47 ±0.36 | 1.88 ±0.62 | 5.26 ±1.66 | 0.56 ±0.05 | 2.50 ±0.72 | 1.72 ±0.16 | 1.54 ±0.22 | 0.50 ±0.05 | 3.98 ±2.03 | 2.00 ±1.07 | 1.41 ±0.24 |
| KIDNEY | 4.14 ±0.65 | 3.57 ±0.68 | 3.08 ±1.80 | 2.53 ±0.09 | 2.38 ±1.23 | 2.61 ±1.99 | 4.34 ±0.33 | 2.41 ±0.33 | 1.73 ±0.19 | 3.79 ±0.15 | 2.3 ±0.32 | 1.85 ±0.16 | 1.68 ±0.24 | 2.36 ±0.15 | 1.78 ±0.24 | 2.83 ±1.55 | 1.69 ±0.20 | 1.53 ±0.77 | 1.50 ±0.15 | 1.87 ±0.12 | 1.70 ±0.40 | 1.58 ±0.15 |
| GUT | 6.40 ±2.77 | 8.40 ±0.32 | 9.13 ±0.26 | 4.92 ±0.33 | 5.84 ±0.86 | 1.04 ±.74 | 13.16 ±6.24 | 5.84 ±0.58 | 8.62 ±1.02 | 1.74 ±0.30 | 21.24 ±3.59 | 8.31 ±0.67 | 11.20 ±1.38 | 2.50 ±0.43 | 26.31 ±3.18 | 9.02 ±1.00 | 19.95 ±1.55 | 10.82 ±0.83 | 36.61 ±4.40 | 11.69 ±0.73 | 19.68 ±5.42 | 13.08 ±1.02 |
| GONADS | 0.15 ±0.03 | 0.18 ±0.12 | 0.18 ±0.06 | 0.12 ±0.02 | 0.09 ±0.01 | 0.09 ±0.07 | 0.20 ±0.02 | 0.13 ±0.05 | 0.08 ±0.002 | 0.14 ±0.01 | 0.16 ±0.02 | 0.13 ±0.02 | 0.09 ±.008 | 0.15 ±0.02 | 0.085 ±0.01 | 0.10 ±0.01 | 0.10 ±0.02 | 0.14 ±0.01 | 0.08 ±0.09 | 0.13 ±0.01 | 0.13 ±0.03 | 0.14 ±0.02 |
| LUNGS | 4.95 ±0.31 | 2.69 ±0.37 | 2.17 ±0.12 | | 1.34 ±0.19 | 25.32 ±4.36 | 1.58 ±0.60 | | 0.97 ±0.19 | 20.25 ±2.06 | 0.93 ±0.13 | | 1.06 ±0.10 | 16.34 ±4.19 | 0.75 ±0.10 | | 0.93 ±0.11 | 8.20 ±3.08 | 0.70 ±0.11 | | 0.61 ±0.14 | 6.71 ±1.66 |
| PANCREAS | 0.45 ±0.01 | 0.49 ±0.09 | 0.41 ±0.31 | | 0.35 ±0.07 | 0.34 ±0.24 | 0.48 ±0.33 | | 0.47 ±0.20 | 0.56 ±0.01 | 0.33 ±0.02 | | 0.24 ±0.01 | 0.45 ±0.08 | 0.71 ±0.07 | | 0.41 ±0.21 | 0.44 ±0.08 | 1.39 ±0.26 | | 0.27 ±0.08 | 0.34 ±0.04 |
| BLOOD. * | 12.80 ±1.20 | 9.61 ±0.57 | 7.87 ±0.65 | 10.52 ±0.50 | 8.31 ±1.67 | 9.30 ±6.50 | 5.54 ±0.15 | 5.90 ±0.72 | 4.43 ±0.52 | 7.10 ±0.85 | 4.12 ±0.52 | 4.48 ±0.16 | 2.96 ±0.12 | 4.84 ±0.63 | 4.36 ±0.22 | 4.23 ±0.35 | 3.58 ±0.16 | 4.25 ±0.40 | 3.87 ±0.37 | 3.90 ±0.15 | 2.57 ±0.49 | 3.07 ±0.08 |

(* % dose/g)

TABLE II DISTRIBUTION OF $^{123}I$ INDOCYANINE GREEN IN DOGS. (% dose/ g)

| Dog # | Time of sacrifice | Liver | Spleen | Kidney | Pancreas | Lung | Gonads | Thyroid | Bile | Urine |
|---|---|---|---|---|---|---|---|---|---|---|
| 1 | one hour | 0.043 | 0.038 | 0.003 | 0.002 | 0.007 | 0.002 | 0.017 | 0.005 | 0.001 |
| 2 | 3 hrs. | 0.017 | 0.13 | 0.003 | 0.002 | 0.003 | 0.002 | 0.05 | 0.077 | 0.008 |
| 3 | 20 hrs. | 0.006 | 0.003 | 0.003 | 0.001 | 0.003 | 0.003 | 2.46 | 0.040 | 0.04 |
| 4 | 20 hrs. * | 0.23 | 0.33 | 0.08 | 0.05 | 0.056 | 0.057 | 1.80 | 0.093 ** | 1.1 |

( * ) Dog with common bile duct obstruction.

(**) Bile collected from common bile duct.