How Does Nuclear Medicine Work?

Radiopharmaceutical Energy Reveals World of Human Biology

Nuclear medicine images are produced by the energy emitted from radiopharmaceuticals inside a patient's body with imaging systems ("scanners") that detect and process the energy signals. The special ability of radiopharmaceuticals to visualize human biology, both healthy and diseased, arises from their distribution through the body as "radiotracers." Nearly all radiopharmaceuticals (i.e., medically useful radiotracers) and imaging systems described here were discovered, designed, or developed by scientists supported by the **BER Medical Sciences** program during the past 50 years.

Biological Imaging

Of a **Physiologic Process**, Not Anatomy

Disease is a biological process, and nuclear medicine provides images of these biological processes. Most radiotracers interact with a biological process—such as bone mineral turnover, potassium transport in heart muscle, or glucose (sugar) metabolism in various organs or tumors—and emit low levels of radiation. Highly sensitive detector systems collect these energy signals, and computer programs reconstruct them into diagnostic images. Because it provides images of a biological process (physiology), nuclear medicine differs from other imaging techniques—such as x-rays, computed tomography (CT), magnetic resonance imaging (MRI), and ultrasound—which primarily visualize structure and shape (anatomy).

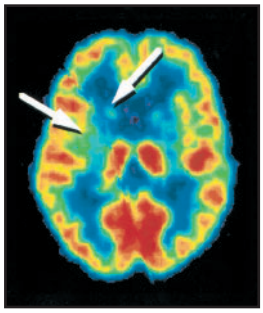

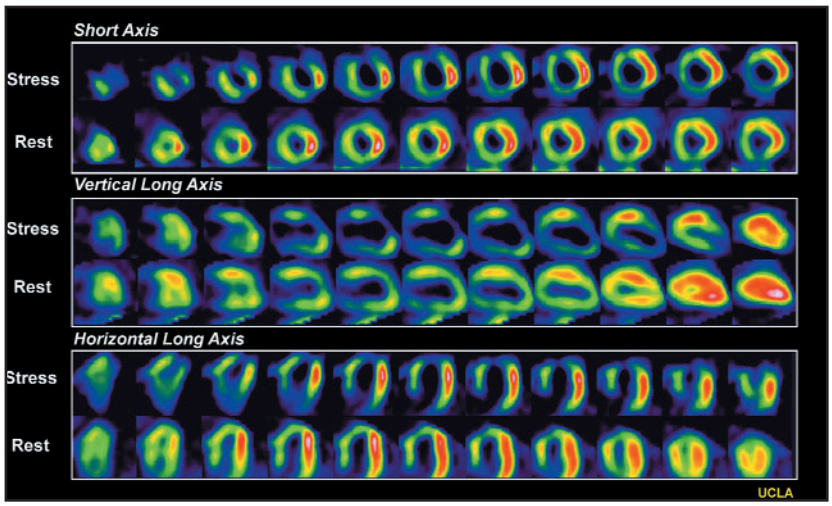

A single image from a brain scan (top left), a bone scan (bottom left), and a series of images from a heart scan (right) during exercise ("stress") and "rest." The brain scan shows reduced glucose metabolism in a pattern characteristic of **Huntington's disease**, evident years before the patient exhibited abnormal movements or other symptoms of this hereditary disease. The bone scan is from a patient with **prostate cancer** that has spread to the spine and other bones. The radiopharmaceutical, similar to the mineral in bone, accumulates at bone tumors (dark spots) because the diseased bone has faster mineral turnover. The heart scan, from a patient with **coronary artery disease**, shows where the heart muscle lacks adequate blood flow. The radiopharmaceutical, thallium-201, mimics potassium and accumulates more in regions of normal blood flow.